

Successful percutaneous removal of broken umbilical vein catheter in a very low-birth-weight preterm infant

Çok düşük doğum ağırlıklı yenidoğanda kopan umbilikal ven kateterinin perkütan çıkarılması

Atalay Demirel, M.D., Gülşah Güven, M.D., Füsün Okan, M.D., Arda Saygılı, M.D.

Department of Child Health and Diseases, Acıbadem University Faculty of Medicine, İstanbul, Turkey

Summary—A 28-week-old preterm infant with a birth weight of 1250 g had a broken segment of umbilical vein catheter (UVC) lodged in the right atrium. It was observed that a 7-cm fragment of catheter had migrated to the right atrium through the inferior vena cava. The catheter was successfully retrieved by fluoroscopically guided percutaneous cardiac catheterization, using a cobra catheter and snare wire, without complication. Fracture and embolization of UVC is a rare but serious complication. Presently described was a case of fractured and embolized UVC in a very low-birth-weight preterm infant, and its successful retrieval via percutaneous endovascular approach.

Özet—Gebeliğin 28. haftasında 1250 gram doğmuş olan bebeğin umbilikal ven kateteri (UVK) koparak sağ atriya ilerlemiştir. Kateterin 7 cm'lik parçasının inferiyor vena kavadan sağ atriya ilerlediği saptandı. Floroskopi altında kobra kateter ve snare tel kullanarak perkütan kardiyak kateterizasyon ile kateter komplikasyonsuz çıkarıldı. Umbilikal ven kateterin kopması ve embolizasyonu nadir fakat ciddi bir komplikasyondur. Bu yazıda, çok düşük doğum ağırlıklı yenidoğanda kopmuş ve embolize olmuş kateterin perkütan endovasküler yolla başarılı şekilde çıkarılması sunuldu.

Umbilical catheters are often used in preterm infants as central venous access for fluid and drug administration, invasive monitorization, and blood sampling, but can lead to complications, such as infection, arrhythmia, embolization, and catheter rupture.^[1-6] Catheter rupture is an uncommon but very challenging complication for clinicians. Catheters can be retrieved by surgical or percutaneous techniques.

Presently reported is our experience with a ruptured and embolized umbilical vein catheter (UVC) in a very low-birth-weight (VLBW) preterm infant, and its retrieval via percutaneous cardiac catheterization.

CASE REPORT

A 28-week-old preterm infant with a birth weight of 1250 g was born by cesarean section to a mother with clinical chorioamnionitis. He was intubated, mechanically ventilated, and given surfactant for respiratory

distress syndrome, before being weaned. Antibiotic treatment was administered for infection. A UVC was placed for parenteral nutritional support on the first day of life, and positioning was checked by x-ray. After hemodynamic and respiratory stabilization, the UVC was removed on the eighth day of life. Two days after catheter removal, abdominal distention and feeding intolerance were observed. Plain abdominal radiography showed that the catheter had fractured and migrated to the right atrium through the inferior vena cava (Figure 1a).

It was decided that the lodged fragment would be removed by percutaneous catheterization technique. With the patient under general anesthesia, a 4-F sheath was placed in the right femoral vein. However, it was difficult to advance the 4-F cobra catheter

Abbreviations:

UVC Umbilical vein catheter
VLBW Very low-birth-weight

Received: February 19, 2016 Accepted: April 01, 2016

Correspondence: Dr. Atalay Demirel. Acıbadem Kadıköy Hospital, Tekin Sit. No: 8, Acıbadem, İstanbul, Turkey.

Tel: +90 216 - 544 44 44 e-mail: drad813@yahoo.com w

© 2016 Turkish Society of Cardiology



to the inferior vena cava. Angiography of the femoral vein showed thrombotic occlusion (Figure 1b). Intravenous heparin (100 IU/kg) was administered. The thrombotic segment of the extracardiac tunnel was crossed by 0.018-in floppy guidewire. The cobra catheter was advanced to the right atrium, and floppy guidewire was exchanged with a 4-F standard snare catheter. The fractured fragment of UVC was retrieved with fluoroscopically guided snare catheter (Figures 1c, d). Total procedural time was 15 minutes, with 5 minutes of fluoroscopy. Control fluoroscopy demonstrated total removal of the broken UVC. Blood loss during the procedure was minimal. Heparin therapy was continued, and there was no clinical sign of thrombosis. Informed consent was obtained from the patient's parents.

DISCUSSION

Catheterization is a very common, life-saving procedure in neonatal intensive care units. Complications are related to positioning and long duration of catheterization.^[1-6] While a majority of VLBW preterm infants are catheterized, lodged fragments of catheter are relatively very rarely reported.

Although umbilical catheter rupture is a very rare complication, many methods of removal have been described, including surgical techniques, percutaneous retrieval via snaring, biopsy forceps, or small balloon techniques.^[7]

The percutaneous technique is less traumatic than open surgery for fragile preterm patients, but more

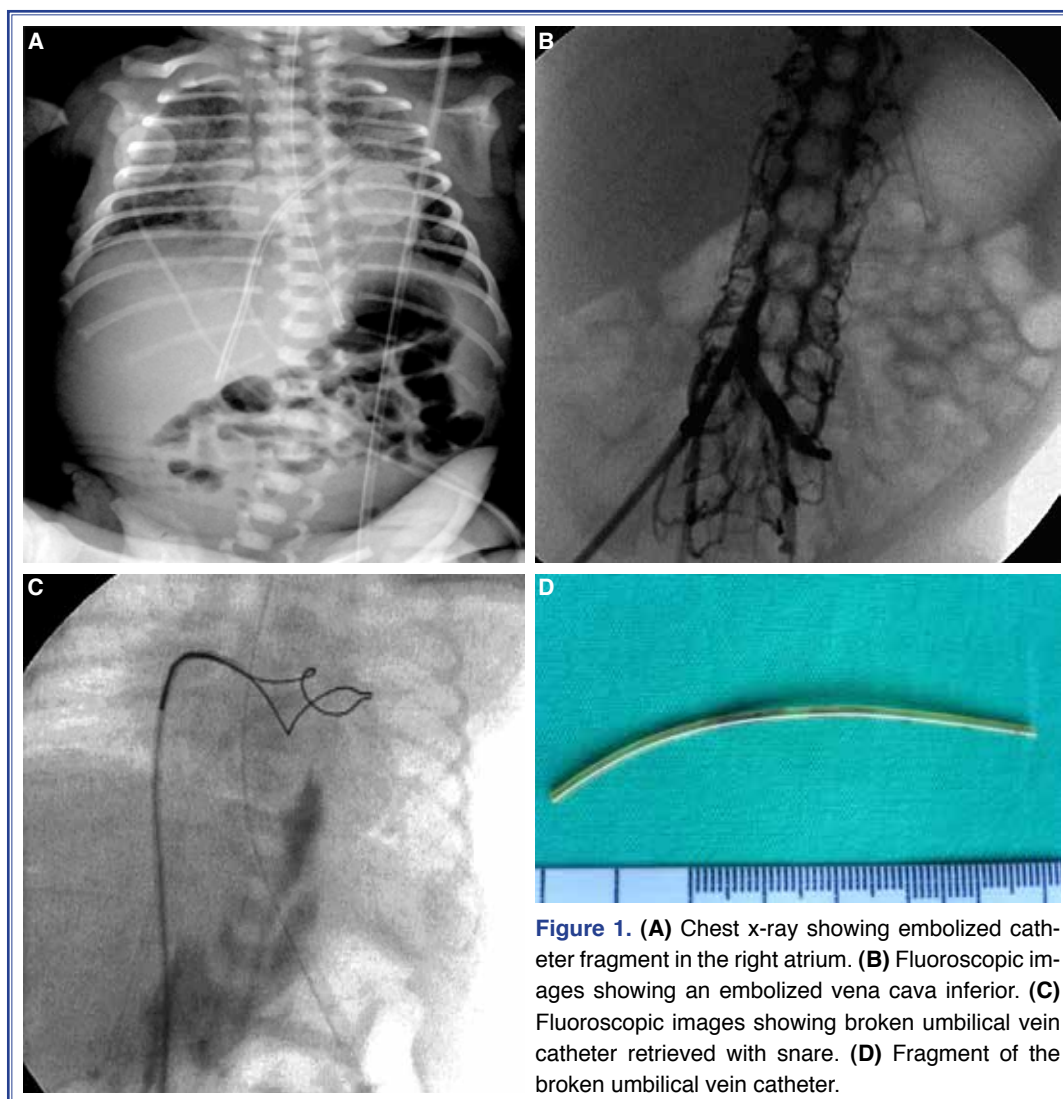


Figure 1. (A) Chest x-ray showing embolized catheter fragment in the right atrium. (B) Fluoroscopic images showing an embolized vena cava inferior. (C) Fluoroscopic images showing broken umbilical vein catheter retrieved with snare. (D) Fragment of the broken umbilical vein catheter.

difficult for interventionists, with the primary difficulty being vascular access. As in the present case, clinicians typically attempt to introduce a large sheath to retrieve the lodged catheter through thrombosed vessels. Heparin was administered during the procedure to recanalize the tunnel, and guidewire and cobra catheter were used prior to the introduction of the snare catheter. The procedure was completed relatively quickly, without complication, and follow-up was uneventful.

Complications related to catheters are most common when the catheter is in place, and removal is far easier than insertion. However, the present case emphasizes the importance of checking the catheter tip during removal and keeping catheter-related complications in mind if deterioration is observed following removal.

In conclusion, umbilical venous catheterization is very common in the care of VLBW preterms. Complications in such common invasive interventions cannot be avoided. Fracture and embolization of a UVC is a rare but serious complication. Presently reported was the successful retrieval of a fractured and embolized UVC in a VLBW infant, via percutaneous endovascular approach, without complication.

Conflict-of-interest issues regarding the authorship or article: None declared.

REFERENCES

1. De Carolis MP, Costa S, Polimeni V, Di Stasi C, Papacci P, Romagnoli C. Successful removal of catheter fragment from right atrium in a premature infant. *Eur J Pediatr* 2007;166:617–8. [Crossref](#)
2. Bautista AB, Ko SH, Sun SC. Retention of percutaneous venous catheter in the newborn: a report of three cases. *Am J Perinatol* 1995;12:53–4. [Crossref](#)
3. Young T, Shaddy RE. Successful percutaneous retrieval of an intracardiac catheter fragment in an 800-g premature infant. *J Perinatol* 2003;23:67–8. [Crossref](#)
4. Massin M, Lombet J, Rigo J. Percutaneous retrieval of broken silastic catheter from the left atrium in a critically ill premature infant. *Cathet Cardiovasc Diagn* 1997;42:409–11. [Crossref](#)
5. Ochikubo CG, O'Brien LA, Kanakriyeh M, Waffarn F. Silicone-rubber catheter fracture and embolization in a very low birth weight infant. *J Perinatol* 1996;16:50–2.
6. Ruiz CE, Nystrom GA, Butt AI, Zhang HP. Percutaneous retrieval of a broken umbilical catheter from left atrium in a premature newborn. *Cathet Cardiovasc Diagn* 1995;36:265–8.
7. Paulus BM, Fischell TA. Retrieval devices and techniques for the extraction of intravascular foreign bodies in the coronary arteries. *J Interv Cardiol* 2010;23:271–6. [Crossref](#)

Keywords: Percutaneous cardiac catheterization; preterm infant; umbilical vein catheter.

Anahtar sözcükler: Perkütan kardiyak kateterizasyon; preterm bebek; umbilical ven kateteri.