

Fever-induced precordial ST-segment elevation in a young man

Genç erkek hastada ateşin yol açtığı prekordiyal ST-segment yüksekliği

Beste Özben, M.D., Oğuz Caymaz, M.D., Okan Erdoğan, M.D.

Department of Cardiology, Medicine Faculty of Marmara University, İstanbul

Brugada syndrome is a rare condition characterized by ST-segment elevation in the right precordial leads. Fever can induce Brugada-like electrocardiographic (ECG) changes. We reported on a 26-year-old male patient with fever and ST-segment elevation in the right precordial leads. Serial cardiac markers were normal and transthoracic echocardiography showed normal wall motion and no evidence for pericardial effusion. Brugada-like ECG changes disappeared after fever resolved. Since the patient had never experienced any arrhythmic symptom, syncope, or spontaneous type 1 ECG, electrophysiological study was not performed and he was not referred for defibrillator implantation. The patient was discharged with strong recommendations to avoid certain medications responsible for Brugada-like ECG changes and to receive urgent treatment for fever. He was asymptomatic during a year follow-up. Emphasis is placed on this particularly rare, but important condition, as it may easily be misdiagnosed and fever may even precipitate ventricular fibrillation.

Key words: Brugada syndrome; electrocardiography; fever/ complications.

Brugada syndrome is a rare condition characterized by ST-segment elevation in right precordial leads. This ST elevation may be dynamic over time. Fever can induce Brugada-like electrocardiographic (ECG) changes and precipitate ventricular fibrillation.^[1] We report a patient with fever which induced Brugada-like ECG changes, aiming to draw attention to this particularly rare, but important condition.

CASE REPORT

A 26-year-old male patient was admitted to the emergency room complaining of fever, sore throat, and chest pain. His medical history was unremarkable and he was not using any medication. On physical examina-

tion, there was pharyngeal inflammation, his body temperature was 38.8 °C, and blood pressure and pulse were 120/80 mmHg and 90/min, respectively. Cardiac auscultation showed normal heart sounds with no murmur or friction rub. A 12-lead ECG showed sinus rhythm (rate 90/min) with incomplete right bundle branch block, ST-segment elevation, and T-wave inversion in V1-2 (Fig. 1a). The patient was observed in the emergency room for electrocardiographic changes. Blood tests showed leukocytosis (12,500/mm³) with 90% polymorphonuclear neutrophils and elevated C-reactive protein (7.8 mg/l). There was neither hypoxia nor hypocapnia in arterial blood gas analysis. The chest X-ray showed no consolidation in the lungs.

Anahtar sözcükler: Brugada sendromu; elektrokardiyografi; ateş/komplikasyon.

Received: March 8, 2009 *Accepted:* June 4, 2009

Correspondence: Dr. Beste Özben, Yıldız Cad., Konak Apt., No: 43/24, 34353 Beşiktaş, İstanbul, Turkey.
Tel: +90 216 - 327 10 10 / 558 e-mail: besteozben@yahoo.com

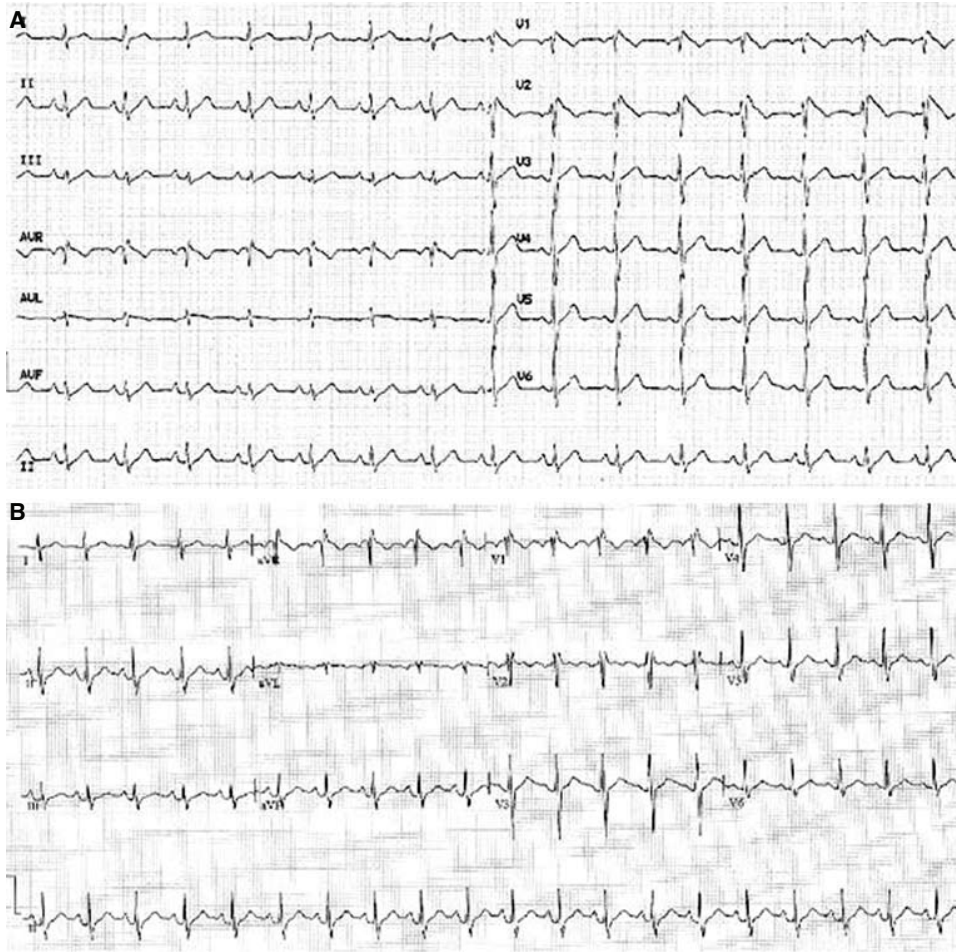


Figure 1. The 12-lead electrocardiogram of the patient (A) during febrile state and (B) after resolution of fever.

Serial cardiac markers were normal (troponin T <0.01 ng/ml, creatine kinase MB isoenzyme 2.1 ng/ml). Transthoracic echocardiography showed normal wall motion with no evidence for pericardial effusion. The patient was discharged after acute coronary syndrome, pericarditis, or pulmonary embolism were ruled out. He was given an antibiotic and antipyretic for upper respiratory tract infection and recommended to present to the cardiology department for ECG findings.

Two days later, the patient applied to our cardiology outpatient clinic. He was afebrile. His complaints were relieved. The ECG showed sinus tachycardia (rate 102/min), incomplete right bundle branch block, and minimal ST-segment elevation in lead V2 (Fig. 1b). We noticed that his ECG during the febrile period was consistent with type I Brugada pattern. Ambulatory Holter ECG monitoring showed no tachyarrhythmia. Since neither the patient nor his family members had ever experienced any arrhythmic symptom, syncope, or aborted sudden cardiac death, electrophysiological study

was not performed. The patient was recommended to avoid medications that might induce Brugada-like ECG changes and to receive urgent specific treatment for fever. He was asymptomatic during a year follow-up.

DISCUSSION

Brugada syndrome was first described in 1992 as a new autosomal dominant inherited channelopathy occurring in the structurally normal heart, characterized by ST-segment elevation in the right precordial leads, right bundle branch block, and susceptibility to ventricular tachyarrhythmias.^[2]

Wilde et al.^[3] reported three patterns of repolarization as the ECG criteria for Brugada syndrome: a coved-type ST-segment elevation of ≥ 2 mm (type 1); saddle-back type with J-wave amplitude ≥ 2 mm giving rise to a gradually descending ST elevation remaining ≥ 1 mm above baseline (type 2); and coved-type or saddle-back type ST elevation of ≤ 2 mm (type 3). ST-segment elevation in Brugada syndrome

may be dynamic over time. Sodium-channel blockers such as ajmaline, flecainide, procainamide, vagotonic agents, α -adrenergic agonists, β -adrenergic blockers, tricyclic antidepressants, glucose-induced insulin secretion, fever, hyperkalemia, hypokalemia, hypercalcemia, alcohol, and cocaine can unmask or induce this ECG pattern.

Mutations in the cardiac sodium-channel gene (SCN5A gene encoding the alpha-subunit of the cardiac sodium channel) are implicated in Brugada syndrome.^[4-6] These mutations result in depression or loss of function of the sodium channel. Inhibition of the sodium channel current causes heterogeneous loss of the action potential dome during the plateau phase (phase 2) in the right ventricular epicardium, but not in the endocardium. This results in a transmural and epicardial voltage gradient, marked dispersion of repolarization and refractoriness, and potential for phase 2 reentry. The voltage gradient in the epicardium and the transmural dispersion underlie the appearance of ST-segment elevation in the right precordial leads and the development of a vulnerable window across the ventricular wall. The epicardial dispersion of repolarization facilitates the development of phase 2 reentry, which generates a phase 2 reentrant extrasystole that captures the vulnerable window to precipitate ventricular tachycardia and/or fibrillation that often results in sudden cardiac death.

These ionic shifts are temperature dependent.^[1] Dumaine et al.^[7] reported an accelerated inactivation of the cardiac sodium channel at high temperatures, associated with the T1620M missense mutation. Keller et al.^[8] identified a novel SCN5A mutation, F1344S, in a patient with Brugada syndrome and fever-induced ventricular fibrillation. The mutation resulted in loss of sodium channel function due to shift of activation. Temperature simulating fever resulted in a further shift of activation and reduction in the slope factor, which reduced sodium currents availability and triggered the manifestation of the Brugada phenotype.

Prompt investigation and treatment of the patients with fever-associated Brugada-like ECG changes may be lifesaving.^[9] Junttila et al.^[10] reported that most of their patients with fever and Brugada-type ECG developed malignant arrhythmias shortly after the onset of fever, regardless of the existence of a predisposing genetic base. Thus, fever should be vigorously treated with antipyretics in these patients. Loop recorder is recommended for therapeutic decision of these patients.^[11]

Since our patient had never experienced any arrhythmic symptom, syncope, or spontaneous type 1 ECG, and none of his family members had experienced sud-

den cardiac death, electrophysiological study was not performed and he was not referred for defibrillator implantation. The patient was strongly recommended to avoid certain medications responsible for Brugada-like ECG changes and to receive urgent treatment for fever. In conclusion, fever may induce Brugada-like ECG changes and ventricular fibrillation. Accurate diagnosis and prompt treatment of fever are essential in these patients to prevent ventricular fibrillation.

REFERENCES

1. Antzelevitch C, Brugada P, Borggrefe M, Brugada J, Brugada R, Corrado D, et al. Brugada syndrome: report of the second consensus conference: endorsed by the Heart Rhythm Society and the European Heart Rhythm Association. *Circulation* 2005;111:659-70.
2. Brugada P, Brugada J. Right bundle branch block, persistent ST segment elevation and sudden cardiac death: a distinct clinical and electrocardiographic syndrome. A multicenter report. *J Am Coll Cardiol* 1992;20:1391-6.
3. Wilde AA, Antzelevitch C, Borggrefe M, Brugada J, Brugada R, Brugada P, et al. Proposed diagnostic criteria for the Brugada syndrome: consensus report. *Circulation* 2002;106:2514-9.
4. Yan GX, Antzelevitch C. Cellular basis for the Brugada syndrome and other mechanisms of arrhythmogenesis associated with ST-segment elevation. *Circulation* 1999;100:1660-6.
5. Alings M, Wilde A. "Brugada" syndrome: clinical data and suggested pathophysiological mechanism. *Circulation* 1999;99:666-73.
6. Gussak I, Antzelevitch C, Bjerregaard P, Towbin JA, Chaitman BR. The Brugada syndrome: clinical, electrophysiologic and genetic aspects. *J Am Coll Cardiol* 1999;33:5-15.
7. Dumaine R, Towbin JA, Brugada P, Vatta M, Nesterenko DV, Nesterenko VV, et al. Ionic mechanisms responsible for the electrocardiographic phenotype of the Brugada syndrome are temperature dependent. *Circ Res* 1999;85:803-9.
8. Keller DI, Huang H, Zhao J, Frank R, Suarez V, Delacrétaiz E, et al. A novel SCN5A mutation, F1344S, identified in a patient with Brugada syndrome and fever-induced ventricular fibrillation. *Cardiovasc Res* 2006;70:521-9.
9. Kalra S, Iskandar SB, Duggal S, Smalligan RD. Fever-induced ST-segment elevation with a Brugada syndrome type electrocardiogram. *Ann Intern Med* 2008; 148:82-4.
10. Junttila MJ, Gonzalez M, Lizotte E, Benito B, Vernoooy K, Sarkozy A, et al. Induced Brugada-type electrocardiogram, a sign for imminent malignant arrhythmias. *Circulation* 2008;117:1890-3.
11. Patruno N, Pontillo D, Achilli A, Ruggeri G, Critelli G. Electrocardiographic pattern of Brugada syndrome disclosed by a febrile illness: clinical and therapeutic implications. *Europace* 2003;5:251-5.