

## Coil embolization of a traumatic arteriovenous fistula of the lower extremity

### Alt ekstremitte travmatik arteriyovenöz fistülünün koil ile tıkanması

Mustafa Topuz, M.D., Mehmet Coşgun, M.D., Ömer Şen, M.D., Murat Çaylı, M.D.

Department of Cardiology, Adana Numune Training and Research Hospital, Adana

**Summary**– Arteriovenous fistulas (AVFs) are unusual connections between the arterial and venous system that bypass the normal anatomic capillary beds. This case report presents an arteriovenous fistula of the lower extremity caused by a penetrating injury. The patient was diagnosed by Duplex ultrasonography. Diagnostic catheterization of the affected limb showed a high-flow AVF between the left profunda femoris artery and left femoral vein with a deep femoral vein aneurysm measuring 9x4 cm. The AVF was successfully treated with coil embolization.

An arteriovenous fistula (AVF) is an anomalous direct communication between an artery and a vein that results in shunting of blood between the two. Although AVFs may be congenital, many of them are traumatic, and often iatrogenic due to increasing numbers of invasive procedures, especially percutaneous femoral artery cannulation.<sup>[1]</sup>

Non-iatrogenic trauma due to penetrating injuries or long bone fractures causing direct arterial trauma can lead to AVF formation.<sup>[2,3]</sup> Although approximately 60% of patients with traumatic AVFs are diagnosed within a week of injury, patients may present with delayed symptoms weeks to years later.<sup>[4]</sup> Symptoms suggestive of an AVF include abnormal sensation (e.g. vibration) in the groin, fatigue, and new onset or worsened lower extremity ischemia. The clinical diagnosis of AVF is made by palpation and auscultation of the affected vessel, which may demonstrate a machinery-like murmur, bruit, hematoma or pulsatile mass. The patient may exhibit lower extremity edema.<sup>[5]</sup>

**Özet**– Arteriyovenöz (AV) fistüller arter ve ven sistemi arasında normal anatomik kapiller yatağı baypas eden anormal bağlantılardır. Biz bu olguda penetran yaralanmaya bağlı olarak alt ekstremitede AV fistül gelişen bir hasta sunduk. Arteriyovenöz fistül tanısı Doppler ultrasonografi ile konuldu. Tanısal kateterizasyonda sol arteriya profunda ile sol femoral ven arasında yüksek akımlı ve derin femoral vende 9x4 cm çapında anevrizma oluşturan AV fistül gösterildi. Arteriyovenöz fistül başarılı şekilde koil ile tıkanarak kapatıldı.

This report presents a 25-year-old man with a traumatic AVF due to stabbing.

### CASE REPORT

A 25-year-old male was admitted to our clinic with a two-week history of left lower limb pain and presenting a pulsatile mass in the gluteal region. His blood pressure was 110/80 mmHg, heart rate 65/min. His physical examination at admission was within normal limits, except for the pulsatile mass in the gluteal fossa. The femoral pulse and other pulses were palpable in the left lower limb. Color-Doppler ultrasonography of the affected limb showed a left deep femoral vein aneurysm without intraluminal thrombi, associated with an AVF of the left profunda femoris artery. He had a history of stabbing to the gluteal area. According to the patient's report, his physical examination in the emergency department had revealed a single 2 cm laceration along the medial side of the left gluteal area inferior to the intertrochanteric plane. The wound had been treated with primary suture and patient had been

Received: June 17, 2015 Accepted: July 06, 2015

Correspondence: Dr. Mustafa Topuz. Adana Numune Eğitim ve Araştırma Hastanesi, Kardiyoloji Kliniği, 01150 Çukurova, Adana.

Tel: +90 322 - 355 01 01 e-mail: topuzm46@gmail.com

© 2015 Turkish Society of Cardiology



discharged. After explaining the necessity of the procedure and obtaining the patient's informed consent, diagnostic angiography was performed to detect the additional vascular injuries. The Seldinger technique was used and a 6F introducer was inserted into the right femoral artery. A 6F Judkins right catheter was advanced into the left profunda femoris artery. The diagnostic angiography revealed an AVF of large diameter and high volume between the second perforating branch of left profunda femoris artery and femoral vein, with early venous phase filling suggesting a left deep femoral vein aneurysm (9x4 cm) (Figure 1a). We decided to proceed via a percutaneous embolization of the fistula. Prior to the procedure, the patient received 80 units/kg of Unfractionated Heparin. The diagnostic catheter was changed, and a 6F Judkins guiding catheter was inserted into the first perforating branch of the left profunda femoris artery. A 0.014 inch floppy guidewire was introduced into the aneurysm and a balloon inflation with a 3.5 x 15 mm balloon performed to determine appropriate coil size prior to coil embolization and to detect any other connection (Figure 1b). A 9 mm Codman platinum microcoil, twice in size of the fistula diameter, was deployed successfully. One minute later, the fistula was found to be closed and the procedure was completed (Figure 1c).

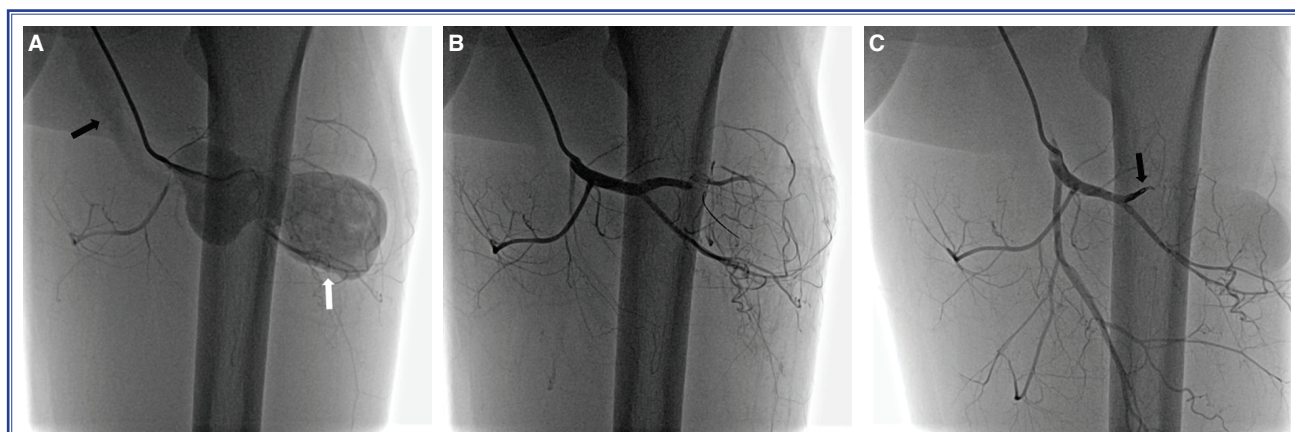
## DISCUSSION

AVF treatment aims to isolate and close the site of arteriovenous communication. The recommended strategy in AVF is that treatment be undertaken as soon as possible for prevention of subsequent complications.

A conservative expectant policy can be adopted in patients with asymptomatic AVFs involving very small fistulas such as those occasionally associated with biopsy or other medical procedures,<sup>[6]</sup> but others should be treated to prevent secondary complications, which include arterial and venous dilation proximal to the fistula, leg edema and ulceration.<sup>[4]</sup> Serious complications such as fistula rupture, neuropathy, distal embolus and thrombosis may also occur.<sup>[5]</sup> In the case of longstanding fistulas, cardiac overload develops and may lead to cardiac failure and endocarditis. These changes may not be totally reversible after closure of the AVF and may require further operative intervention with a potentially poor outcome.<sup>[7]</sup>

Digital subtraction arteriography remains the gold standard for diagnosing AVF, but less invasive tools such as duplex color Doppler, computed tomography or magnetic resonance imaging allow for quick and accurate diagnosis.<sup>[8]</sup> Although arteriograms are performed routinely when there is clinical evidence of vascular injury following penetrating wounds, they are not commonly performed in the presence of a penetrating wound with normal vascularity. In the present case, the patient had a normal vascular and neurological examination except for the pulsation. Hence, we first performed a duplex scan and followed with digital subtraction angiography which revealed the AVF.

Although surgical closure of AVFs remains the gold standard, other treatment options include covered stent and coil embolization. Percutaneous embolization is an effective and minimally invasive alternative to open surgery.<sup>[9]</sup> Embolization of the feeding artery



**Figure 1.** (A) The arteriovenous fistula between the profunda femoris artery and femoral vein (black arrow) with a large aneurysm in the deep femoral vein (white arrow). (B) Balloon inflation to detect any other injuries. (C) Coil embolization (arrow) of the AV fistula and control angiography.

with coils is appropriate if the artery can be safely sacrificed, the flow velocity and size of the fistula allow accurate, secure coil positioning without the risk of coils dislodging, and, most importantly, in a single communication. We performed a balloon inflation to discover any other connection. Coils need to be appropriately oversized compared to the target vessel to avoid risk of migration, but not so large as to elongate and occupy non-target territory. Although embolization is indicated and surgery is specifically contraindicated in the treatment of complex AVFs with many feeding and draining vessels, we showed that coil embolization is also successful in the treatment of an AVF with single connection and high flow rate.

From a technical point of view, the site of coil occlusion is important because getting too close to the orifice of the artery may jeopardize the arterial flow while being too close to the drainage orifice may cause the coil to go into the venous circulation.<sup>[9]</sup> Fistula leak is another long-term consideration and an adequate amount of coil deployment is important. Flow should diminish within a few minutes.

In addition to traditional surgical treatment and coil embolization, implantation of a covered stent, previously described by Summari et al., is another option, especially in the presence of a single AVF.<sup>[10]</sup> In certain very high-flow or difficult situations, it may be desirable to use a liquid agent that polymerizes rapidly or in a more controlled manner, such as cyanoacrylate glue or Onyx (Covidien, Mansfield, MA) respectively.<sup>[11]</sup> These agents may be used in conjunction with other devices or techniques (e.g. after initial coil deployment or with a proximal occluding balloon) to reduce AVF flow and the risk of non-target embolization.<sup>[12]</sup>

To avoid the risk of accidental coil migration, a new generation of vascular plugs offer a therapeutic option for AVF closure. The Amplatzer Vascular Plug was originally designed to occlude peripheral arteriovenous malformations.<sup>[13]</sup> Such devices were not thought suitable for closure use in this case due to aneurysm formation.

Although incomplete treatment of an AVF may lead to certain recurrence with a more complex architecture that is more troublesome and challenging to treat, the endovascular approach can be used safely if the initial treatment is carefully planned and executed for a successful and durable result.

**Conflict-of-interest issues regarding the authorship or article: None declared.**

## REFERENCES

1. Finlay DJ, Sanchez LA, Sicard GA. Subclavian artery injury, vertebral artery dissection, and arteriovenous fistulae following attempt at central line placement. *Ann Vasc Surg* 2002;16:774–8. [CrossRef](#)
2. Salander JM, Youkey JR, Rich NM, Olson DW, Clagett GP. Vascular injury related to lumbar disk surgery. *J Trauma* 1984;24:628–31. [CrossRef](#)
3. Smith DE, McGraw RW, Taylor DC, Masri BA. Arterial complications and total knee arthroplasty. *J Am Acad Orthop Surg* 2001;9:253–7.
4. Erdöl C, Baykan M, Gökçe M, Celik S, Sari A, Uzun Z, et al. Congestive heart failure associated with chronic venous insufficiency and leg ulcers secondary to an arteriovenous fistula caused by a shotgun wound 15 years ago. *Vasa* 2002;31:125–8.
5. Stigall KE, Dorsey JS. Late complications of traumatic arteriovenous fistula. Case report and overview. *Am Surg* 1989;55:180–3.
6. Kent KC, McArdle CR, Kennedy B, Baim DS, Anninos E, Skillman JJ. A prospective study of the clinical outcome of femoral pseudoaneurysms and arteriovenous fistulas induced by arterial puncture. *J Vasc Surg* 1993;17:125–33. [CrossRef](#)
7. Mellièrè D, Hassen-Khodja R, Cormier JM, Le Bas P, Mikati A, Ronsse H. Proximal arterial dilatation developing after surgical closure of long-standing posttraumatic arteriovenous fistula. *Ann Vasc Surg* 1997;11:391–6. [CrossRef](#)
8. Chen JK, Johnson PT, Fishman EK. Diagnosis of clinically unsuspected posttraumatic arteriovenous fistulas of the pelvis using CT angiography. *AJR Am J Roentgenol* 2007;188:269–73.
9. Alekyan BG, Podzolkov VP, Cárdenas CE. Transcatheter coil embolization of coronary artery fistula. *Asian Cardiovasc Thorac Ann* 2002;10:47–52. [CrossRef](#)
10. Summari F, Romagnoli E, Preziosi P. Percutaneous antegrade transarterial treatment of iatrogenic radial arteriovenous fistula. *J Cardiovasc Med (Hagerstown)* 2012;13:50–2. [CrossRef](#)
11. Numan F, Omeroglu A, Kara B, Cantaşdemir M, Adaletli I, Kantarci F. Embolization of peripheral vascular malformations with ethylene vinyl alcohol copolymer (Onyx). *J Vasc Interv Radiol* 2004;15:939–46. [CrossRef](#)
12. Barley FL, Kessel D, Nicholson T, Robertson I. Selective embolization of large symptomatic iatrogenic renal transplant arteriovenous fistula. *Cardiovasc Intervent Radiol* 2006;29:1084–7. [CrossRef](#)
13. Wang W, Li H, Tam MD, Zhou D, Wang DX, Spain J. The amplatzer vascular plug: a review of the device and its clinical applications. *Cardiovasc Intervent Radiol* 2012;35:725–40.

**Keywords:** Arteriovenous fistulas; fistula/therapy; coil embolisation.

**Anahtar sözcükler:** Arteriyovenöz fistül; fistül/teravi; koil tıkama.