

What should be done in the event of simultaneous massive pulmonary embolism and myocardial infarction with ST elevation?

Yoğun pulmoner emboli ve ST yükselmeli miyokart enfarktüsü eşzamanlı birlikteliğinde ne yapmalıyız?

Recep Akgedik, M.D., Zeki Yüksel Günaydın, M.D.,# Berna Botan Yıldırım, M.D.,
Canan Eren Dağlı, M.D., Osman Bektaş, M.D.#

Department of Chest Diseases, Ordu University Faculty of Medicine, Ordu

#Department of Cardiology, Ordu University Faculty of Medicine, Ordu

Summary– Massive pulmonary embolism (MPE) and acute myocardial infarction (AMI) are life-threatening conditions with well-known diagnosis and treatment. Symptoms and findings such as dyspnea, chest pain, hypotension, ECG changes and elevation of cardiac enzymes are seen in both diseases. However, MPE and AMI are rarely simultaneous in a single case. This report presents an 85-year-old patient with simultaneous MPE and AMI with ST elevation. While treatment strategies for both MPE and AMI have been adequately described, it is not clear which treatment to choose when both emergency pathologies occur simultaneously in one patient. This case report discusses the treatment of these two diseases in such a case.

Acute myocardial infarction (AMI) and acute pulmonary embolism (APE) are frequently-encountered diseases with well-known diagnosis and treatment, and high mortality. Symptoms and findings such as dyspnea, chest pain, syncope, hemodynamic instability and cardiac arrest appear in both. Differential diagnosis can generally be easily made, based on clinical and laboratory findings, electrocardiography, echocardiography and pulmonary angiography. However, in some cases, a definitive diagnosis may not be possible in a short time in spite of all diagnostic tests.^[1-3]

Here is presented an 85-year-old patient with simultaneous AMI and APE. Alongside the case, the treatment of these two diseases when found to develop simultaneously in the same patient will be discussed.

Özet– Yoğun pulmoner emboli (YPE) ve akut miyokart enfarktüsü (AME) tanı ve tedavisi iyi bilinen hayatı tehdit eden hastalıklardır. Dispne, göğüs ağrısı, hipotansiyon, EKG değişiklikleri ve kardiyak enzim yükseklikleri her iki hastalıkta da görülebilen ortak semptom ve bulgulardır. Hem YPE hem de AME tedavi stratejileri yeteri kadar açık olarak tanımlanmıştır. Yoğun pulmoner emboli ve AME oldukça nadiren bir hastada eş zamanlı bulunabilir. Ancak bir hastada bu iki acil patolojinin eş zamanlı bulunması durumunda seçilecek tedavi açık değildir. Bu yazıda eş zamanlı YPE ve ST yükselmeli AME tanısı koyduğumuz 85 yaşındaki hasta sunuldu. Bir hastada bu iki hastalığın birlikte bulunması durumunda tedavi seçeneklerini olgumuz ve literatür eşliğinde tartışıldı.

CASE REPORT

An 85-year-old woman with no known prior diseases except hypertension/hypotension (HT) presented to emergency with dyspnea, chest pain and poor general condition. A brief syncope episode had occurred two hours prior to presentation. Upon physical examination, her blood pressure (BP) was 90/50 mmHg, pulse 130/min and respiratory rate 25 breaths/minute. She was found to have pitting edema and redness in the right calf and diffuse wheezing on physical examination.

The patient's cardiac rhythm was sinus rhythm on electrocardiography (ECG) (HR: 130/min) and there were slight ST elevations in V1-4, Q wave (Q pattern)

Received: May 06, 2015 Accepted: July 10, 2015

Correspondence: Dr. Recep Akgedik. Ordu Üniversitesi Tıp Fakültesi,

Göğüs Hastalıkları Anabilim Dalı, 52200 Ordu.

Tel: +90 452 - 234 50 10 e-mail: recepakgedik@hotmail.com

© 2015 Turkish Society of Cardiology



in D3 derivation (Figure 1a). The patient's chest x-ray was unremarkable. Laboratory examination revealed the following: WBC 10300/ml (range: 4.6-10.2), hemoglobin 11.1 g/dl (range: 12-18), Hct 34.6% (37-63), CRP 15.9 mg/dl (0-0.5), D-Dimer 3716 ng/ml (0-500), Pro-BNP 1542 pg/ml (0-100), Troponin-I 9.6 ng/ml (0-0.028); blood gas analysis, pH 7.47, PCO₂ 31, PO₂ 62, HCO₃ 24, SO₂ 85. Other laboratory tests were within normal ranges.

Transthoracic echocardiography (TTE) revealed an ejection fraction (EF) of 50% and dilation in the right chambers and an estimated pulmonary artery systolic pressure (ePASP) of 55 mmHg. In addition to the findings of right sided loading, McConnell's sign and hypokinesia in the apical wall of the left ventricle was present. The interatrial septum was intact with no passage demonstrated by color Doppler.

A computed tomography pulmonary angiography (CTPA) was obtained because the patient's Well's score was elevated. Filling defects in both the main

pulmonary artery and its branches contributed to pulmonary embolism (PE) (Figure 2). She was accepted as having a high risk pulmonary embolism (PE) with the syncope episode, hypotension, and TTE findings. The CTPA showed a PE, and this, together with elevation in troponin level, ST elevation in the ECG, and apical hypokinesia seen in the echocardiography, suggested the presence of an AMI. The patient was admitted to the intensive care

Abbreviations:

AMI	Acute myocardial infarction
APE	Acute pulmonary embolism
BP	Blood pressure
CTPA	Computed tomography pulmonary angiography
DVT	Deep vein thrombosis
ECG	Electrocardiography
EF	Ejection fraction
ePASP	Estimated pulmonary artery systolic pressure
HT	Hypertension/hypotension
IVT	Intravenous systemic thrombolytic treatment
LV	Left ventricle
PCA	Percutaneous coronary angiography
PCI	Percutaneous coronary angiographic intervention
PE	Pulmonary embolism
Ptx	Pneumothorax
RV	Right ventricle
SBP	Systemic blood pressure
TTE	Transthoracic echocardiography

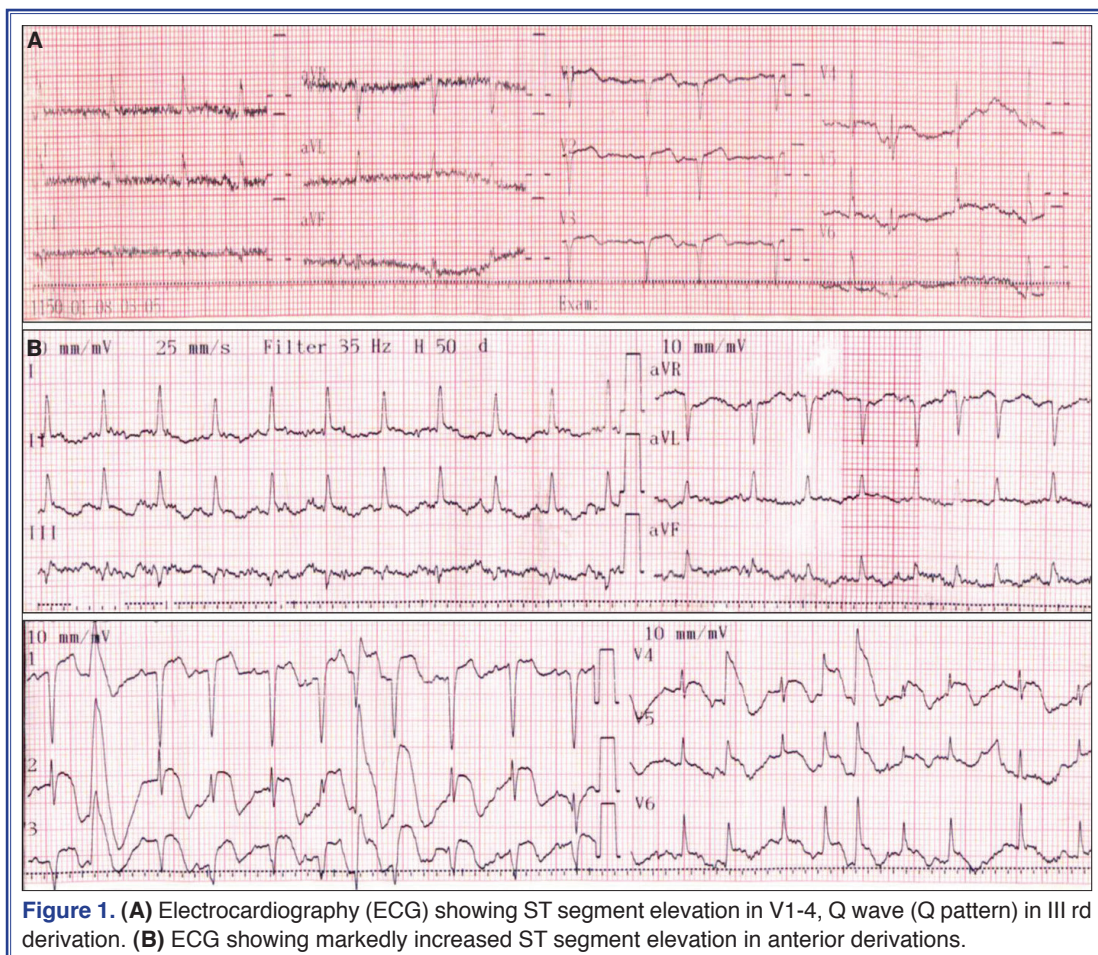


Figure 1. (A) Electrocardiography (ECG) showing ST segment elevation in V1-4, Q wave (Q pattern) in III rd derivation. (B) ECG showing markedly increased ST segment elevation in anterior derivations.

unit with the preliminary diagnoses of APE and AMI. Since the poor general condition of the patient persisted (TA <90), r-TPA (100 mg/2 hours) was administered as per the decision of both the chest disease and cardiology specialists, assuming that both vascular diseases could be treated in this manner. Enoxaparin (6000 units), clopidogrel (600 mg), and acetylsalicylic acid (300 mg) were immediately initiated following the r-TPA infusion.

The patient's oxygen requirement decreased, dyspnea regressed, and BP was elevated (BP: 110/70) after r-TPA treatment. However, increased ST elevations were detected in the anterior derivations in the follow-up ECG (Figure 1b). Control troponin-I was elevated to 19.06 ng/ml. This confirmed the simultaneous presence of PTE and anterior AMI. Coronary reperfusion could not be restored, and therefore a percutaneous coronary angiography (PCA) with the aim of emergent coronary revascularization was performed and stenosis of 90% in two consecutive locations in the mid section of left anterior descending artery (LAD) and total occlusion in the well-developed septal one were detected (Figure 3). Since the diameter of the vessel with total occlusion was <2 mm, no percutaneous coronary angiographic intervention (PCI) was performed. An elective coronary artery bypass surgery was planned. However, the patient had lung edema at the 24th hour of her admission and diuretic treatment was initiated. Noninvasive mechanical ventilation was started since respiratory failure

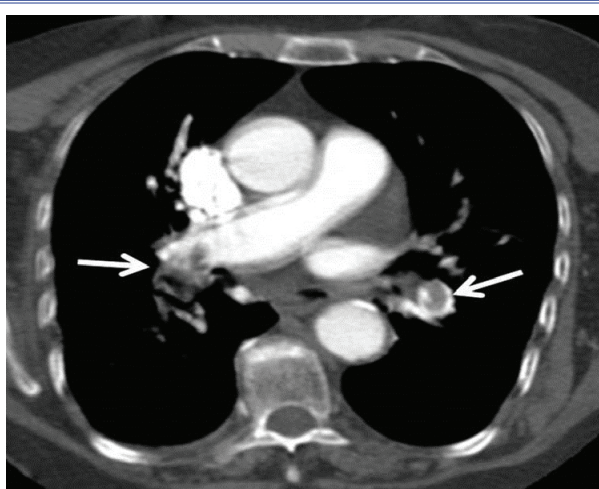


Figure 2. Computed tomographic pulmonary angiogram showing thrombi at bilateral pulmonary arteries (yellow arrows).

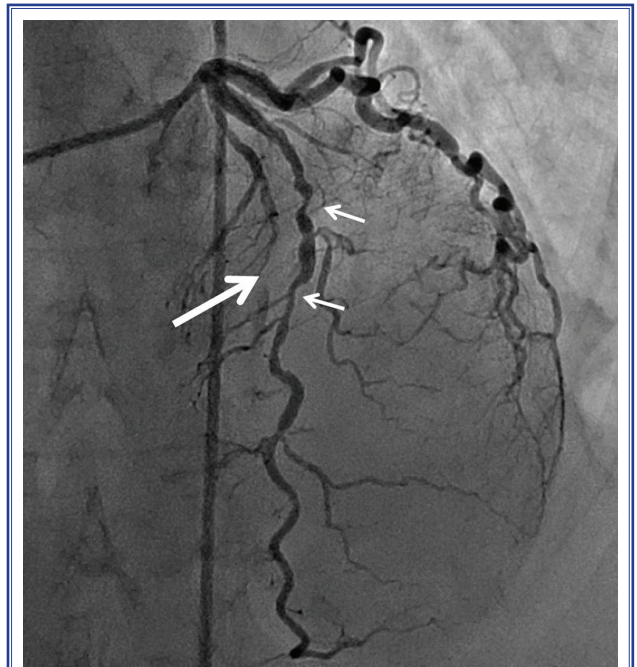


Figure 3. Percutaneous coronary angiography showing 90% stenosis in two consecutive locations in the mid section of left anterior descending artery (white arrows) and total occlusion in the well-developed septal one (yellow arrows).

was prominent. The follow-up TTE demonstrated an EF of 35% with dilation in the right chambers, ePASP of 35 mmHg, and hypokinesia in the apical and lateral walls of the left ventricle. Invasive mechanical ventilation was started when respiratory failure deepened. Pneumothorax (Ptx) due to barotrauma was detected on the third day of admission and a tube thoracostomy was inserted. Ptx was observed to resolve after the intervention. However, the patient was hypotensive with no response to positive inotropic support and she died.

DISCUSSION

The primary aim of sharing this case is to report the simultaneous occurrence of two vascular pathologies, APE and AMI, which are both life-threatening conditions that necessitate emergency interventions. Furthermore, the study aimed to find an answer to the question of selection of first priority treatment in such cases. In the present case, acute PE was detected in the CTPA, r-TPA was applied subsequently, and a total occlusion was detected by the PCA that was performed due to increased ST elevations in the ECG and increased cardiac troponin levels. The simultaneous

occurrence of the two diseases was clearly demonstrated in this case.

Clinical and laboratory findings seen in APE, such as dyspnea, chest pain, hypotension, ECG changes, and elevated D-dimer are also seen in AMI. In the current case, clinical and laboratory findings such as LV apical hypokinesia in addition to acute onset dyspnea, chest pain, history of a syncope episode, deep vein thrombosis (DVT) findings, ST elevation in anterior derivations in the ECG, elevations of D-dimer and troponin levels, and findings of acute right sided loading in TTE supported both pathologies. Initially, a diagnosis of APE was assumed, since the syncope attack and DVT were clearly apparent in addition to TTE findings.

APE and AMI are rarely simultaneously present in a single case. When the coexistence of these two conditions are discussed, the first diagnosis to be considered should be PE and coronary artery embolism due to paradoxical embolus.^[4] However, the coexistence of APE and AMI is extremely rare in the absence of pulmonary AV shunts, patent foramen ovale and intracardiac shunts that would suggest paradoxical embolism. In this case, CTPA and TTE demonstrated no AV shunts and the findings of PCA suggested AMI secondary to atherosclerosis instead of paradoxical embolism.

Pulmonary arterial pressure (PAB) is found to increase in APE as a result of a stenosis of more than 30-50% of the vascular bed and vasoconstriction secondary to the mediators released. Subsequently, the work load and oxygen demand on the right ventricle (RV) increase with a decreased RV output. Therefore, left ventricle (LV) preload decreases. LV cardiac output and systemic blood pressure (SBP) decrease. An attempt to regulate SBP is made through triggered neurohumoral activity and systemic vasoconstriction due to other compensatory mechanisms and positive inotropic-chronotropic effects. In conclusion, the work load and oxygen demand of the left side of the heart increases.^[1] Our decision in this case is that the AMI could have been triggered by the above-mentioned mechanisms.

Patients with massive PE are under high risk of in-hospital mortality, especially in the first couple of hours after admission.^[5,6] The treatment modalities selected in high risk PE are intravenous systemic

thrombolytic treatment (IVT), percutaneous catheter directed treatment (PCDT) (with or without local thrombolytic treatment), and surgical embolectomy.^[1] Randomized studies have consistently demonstrated that IVT rapidly resolves thromboembolic obstruction and has beneficial effects on hemodynamic parameters.^[1,7] Therefore, when not contraindicated for any reason, IVT is the first line treatment in high risk PE compared to other treatment alternatives.^[1]

Emergency PCI and IVT for reperfusion are treatment options in AMI with ST elevation. PCI has been repeatedly demonstrated to be superior to IVT in randomized trials comparing timely PCI and IVT performed in centers with a high volume and high experience.^[8,9]

Bhatia et al. reported a case with coexistent APE and AMI. A 55-year-old male patient with a history of coronary artery disease was brought to the emergency service with cardiac arrest; a response was obtained to resuscitation and PCA and AMI were detected. In spite of signs of APE in the TTE, IVT could not be administered due to the bleeding risk secondary to a previous arteriotomy. In addition, surgical or catheter embolectomy could not be performed due to the unstable condition of the patient. The diagnosis of pulmonary embolism was confirmed by autopsy.^[10]

Xie et al. reported a case of a 55-year-old female patient with coexistence of a massive PE and AMI. They administered IVT (urokinase, 150 billion units /2 hours) to the patient. They reported that the patient was cured of both vascular pathology and was discharged from hospital with this treatment strategy.^[11] We preferred an IVT treatment strategy similar to Xie et al. but with a different treatment; 100 mg r-TPA /2 hours.

The treatment strategies for both MI with ST elevation and high risk APE have been adequately demonstrated and clearly defined beyond dispute. However, it is not clear which treatment to choose when both emergency pathologies are seen together in one patient. IVT can treat both vascular conditions in such a case. It is easily applied and its risks are lower when compared to other treatment methods. Thrombolytic treatment may elicit risks due to the arteriotomy performed when PCI is first applied and options of surgical and catheter embolectomy remain to be selected in such a case. The latter modalities could only be

performed in large and experienced centers and carry a higher risk compared to thrombolytic treatment.^[1] Therefore, we selected the treatment strategy stated above. Nevertheless, the required dose and time of IVT treatment is unknown in cases with coexistence of these two conditions. r-TPA is initiated in AMI at bolus infusion dose of 100 mg/1.5 hours, while it is administered at a dose of 100 mg/2 hours without a bolus loading dose in HRPE.^[1,2] In the current case, we decided to administer the IVT dose and time that is usually administered in PE treatment due to the advanced age and bleeding risk of the patient.

The oxygen saturation of the patient was elevated and her hypotension was resolved with this treatment. There were no complications other than lung edema and respiratory distress necessitating mechanical ventilation. The patient died due to unexpected Ptx secondary to barotrauma, the presence of two severe vascular diseases, and particularly due to advanced age. The length of r-TPA treatment could be curtailed as performed in the treatment of AMI in a younger patient with the coexistence of high risk APE and AMI; perhaps that treatment could have been more effective. However, more experience is required on this subject.

In conclusion, it should be taken into account that the coexistence of APE and AMI, although very rare, may present in a single case. Unless it is absolutely contraindicated, thrombolytic treatment could be recommended in such conditions with coexistence of two vascular pathologies.

Conflict-of-interest issues regarding the authorship or article: None declared.

REFERENCES

1. Konstantinides SV, Torbicki A, Agnelli G, Danchin N, Fitzmaurice D, Galiè N, et al. 2014 ESC guidelines on the diagnosis and management of acute pulmonary embolism. *Eur Heart J* 2014;35:3033–69. [CrossRef](#)
2. O'Gara PT, Kushner FG, Ascheim DD, Casey DE Jr, Chung MK, de Lemos JA, et al. 2013 ACCF/AHA guideline for the management of ST-elevation myocardial infarction: a report of the American College of Cardiology Foundation/American Heart Association Task Force on Practice Guidelines. *Circulation* 2013;127:362–425. [CrossRef](#)
3. Bajaj N, Bozarth AL, Guillot J, Kojokittah J, Appalaneeni SR, Cestero C, et al. Clinical features in patients with pulmonary embolism at a community hospital: analysis of 4 years of data. *J Thromb Thrombolysis* 2014;37:287–92. [CrossRef](#)
4. Cheng TO. Coronary embolism. *Int J Cardiol* 2009;136:1–3.
5. Stein PD, Henry JW. Prevalence of acute pulmonary embolism among patients in a general hospital and at autopsy. *Chest* 1995;108:978–81. [CrossRef](#)
6. Werth S, Kamvissi V, Stange T, Kuhlisch E, Weiss N, Beyer-Westendorf J. Outpatient or inpatient treatment for acute pulmonary embolism: a retrospective cohort study of 439 consecutive patients. *J Thromb Thrombolysis* 2015;40:26–36.
7. Jaff MR, McMurtry MS, Archer SL, Cushman M, Goldenberg N, Goldhaber SZ, et al. Management of massive and submassive pulmonary embolism, iliofemoral deep vein thrombosis, and chronic thromboembolic pulmonary hypertension: a scientific statement from the American Heart Association. *Circulation* 2011;123:1788–830. [CrossRef](#)
8. Zijlstra F, Hoorntje JC, de Boer MJ, Reiffers S, Miedema K, Ottervanger JP, et al. Long-term benefit of primary angioplasty as compared with thrombolytic therapy for acute myocardial infarction. *N Engl J Med* 1999;341:1413–9. [CrossRef](#)
9. Andersen HR, Nielsen TT, Rasmussen K, Thuesen L, Kelbaek H, Thayssen P, et al. A comparison of coronary angioplasty with fibrinolytic therapy in acute myocardial infarction. *N Engl J Med* 2003;349:733–42. [CrossRef](#)
10. Bhatia N, Vongooru H, Ikram S. Acute myocardial infarction and massive pulmonary embolus presenting as cardiac arrest: initial rhythm as a diagnostic clue. *Case Rep Emerg Med* 2013;2013:343918. [CrossRef](#)
11. Xie XJ, Jiang JB, Jiang J, Wang JA. Concurrent pulmonary thrombosis with systemic embolism: a case report. *J Zhejiang Univ Sci B* 2014;15:838–44. [CrossRef](#)

Keywords: Pulmonary embolism; myocardial infarction; thrombolytic treatment.

Anahtar sözcükler: Pulmoner emboli; miyokart enfarktüsü; trombolitik tedavi.