

## An elderly patient with atresia of the left main stem

### *Sol ana koroner arter atrezili yaşlı bir hasta*

Mustafa Topuz

Yücel Çölkese

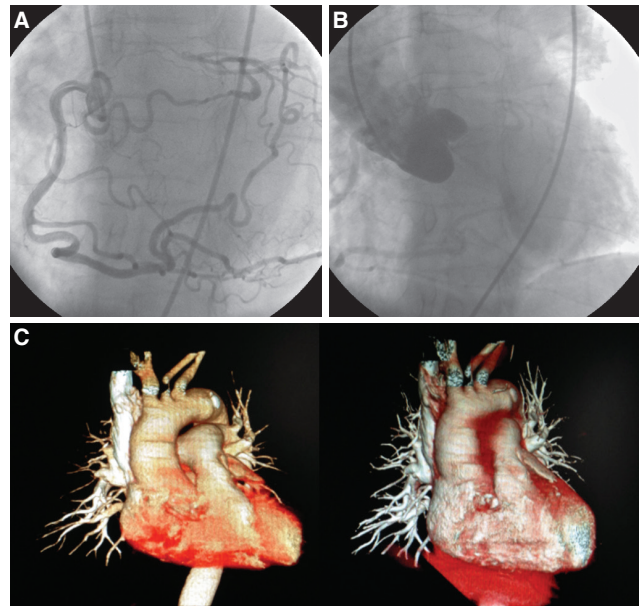
Mehmet Çoşgun

Murat Çaylı

Department of Cardiology,  
Adana Numune Training and  
Research Hospital, Adana

Atresia of the left main coronary artery (LMCA) is a very rare congenital coronary anomaly, and has a wide clinical spectrum, occurring in newborns (1–3 months), as well as in elderly patients. Because of poor clinical outcomes in LCMA atresia, surgical revascularization is recommended regardless of the presence of associated cardiac anomalies. A 76-year-old female was referred to our clinic for evaluating preoperative risk of a planned surgery. Her past medical history was significant for hypertension. The cardiovascular examination of the patient was essentially unremarkable. Electrocardiography showed left bundle branch block with normal sinus rhythm. Echocardiography showed a structurally normal heart with normal left ventricular function, ejection fraction (EF) 60%, and no regional wall motion abnormality. With atypical chest pain and positive exercise stress 201-thallium myocardial scintigraphy (small reversible defects in the anterior and posterolateral walls), the patient was referred to coronary angiography. On selective coronary angiography, cannulation and direct visualization of the LMCA ostium was not possible. There was a large dominant right coronary artery (RCA) originating from the right aortic sinus, with significant intercoronary retrograde collaterals to the left anterior descending (LAD) artery and the left circumflex (LCx) artery via the conus artery branch, posterior lateral and posterior descending branch (Figure A, Video A\*). There was no calcification, or obstructive or non-obstructive atherosclerotic plaques in the coronary arteries. We performed repeated injections to visualize the LMCA ostium, which may arise from the right sinus of Valsalva near the RCA, but there was no opacification. Aortic root angiography showed absence of the LMCA from any other site of the aortic sinus (Figure B, Video B\*). The patient was referred for computed tomography (CT) coronary angiography. The orifice of the LMCA from the

left coronary sinus was not visible (Figure C). After discussion with cardiac surgeons, medical treatment was chosen as the therapeutic approach due to the patient's age and atypical symptoms. Moreover, the extent of ischemia on scintigraphy was not substantial. The patient was discharged with antiplatelet, anti-anginal, beta-blocker and statin therapy. Preoperative risk was determined as low for the patient and she was referred for the planned surgery. There were no adverse cardiac events in the perioperative or postoperative periods. Congenital atresia of the LMCA is a very rare anomaly in adults. Although myocardial revascularization via surgery in adults, and surgical angioplasty in children seem presently to be the best methods of choice, there is a lack of data both on standardization of best therapeutic options for the improvement of myocardial function and surveys of patients because of the limited number of short- and long-term follow-up results, and also due to the rarity of the anomaly.



**Figures– (A)** The significant retrograde collaterals from the RCA to the LAD artery and the LCx artery via the sinus node artery branch and posterior lateral branch. **(B)** The patient's aortic root angiogram. **(C)** The patient's CT coronary angiogram. \*Supplementary video files associated with this presentation can be found in the online version of the journal.