

## Successful coil embolization of a large coronary artery fistula in a patient with congestive heart failure

Konjestif kalp yetersizliği olan bir hastada geniş koroner arter fistülünün coil embolizasyon yöntemiyle kapatılması

Akın İzgi, M.D., Cevat Kıрма, M.D., Muhsin Türkmen, M.D., Ali Cevat Tanalp, M.D.

Department of Cardiology, Kartal Koşuyolu Heart and Research Hospital, İstanbul

Although a minority of coronary artery fistulae are small in caliber and may be asymptomatic throughout life, most cases will require intervention by either transcatheter techniques or surgery because of evolving symptoms. We report a 70-year-old female patient who underwent successful coil embolization of a coronary artery fistula that was associated with congestive heart failure. On presentation, she had dyspnea, palpitation, chest pain, functional capacity of NYHA class III, a pansystolic murmur of grade 3/6 in the right parasternal region, and a continuous murmur of grade 2-3/6 in the second left intercostal space and at the base of the heart. Selective coronary angiography showed a large coronary artery fistula, originating from the proximal left anterior descending coronary artery and draining into the main pulmonary artery. Embolization was performed with placement of one coil in the distal part and two coils in the proximal part of the fistula. The continuous murmur disappeared after the procedure. She was asymptomatic with significantly improved functional capacity at the second-month follow-up.

**Key words:** Arteriovenous fistula/therapy; coronary angiography; coronary vessel anomalies; embolization, therapeutic; heart catheterization.

Koroner arter fistülü az sayıda hastada küçük çaplı ve yaşam boyu asemptomatik olsa da, gelişen semptomlar nedeniyle birçok hastada transkateter veya cerrahi yolla kapatma gerektirir. Bu yazıda, konjestif kalp yetersizliğine bağlı semptomları bulunan 70 yaşındaki kadın hastada saptanan koroner arter fistülünün coil embolizasyon yöntemiyle başarılı şekilde kapatılması sunuldu. Başvuru sırasında hastada, nefes darlığı, çarpıntı, göğüs ağrısı, NYHA sınıf 3 fonksiyonel kapasite, sağ parasternal alanda duyulan 3/6 derecesinde pansistolik üfürüm ve ikinci sol interkostal boşluk ve kalp tabanında işitilen 2-3/6 derecesinde sürekli bir üfürüm vardı. Selektif koroner anjiyografide, proksimal sol ön inen koroner arterden köken alan ve ana pulmoner artere boşalan koroner arter fistülü saptandı. Distal kısmına bir, proksimal kısmına iki coil yerleştirilmesiyle fistül başarılı şekilde kapatıldı. İşlemden sonra sürekli üfürüm kayboldu. İkinci aydaki kontrolü sırasında hasta asemptomatik ve fonksiyonel kapasitesi belirgin derecede artmıştı.

**Anahtar sözcükler:** Arteriyovenöz fistül/tedavi; koroner anjiyografi; koroner damar anomalisi; embolizasyon, terapötik; kalp kateterizasyonu.

A coronary artery fistula is defined as a direct connection between a major epicardial coronary artery and a cardiac chamber or a major vessel such as the vena cava, coronary sinus, or pulmonary artery. This vascular abnormality which may be encountered at any age is the most important hemodynamically significant coronary artery anomaly.<sup>[1,2]</sup> Larger fistulae progressively enlarge over time and complications such as

congestive heart failure, myocardial infarction, arrhythmias, infectious endocarditis, aneurysm formation, rupture, and death are more likely to arise in older patients.<sup>[3-6]</sup> Most lesions enlarge progressively and warrant repair either by transcatheter or surgical techniques. We report successful coil embolization of a large coronary artery fistula that was associated with congestive heart failure.

Received: August 10, 2005 Accepted: December 22, 2005

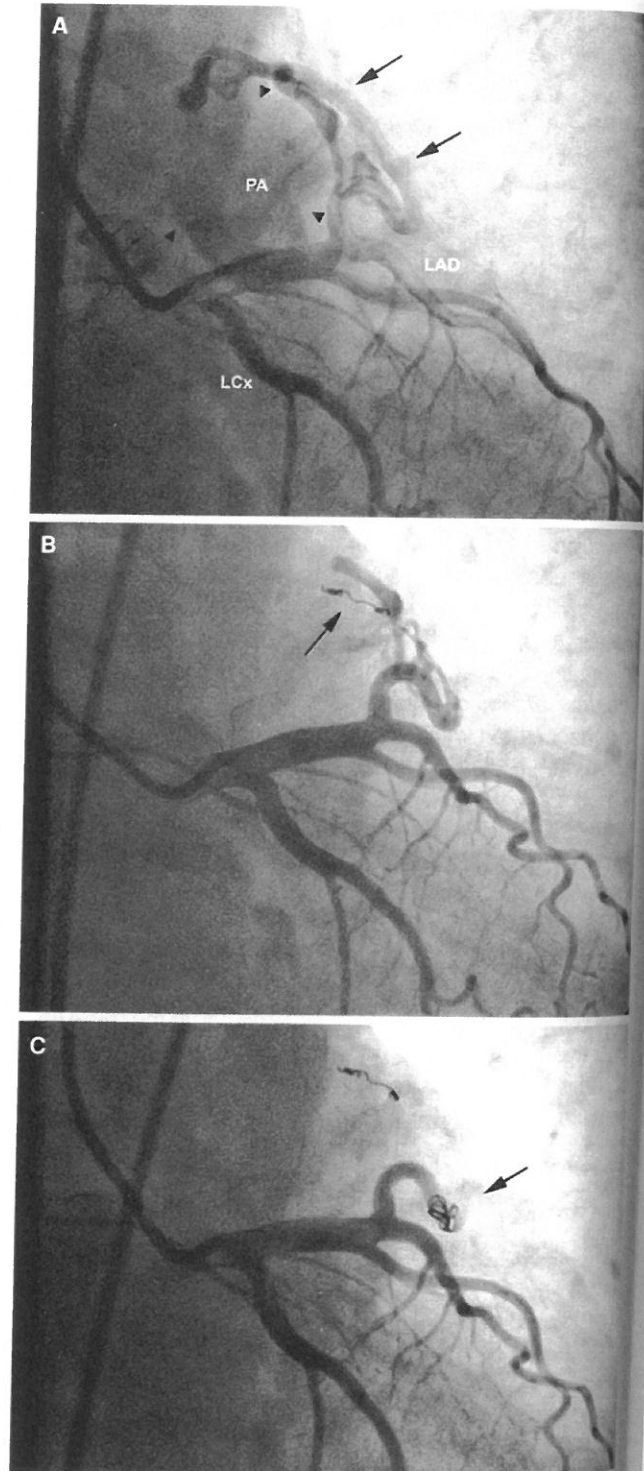
Correspondence: Dr. Akın İzgi, Kartal Koşuyolu Kalp Eğitim ve Araştırma Hastanesi Kardiyoloji Kliniği, 34865 Cevizli, İstanbul.  
Tel: 0216 - 459 40 41 / 1146 Fax: 0216 - 459 63 21 e-mail: akinizgi@hotmail.com

## CASE REPORT

A 70-year-old female patient was admitted with dyspnea, palpitation, and chest pain which had progressively increased in severity over the last three years. On admission, her functional capacity was NYHA class III. She had a history of hypertension which had been stable under medication. Physical examination revealed a pansystolic murmur of grade 3/6 in the right parasternal region and a continuous murmur of grade 2-3/6 in the second left intercostal space and at the base of the heart. The pulmonic component of the second heart sound was increased. Electrocardiography showed atrial fibrillation and horizontal ST-segment depression of 0.5 mm on derivations V3-6. Mild cardiomegaly and a prominent pulmonary conus were noted on a chest radiograph. Biochemical parameters and the hemogram were normal. Transthoracic echocardiography demonstrated biatrial enlargement, turbulent flow inside the main pulmonary artery, grade 3 tricuspid regurgitation, and pulmonary artery pressure of 40 mmHg. The main pulmonary artery was enlarged to a size of 2.6 cm. The left ventricular systolic function was subnormal due to atrial fibrillation with rapid ventricular response.

In the light of clinical, electrocardiographic, and echocardiographic findings, the patient underwent cardiac catheterization, which showed elevated systolic pulmonary artery pressure (49 mmHg) and an oxygen step-up between the right ventricle and the main pulmonary artery from 78% to 90%. There was no difference in oxygen saturation between the right and left pulmonary arteries. Right and left ventriculographies did not show atrial and ventricular septal defects, respectively. However, selective coronary angiography showed a large coronary artery fistula, originating from the proximal left anterior descending (LAD) coronary artery and draining into the main pulmonary artery (Fig. 1a). The left-to-right shunt ratio ( $Q_p/Q_s$ ) was calculated as 1.6.

As the coronary fistula originated from the proximal LAD artery and was in close contact with the first diagonal branch, coil embolization was planned. Intravenous heparin (5,000 U) was administered after insertion of an 8 F sheath. A standard 8 F guiding catheter was inserted into the left coronary artery. A floppy guidewire was placed into the fistula and a microcatheter (RapidTransit; Cordis, Miami, FL; USA) was advanced over the guidewire. The guidewire was withdrawn and a 4x3-mm mini-complex DCS Orbit detachable coil (Cordis, USA) was placed into the distal part of the fistula (Fig. 1b). The



**Fig. 1.** (A) On coronary angiography, a right anterior oblique caudal projection demonstrates a large coronary arteriovenous fistula (arrows) originating from the proximal left anterior descending (LAD) artery and draining into the main pulmonary artery (PA, arrow heads). (LCx, left circumflex coronary artery) (B) The same angiographic view showing incomplete occlusion of the fistula after coil placement to the distal part (arrow) (C) Following the second coil embolization to the proximal part, the fistula completely disappeared (arrow).

occlusion was suboptimal on the 5th-minute control angiography, so two additional coils were placed in the proximal part of the fistula (Fig. 1c). The procedure was terminated without any complications. On auscultation, the continuous murmur disappeared and the patient was discharged at the 48th hour of the procedure. The patient was asymptomatic and her functional capacity improved significantly at the second-month follow-up.

## DISCUSSION

The incidence of coronary artery fistula is 0.1-0.2% on diagnostic coronary angiography.<sup>[7]</sup> Most of the fistulae arise from the right coronary artery (60%) and terminate in the right side of the heart (90%). The most frequent site of termination is the right ventricle. The number of fistulous connections, nature of the feeding vessel or vessels, and the sites of drainage should be identified by coronary angiography before making a decision for the treatment of a symptomatic coronary artery fistula.

The first successful transcatheter closure of a fistula was reported by Reidy et al.<sup>[8]</sup> in 1983. Since then, transcatheter coil occlusion of coronary artery fistulae has evolved as the preferred therapy. Mavroudis et al.<sup>[9]</sup> recommended elective coil occlusion in patients who satisfy the following criteria: absence of multiple fistulae, a single narrow drainage site, absence of involvement of large branch vessels, and safe accessibility to the coronary artery supplying the fistula. Device deployment can either be antegrade (via the femoral vein) or retrograde (via the femoral artery). The transcatheter closure of the fistulae often requires complicated catheter manipulations as well as selection of various catheters and guidewires. Despite successful use of detachable balloons,<sup>[10]</sup> various chemicals,<sup>[11]</sup> covered stents,<sup>[12]</sup> duct occluders and umbrellas,<sup>[13]</sup> the use of implantable coils is currently considered the best method due to improved control and delivery techniques.<sup>[14]</sup> Coil occlusion is primarily preferred in smaller fistulae and offers advantages of using a smaller sheath and catheter delivery size and a lower cost. Double umbrella devices are preferred for larger fistulae and allow a more precise positioning. The success rates of transcatheter closure vary from 83% to 91% and are comparable with surgical techniques. The risks of transcatheter coil occlusion are low. Complications such as transient ST-T changes, arrhythmia, coronary artery spasm, fistula dissection, coil embolization, and death may ensue. Mortality has been reported to be 0% to 2.2%.<sup>[14,15]</sup>

Patients with a large fistula, multiple openings, significant aneurysmal dilatation, or associated cardiac lesions may not be optimal candidates for transcatheter closure.<sup>[15]</sup> In these circumstances, surgical closure of the fistula is performed either by epicardial ligation or by endocardial patching of the orifice. However, surgery represents inherent risks of cardiopulmonary bypass and median sternotomy. Mortality related to surgical repair of fistulae ranges from 2% to 4%.<sup>[16]</sup> Variations that may contribute to surgical risks include the presence of a giant aneurysm or a fistula from the right coronary artery to the left ventricle.

In our patient, covered stent implantation was not preferred because of the proximity of the fistula to the large diagonal branch of the LAD artery and the absence of coronary artery disease. Treatment with coil embolization enabled a satisfactory result.

## REFERENCES

1. Levin DC, Fellows KE, Abrams HL. Hemodynamically significant primary anomalies of the coronary arteries. Angiographic aspects. *Circulation* 1978;58:25-34.
2. Gillebert C, Van Hoof R, Van de Werf F, Piessens J, De Geest H. Coronary artery fistulas in an adult population. *Eur Heart J* 1986;7:437-43.
3. Ito H, Kamiyama T, Nakamura W, Segawa K, Takahashi K, Iijima T, et al. Coronary artery-pulmonary artery fistula originating from three major coronary branches associated with exertional chest pain and tachycardia-dependent left bundle branch block. *Jpn Heart J* 1998;39:247-53.
4. Lin YH, Chao CL, Lee YT, Chen SJ, Wang SS. Coronary artery fistula presented as infective endocarditis with pulmonary septic emboli. *Int J Cardiol* 2005;98:159-60.
5. Habermann JN, Howard ML, Johnson ES. Rupture of the coronary sinus with hemopericardium. A rare complication of coronary arteriovenous fistula. *Circulation* 1963;28:1143-4.
6. Dichtl W, Waldenberger P, Pachinger O, Muller S. An uncommon coronary artery fistula causing survived sudden cardiac death in a young woman. *Int J Cardiovasc Imaging* 2005;21:387-90.
7. Angelini P. Normal and anomalous coronary arteries: definitions and classification. *Am Heart J* 1989;117:418-34.
8. Reidy JF, Sowton E, Ross DN. Transcatheter occlusion of coronary to bronchial anastomosis by detachable balloon combined with coronary angioplasty at same procedure. *Br Heart J* 1983;49:284-7.
9. Mavroudis C, Backer CL, Rocchini AP, Muster AJ, Gevitz M. Coronary artery fistulas in infants and chil-

- dren: a surgical review and discussion of coil embolization. *Ann Thorac Surg* 1997;63:1235-42.
10. Graeb DA, Morris DC, Ricci DR, Tyers GF. Balloon embolization of iatrogenic aortocoronary arteriovenous fistula. *Cathet Cardiovasc Diagn* 1990;20:58-62.
  11. Vajifdar BU, Gupta A, Lokhandwala YY, Kerkar PG, Limaye U, Ramakantan R. Transcatheter glue occlusion of bilateral coronary-pulmonary arterial fistulae. *Indian Heart J* 1999;51:209-11.
  12. Roongsritong C, Laothavorn P, Sa-nguanwong S. Stent grafting for coronary arteriovenous fistula with adjacent atherosclerotic plaque in a patient with myocardial infarction. *J Invasive Cardiol* 2000;12:283-5.
  13. Al-Ata J, Amin M, Galal MO, Kouatli A, Hussain A. Transcatheter occlusion of a large left coronary artery to right superior vena cava fistula using the Amplatzer duct occluder device. *Pediatr Cardiol* 2004;25:70-2.
  14. Qureshi SA, Tynan M. Catheter closure of coronary artery fistulas. *J Interv Cardiol* 2001;14:299-307.
  15. Armsby LR, Keane JF, Sherwood MC, Forbess JM, Perry SB, Lock JE. Management of coronary artery fistulae. Patient selection and results of transcatheter closure. *J Am Coll Cardiol* 2002;39:1026-32.
  16. Kirklin JW, Barratt-Boyes BG, editors. Congenital anomalies of the coronary arteries. In: *Cardiac surgery. Morphology, diagnostic criteria, natural history, techniques, results, and indications*. 3rd ed. New York: Churchill Livingstone; 2003. p.1240-64.