

Extraction of a Dual-Chamber Pacemaker and Subsequent Left Bundle Branch Area Pacing in a Young Patient

Genç Bir Hastada İki-Odacıklı Bir Pilin Ekstraksiyonu ve Akabinde Sol Dal Bölgesi Uyarımı

A 22-year-old female patient with congenital complete heart block and a dual-chamber pacemaker implanted in 2017 was referred to our department for electrode revisions due to recurrent presyncope attacks and dysfunction of both the right atrial (RA) and right ventricular (RV) electrodes, characterized by undersensing and capture failure of the atrial lead, as well as intermittent loss of ventricular capture from the RV lead (Figure 1). There was no history of electromagnetic interference, such as Magnetic Resonance Imaging (MRI), or magnet application for surgery. Transthoracic echocardiography at the time of implantation showed a left ventricular ejection fraction (LVEF) of 65% with otherwise normal cardiac structures. However, the current ejection fraction had decreased to 45%, indicating an apical pacing-induced reduction. Venography performed before the lead extraction procedure demonstrated occluded left subclavian and brachiocephalic veins. After failed attempts using simple and locking stylets (LLD®, Philips), a 13F rotating mechanical dilator sheath (TightRail™, Philips) was advanced over both the RV active-fixation and RA passive-fixation electrodes. Both electrodes were successfully extracted. Following the extraction of each electrode, a venous route through the occluded veins was established, and two standard guidewires were advanced through this route. Considering the pacing-induced decrease in left ventricular function, conduction system pacing was decided upon, and a 4.1F lumenless, active-fixation pacing lead (SelectSecure™ MRI SureScan™ Model 3830, Medtronic) was implanted in the area of the left bundle branch using a pre-shaped delivery catheter (Selectra 3D, Biotronik) (Video 1). In both unipolar and bipolar modes, good sensing (R wave > 10 mV) and pacing (capture threshold < 1 V @ 0.5 msec, impedance of 650 Ω) values were obtained. After the implantation of the standard atrial lead, a dual-chamber pulse generator was secured in the pocket. Repeatedly, good sensing and pacing parameters, along with the normalization of left ventricular function (LVEF of 60%), were observed at the 6-month follow-up (Figure 2).

Conventional RV apical pacing-induced cardiomyopathy (PICM) is a well-known phenomenon, especially in patients with a high percentage of pacing. By definition, a decrease in LVEF of $\geq 10\%$, resulting in an LVEF < 50% in a patient with RV apical pacing and without other causes of cardiomyopathy, is associated with PICM. A high RV apical pacing percentage and increased paced QRS duration (QRSd), indicating electrical dyssynchrony, are risk factors for PICM. Various echocardiographic tools and techniques, such as tissue Doppler imaging, strain analysis, and 3D echocardiography, can demonstrate mechanical dyssynchrony in RV apical pacing. In the current case, nearly 100% RV apical pacing load due to a very slow baseline heart rate of < 45 bpm over five years resulted in a 30% decrease in LVEF, resulting in an LVEF of 45%. The RV apical paced QRSd was also > 170 msec, which might indicate significant electrical dyssynchrony. Specific echocardiographic findings related to dyssynchrony were not available both at the time of implantation and during follow-up. Conduction system pacing, using either His-Bundle pacing or left bundle branch area pacing, shows superior performance from hemodynamic, electrical, and structural perspectives. When possible, conduction system pacing should be considered to pace the heart more physiologically to prevent, and in some conditions, reverse the deleterious effects of apical pacing.

CASE IMAGE OLGU GÖRÜNTÜSÜ

Serkan Çay ^{ID}
Özcan Özeke ^{ID}
Fırat Özcan ^{ID}
Meryem Kara ^{ID}
Elif Hande Özcan Çetin ^{ID}
Ahmet Korkmaz ^{ID}
Serkan Topaloğlu ^{ID}

Department of Cardiology, Division of Arrhythmia and Electrophysiology, University of Health Sciences, Yüksek İhtisas Cardiovascular Building, Ankara City Hospital, Ankara, Türkiye

Corresponding author:
Serkan Çay
✉ cayserkan@yahoo.com

Received: January 21, 2023
Accepted: March 19, 2023

Cite this article as: Çay S, Özeke Ö, Özcan F, et al. Extraction of a dual-chamber pacemaker and subsequent left bundle branch area pacing in a young patient. *Türk Kardiyol Dern Ars.* 2024;52(2):155-156.

DOI: 10.5543/tkda.2023.30497



Available online at archivestsc.com.
Content of this journal is licensed under a Creative Commons Attribution - NonCommercial-NoDerivatives 4.0 International License.

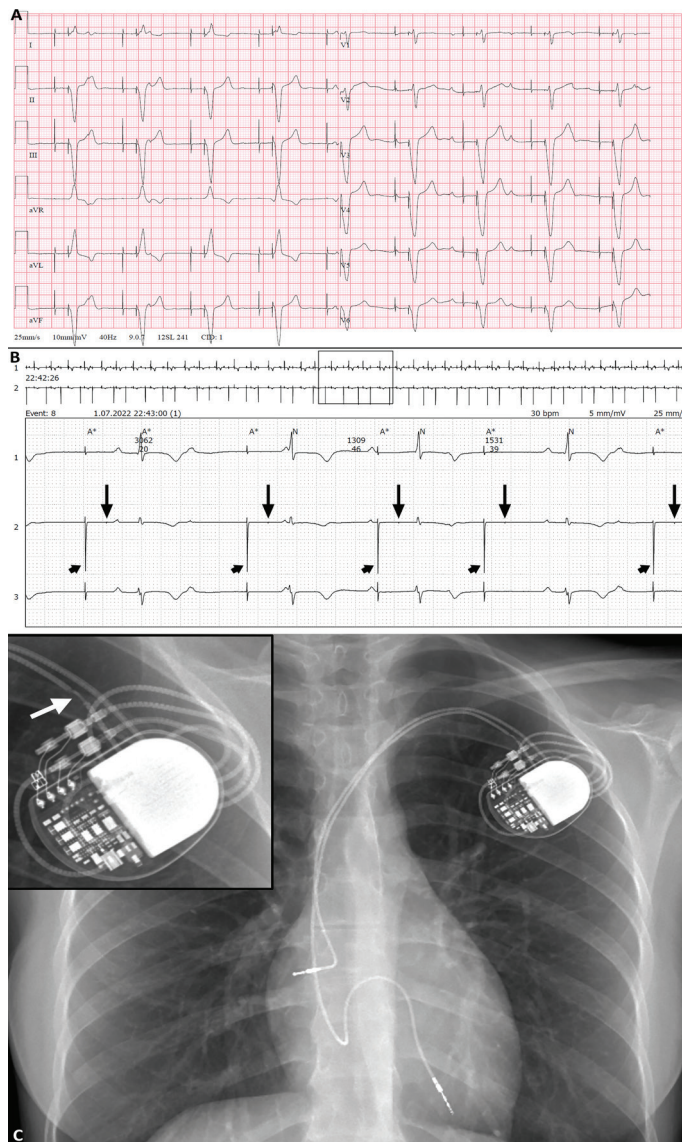


Figure 1. Preprocedural 12-lead surface electrocardiography showing complete heart block, RV apical pacing (QRSd: 176 msec) with atrial undersensing, and capture failure in the unipolar manner (A). A sample strip from the 24-hour Holter recording demonstrates complete heart block, RV capture failure (black arrows), and right atrial undersensing and capture failure (black arrowheads) (B). The programmed pacing mode was DDD with timing intervals including LRI of 1,100 msec, paced AVI of 220 msec, and AEI of 880 msec. No grossly visible fusion or pseudofusion beats are present, and some ventricular complexes are distorted by overlapped dissociated P waves due to both undersensing and capture not output failure of the atrial lead. In addition, intermittent loss of RV capture (at 5 V @ 1 msec) (black arrows) with normal sensing function of the RV lead results in resetting of the LRI. If a sensing ventricular event does not occur during the VRP, it resets the LRI, and after AEI, an atrial pacing spike causing noncapture (black arrowheads) is seen. The posteroanterior chest X-ray shows the dual-chamber pacemaker with an RA electrode and an RV apical electrode. The inset picture shows gross failure (lead fracture with accompanying possible insulation break) (white arrow) through the atrial lead in the pacemaker pocket (C). Although no apparent pathophysiologic mechanism could be proposed to explain the underlying cause(s) of capture failure in the RV lead, lead maturation due to late fibrosis, micro-dislodgement, and microfracture/insulation break due to chronic mechanical lead injury might be considered. AEI, atrial escape interval; AVI, atrioventricular interval; LRI, lower rate interval; QRSd, QRS duration; RA, right atrial; RV, right ventricular; VRP, ventricular refractory period.

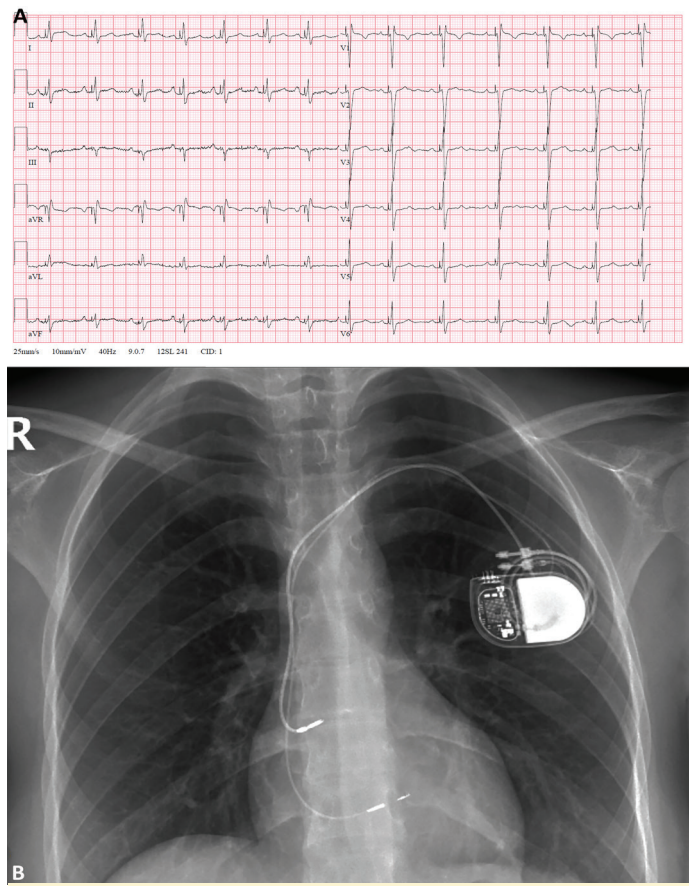


Figure 2. Postprocedural 12-lead surface electrocardiography showing atrial-sensed left bundle branch area pacing (QRSd: 120 msec) morphology with an R-wave peak time of 60 msec (A). The posteroanterior chest X-ray shows the dual-chamber pacemaker with an RA electrode and a ventricular septal electrode in the appendage and upper septum, respectively (B). QRSd, QRS duration; RA, right atrial.

Informed Consent: Informed consent was obtained from the patient for the publication of the case image and accompanying images.

Peer-review: Internally peer-reviewed.

Author Contributions: Concept – S.Ç.; Design – S.Ç.; Supervision – S.Ç.; Materials – S.Ç.; Data Collection and/or Processing – S.Ç.; Writing – S.Ç.; Critical Review – Ö.Ö., F.Ö., M.K., H.Ç., A.K., S.T.

Conflict of Interests: No conflict of interest disclosure has been received from the authors.

Funding: The authors declared that this study received no financial support.

Video 1. Procedural steps from the extraction of both electrodes to the implantation of new electrodes. Contrast injection through the delivery sheath illustrates the depth of the ventricular electrode in the septum. An extra safety guidewire was positioned in the superior vena cava during the extraction procedure.

LBBAP, left bundle branch area pacing.