

Radiofrequency Catheter Ablation of Orthodromic Reentrant Tachycardia Detected by Smartwatch: Beginning of a New Era?

Akıllı Saat ile Tespit Edilen Ortodromik Reentrant Taşikardinin Radyofrekans Kateter Ablasyonu: Yeni bir Dönemin Başlangıcında mıyız?

A 32-year-old male patient presented to our clinic with episodes of palpitations. In one of those episodes, his smart watch (Apple Watch Series 4, Apple, Cali, USA) recorded tachycardia with a heart rate of 167/beats per minute (Figure 1). He had prior referrals to the emergency department with palpitation, but no documented tachycardia episodes were detected after serial electrocardiography (ECG) recordings and Holter monitoring. In his smart watch-detected tachycardia, narrow complex tachycardia with a short RP interval was observed (Figure 1).

He was recommended to undergo an electrophysiological study. During incremental pacing, narrow complex tachycardia with a ventricular cycle length of 390 milliseconds was induced (Figure 2A). There was concentric activation in coronary sinus with V-A interval measured as 93 milliseconds. Para-Hisian pacing maneuver revealed no change in stimulus to A interval (Figure 2B). His-refractory ventricular stimuli advanced to the next atrial signal with the same atrial activation pattern. On the basis of these findings, orthodromic reentrant tachycardia using a septal concealed accessory pathway was suspected as the diagnosis. We mapped the earliest retrograde A by using a 3-dimensional mapping system (EnSite Precision Cardiac Mapping System, Abbott, Ill, USA) during ventricular pacing. The earliest A signal was recorded at the left posteroseptal region (Figure 2C) and ablation of this side resulted in changing the earliest retrograde A activation to His region. Tachycardia was noninducible after ablation.

Smart watches that are capable of recording ECG may be a good option in patients with palpitations suggestive of tachycardia in whom traditional rhythm monitoring devices fail to identify episode.

Informed consent was obtained from the patient for the publication of the case image and the accompanying images.

CASE IMAGE OLGU GÖRÜNTÜSÜ

Göksel Çinier, M.D. 

Mert Hayiroğlu, M.D. 

İlker Tekkesin, M.D. 

Kadir Gürkan, M.D. 

Department of Cardiology, Dr Siyami Ersek Thoracic and Cardiovascular Surgery Training and Research Hospital, İstanbul, Turkey

Corresponding author:

Göksel Çinier
✉ cinierg@gmail.com

Received: January 3, 2021

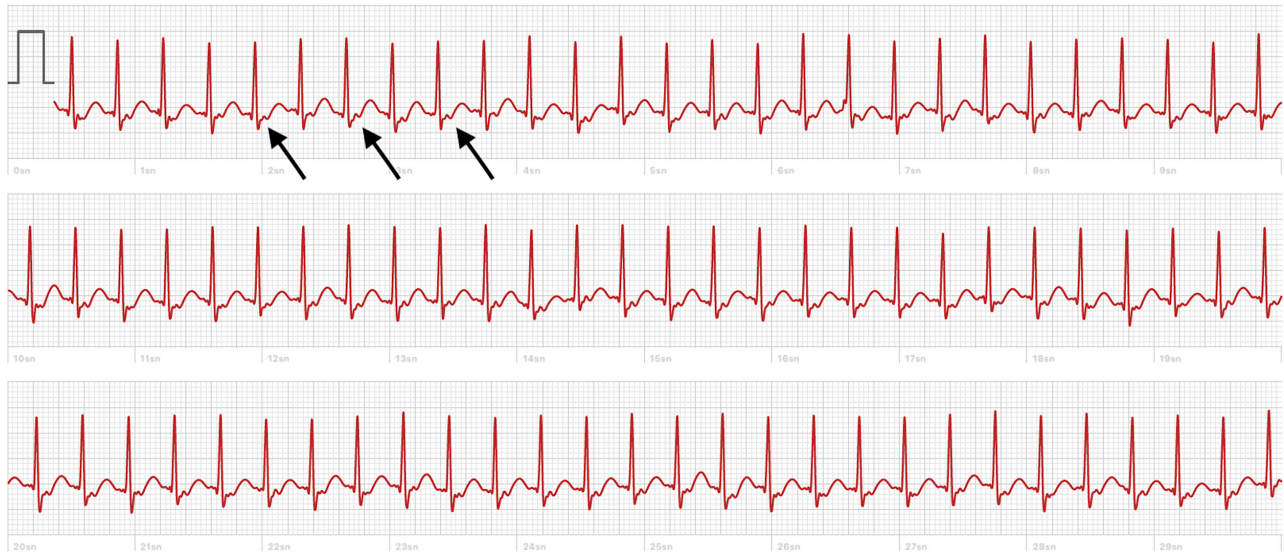Accepted: February 22, 2022

Cite this article as: Çinier G, Hayiroğlu M, Tekkesin İ, Gürkan K. Radiofrequency catheter ablation of orthodromic reentrant tachycardia detected by smartwatch: beginning of a new era? Turk Kardiyol Dern Ars 2022;50(2):159-160.

DOI:10.5543/tkda.2022.95007



Available online at archivestsc.com.
Content of this journal is licensed under a Creative Commons Attribution - NonCommercial-NoDerivatives 4.0 International License.



25 mm/sn, 10 mm/mV, Derivasyon I, 512 Hz, iOS 14.2, watchOS 7.1, Watch6,1 – Bu dalga formu Derivasyon I EKG'ye benzerdir. Daha fazla bilgi için Kullanma Yönergeleri'ne bakın.

Figure 1. Tachycardia episode detected by the smart watch. Retrograde P waves (black arrows) can be observed.

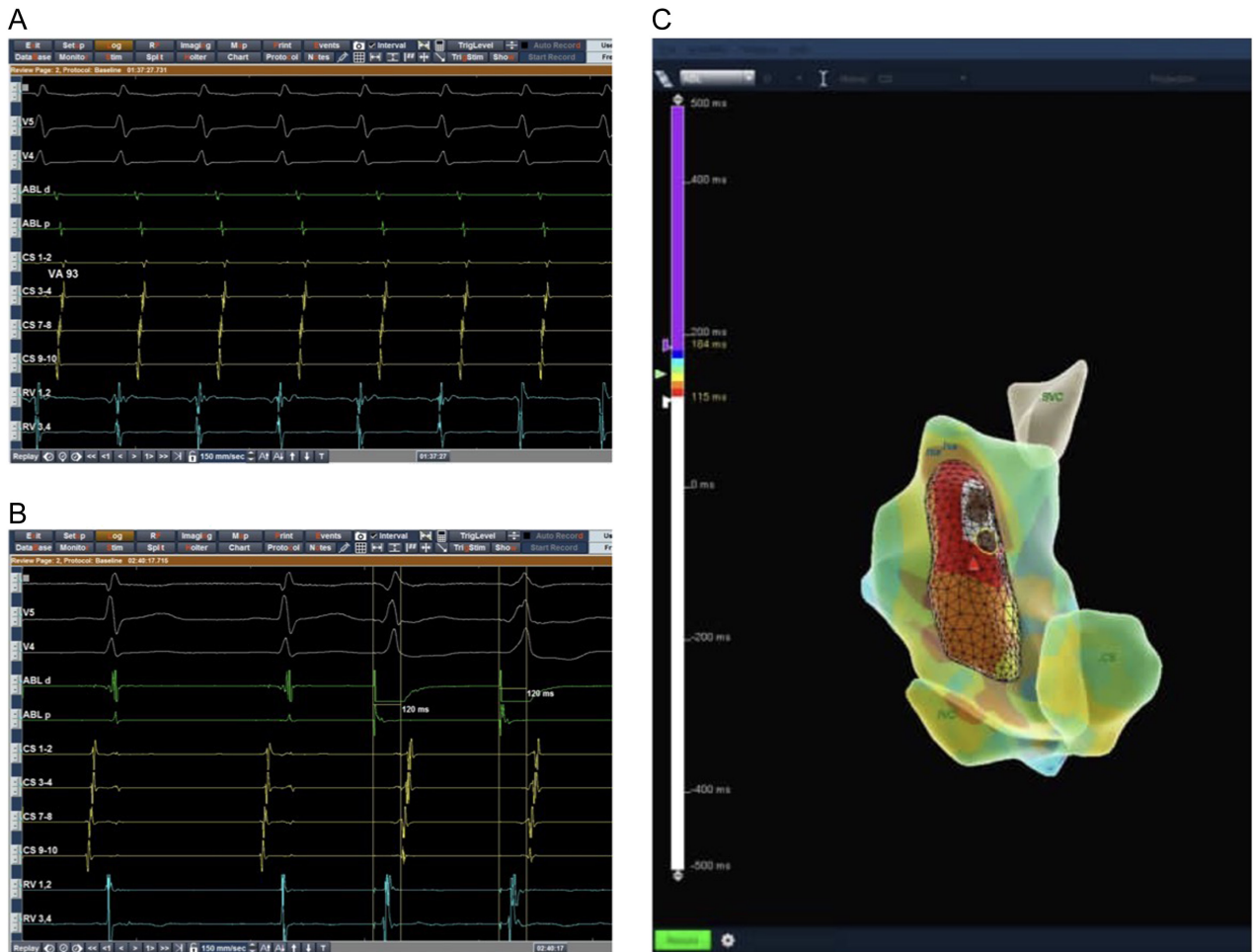


Figure 2. (A) Electrograms showing tachycardia with a cycle length of 390 milliseconds. The measured V-A interval is 93 milliseconds. CS 1,2 is the most distal and CS9,10 is the most proximal. Note the concentric retrograde atrial activation. RV catheter is located in the RV apex. (B) Para-Hisian pacing maneuver resulted in no change in V-A duration and retrograde activation sequence. (C) Three-dimensional mapping image of successful ablation site. CS, coronary sinus; RV, right ventricle.