

An asymptomatic patient with a pellet within the myocardium

Asemptomatik bir hastada miyokart içinde saçma tanesi

Fethi Kılıçaslan, M.D., Mustafa Aparcı, M.D., Ömer Uz, M.D., Ersin Öztürk, M.D.#

Departments of Cardiology and #Radiology, Haydarpaşa Training Hospital, Gülhane Military Medical School, İstanbul

Summary – Penetrating injuries to the myocardium are rare but potentially lethal. We present a 22-year-old asymptomatic male patient with a pellet lodged in the myocardium as a result of a gunshot that took place three years before. His medical history was otherwise unremarkable. The chest X-ray showed multiple pellets within the thorax. Computed tomography of the chest demonstrated many pellets in the anterior chest wall, while a few lodging within the lung tissue and one within the myocardium. Transthoracic echocardiography showed a pellet within the left ventricular myocardium presenting as an acoustic shadowing. Thickening of the adjacent pericardium was also noted. There were no signs of constrictive pericarditis or regional wall motion abnormality. Holter monitoring and treadmill exercise test did not show any abnormal finding. The patient was included in a periodic follow-up program.

Özet – Miyokartta delici yaralanmalar nadirdir fakat ölümcül olabilir. Bu yazıda, üç yıl önceki ateşli silah yaralanması sonucu miyokardına saçma tanesi saplanan asemptomatik 22 yaşında bir erkek hasta sunuldu. Hastanın özgeçmişinde dikkat çekici başka nokta yoktu. Akciğer filminde göğüs içinde çok sayıda saçma tanesi izlendi. Akciğer bilgisayarlı tomografisinde göğsün ön duvarında belirgin sayıda, akciğer dokusunda bir kaç tane ve miyokart içinde bir tane saçma tanesi görüldü. Transtorasik ekokardiyografide sol ventrikül miyokardı içindeki saçma tanesi akustik gölgelenme şeklinde izlendi; beraberinde komşu perikartta kalınlaşma da dikkat çekiciydi. Konstriktif perikardit bulgusuna veya bölgesel duvar hareket bozukluğuna rastlanmadı. Holter izleminde ve egzersiz testinde de anormal bulgu yoktu. Hasta düzenli takip programına alındı.

CASE REPORT

Myocardial injury due to a penetrating gunshot wound is a potentially lethal clinical condition.^[1] Patients usually present with acute hemodynamic decompensation due to myocardial injury and/or cardiac tamponade.^[2] Treatment of these patients often requires emergency surgery.^[2] In less severe conditions, patients may present with dyspnea, chest pain, hemoptysis, or arrhythmia.^[1] If there is no sign of cardiac tamponade and clinical deterioration, conservative treatment may be followed.^[1,2]

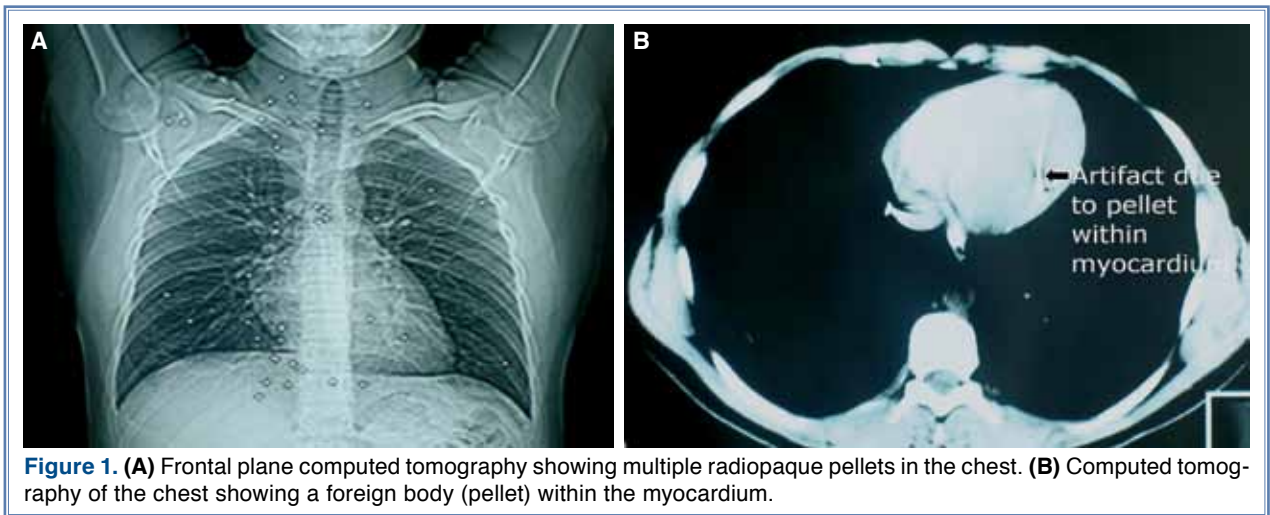
In this case report, we present a patient with a three-year history of accidental gunshot wound. Despite the presence of many pellets in the thorax (several of them were within the lungs and one was within the myocardium), he was totally asymptomatic without any symptom of cardiac or pulmonary dysfunction.

A 22-year-old male was referred to our department for further evaluation following a health screening. He had no cardiac or pulmonary symptoms. His medical history was remarkable for an accidental gunshot injury to his anterior chest three years before. He was shot from a distance of approximately 15 meters and had multiple wounds over his upper body. Then, he was evaluated at the emergency service in a rural hospital and was decided to be treated conservatively without any surgical intervention, after which he had no complaints of arrhythmia, presyncope, syncope, angina, systemic embolism, or heart failure. Physical examination showed multiple sites of discoloration on the anterior chest wall. His blood pressure and pulse rate were 130/80 mmHg

Received: October 5, 2011 Accepted: December 12, 2011

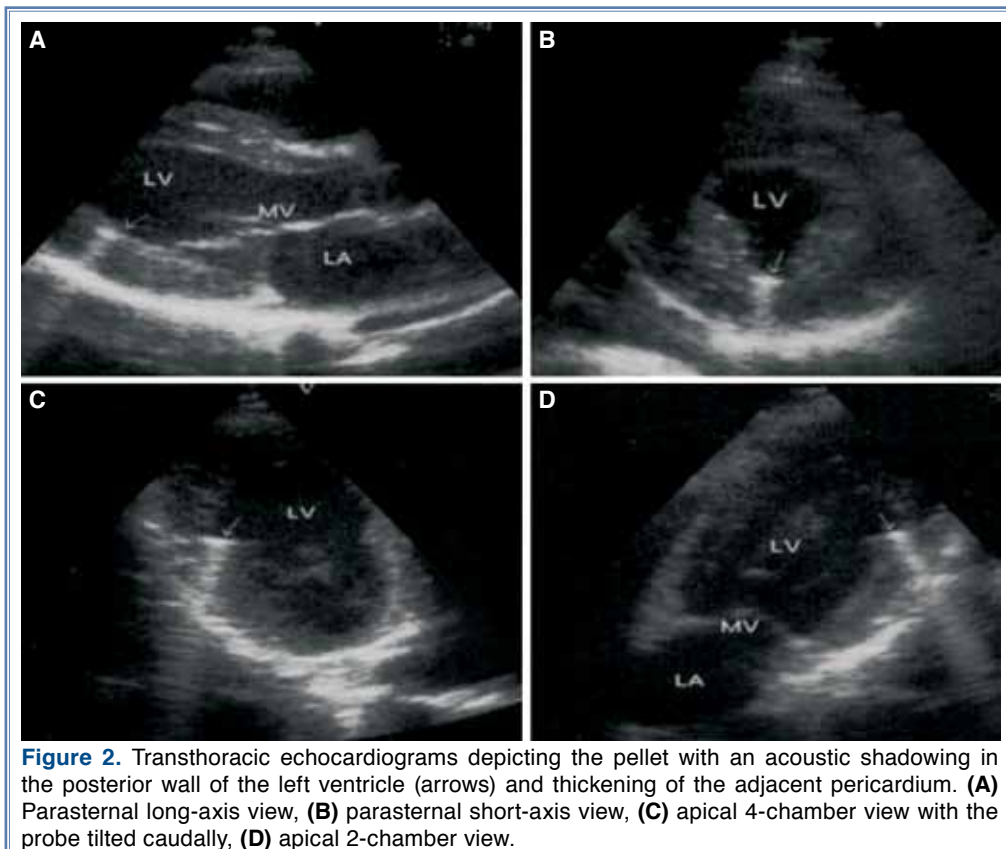
Correspondence: Dr. Ömer Uz, GATA Haydarpaşa Eğitim Hastanesi, Kardiyoloji Servisi, 34668 Kadıköy, İstanbul, Turkey.
Tel: +90 216 - 542 20 20 / 3185 e-mail: homeruz@yahoo.com

© 2012 Turkish Society of Cardiology



and 80 bpm, respectively. The electrocardiogram was within normal limits with sinus rhythm. Multiple radiopaque materials (pellets) were seen on the chest X-ray. Computed tomography of the chest showed many pellets located at the anterior chest wall while a few lodged within the lung tissue, and one within the myocardium (Fig. 1). On transthoracic echocardiography, the heart appeared structurally normal with an ejection

fraction of 60%. The pellet was seen as an echo contrast material with an acoustic shadowing within the posterior part of the left ventricular myocardium (Fig. 2). Thickening (6 mm) of the adjacent pericardium was noted. However, there were no signs of constrictive pericarditis or regional wall motion abnormality. Holter monitoring and treadmill exercise test did not show any abnormal finding.



DISCUSSION

Foreign bodies within the heart are commonly encountered following either penetrating traumas or gunshots to the chest wall. Metal objects such as bullets and needles and rarely, nonmetal objects such as catheter fragments, pencils and glass pieces may be found within the heart.^[1-3] Depending on the entry site and the type of the wound, foreign bodies may be of intrapericardial, intramyocardial or endocavitary (atrium, ventricle or vessels) locations. Actis Dato et al.^[1] reported 14 patients with foreign bodies in the heart, which included bullets (in the right or left ventricle), needles (in the left ventricle, atrium, pulmonary artery), retained catheter fragments (in the right ventricle), a metallic explosive fragment (in the right atrium), and a commissurotomy ring (in the left atrium).

Patients sustaining penetrating trauma or gunshot to the chest should be carefully evaluated for lethal complications such as cardiac tamponade, pneumothorax, and hemorrhagic shock. Even though the patient may be hemodynamically stable without any signs of these complications, chest X-ray, transthoracic echocardiography, and computed tomography of the thorax should be obtained. Among them, echocardiographic examination is the most important method for diagnosing foreign bodies in the heart.^[4] In our case, although the pellets were initially recognized on the X-ray, we could define their location only by echocardiographic and tomographic examinations.

Foreign bodies in the heart should be removed urgently in case of any life-threatening complications and if there is risk for embolism, arrhythmia, or infection.^[2] Extraction is often performed via a median sternotomy with or without cardiopulmonary bypass.^[5] Percutaneous catheter-guided techniques for removal of foreign bodies from the heart were also reported.^[6] The penetrating material should be removed in the operating room due to risk for excessive bleeding and pericardial tamponade necessitating an urgent surgery.^[2] Asymptomatic patients without any risk for embolism, arrhythmia or infection may be treated conservatively, especially if the removal surgery is a high-risk operation.^[1] The major risk of nonoperative or conservative management is the development of cardiac neurosis, embolization, thrombosis, or subacute bacterial endocarditis.^[5] Another potential concern is the risk for local inflammatory reaction. Like intracoronary stents, foreign bodies in the myocardium may cause inflammatory reaction.^[7,8]

Seipelt et al.^[8] reported a male who developed coronary artery disease 44 years after a gunshot injury that remained two missiles, one adjacent to the right coronary artery and the other to the left anterior descending coronary artery. The authors implicated the inflammatory reaction caused by the bullets for triggering coronary artery disease. Medical record of our patient following the accidental gunshot was not available to explain why he had been treated conservatively. Most probably, he was free of any lethal complication. Our laboratory tests showed no organ dysfunction. The only sequela other than the pellets themselves was focal thickening of the adjacent pericardium that did not cause constriction. Thus, no specific treatment was advised except for periodic controls on a yearly basis. Fortunately, the patient did not have any complication related to the gunshot wound and the pellets.

Conflict-of-interest issues regarding the authorship or article: None declared

REFERENCES

1. Actis Dato GM, Arslanian A, Di Marzio P, Filosso PL, Ruffini E. Posttraumatic and iatrogenic foreign bodies in the heart: report of fourteen cases and review of the literature. *J Thorac Cardiovasc Surg* 2003;126:408-14.
2. De Raet J, Mees U, Vandekerckhof J, Hendrikx M. Penetrating pediatric cardiac trauma caused by fall on a pencil with normal echocardiography. *Interact Cardiovasc Thorac Surg* 2004;3:634-6.
3. Yang X, Shen X. A piece of glass in the heart. *Ann Thorac Surg* 2006;81:335-6.
4. Jimenez E, Martin M, Krukenkamp I, Barrett J. Subxiphoid pericardiotomy versus echocardiography: a prospective evaluation of the diagnosis of occult penetrating cardiac injury. *Surgery* 1990;108:676-9.
5. Barrett NR. Foreign bodies in the cardiovascular system. *Br J Surg* 1950;37:416-45.
6. Kaushik VS, Mandal AK. Non-surgical retrieval of a bullet embolus from the right heart. *Catheter Cardiovasc Interv* 1999;47:55-7.
7. Gomes WJ, Giannotti-Filho O, Paez RP, Hossne NA Jr, Catani R, Buffolo E. Coronary artery and myocardial inflammatory reaction induced by intracoronary stent. *Ann Thorac Surg* 2003;76:1528-32.
8. Seipelt RG, Vazquez-Jimenez JF, Messmer BJ. Missiles in the heart causing coronary artery disease 44 years after injury. *Ann Thorac Surg* 2000;70:979-80.

Key words: Foreign bodies; heart injuries/etiology.

Anahtar sözcükler: Yabancı cisim; kalp yaralanması/etiyojisi.