

A Breathtaking Case of Pulmonary Hypertension with Frightening Complications and Intertwining Different Etiologies

Korkutucu Komplikasyonları ve Karmaşık Etiyolojileri ile Nefes Kesen Bir Pulmoner Hipertansiyon Vakası

ABSTRACT

Pulmonary hypertension (PH) is a major health problem with increasing awareness. Although most common cause of PH is left heart disease (Group 2 PH), life-threatening complications occur mostly in Group 1 (pulmonary arterial hypertension) and Group 4 (chronic thromboembolic PH) patients. Although external compression of the left main coronary artery (LMCA) due to pulmonary artery dilatation is rare, it is a life-threatening complication since it causes myocardial ischemia and sudden cardiac death. In addition, PH is more than a single clinical entity due to its complex mechanism in which more than one subgroup may develop over time in the same patient. This complex mechanism challenges us when diagnosing the patient and faces us with life-threatening complications. In this case; we report a pulmonary arterial hypertension patient applied to our clinic with progressive dyspnea and recent angina, after detection of LMCA ostial stenosis, the patient was treated with intravascular ultrasound-guided stent implantation. In the further follow-ups, the patient underwent the pulmonary endarterectomy operation due to the diagnosis of chronic thromboembolic pulmonary hypertension secondary to newly diagnosed primary antiphospholipid syndrome.

Keywords: Chronic thromboembolic pulmonary hypertension, percutaneous coronary interventions, pulmonary endarterectomy, pulmonary hypertension

ÖZET

Pulmoner hipertansiyon (PH) giderek farkındalığı artan önemli bir sağlık sorunudur. PH'nin en sık nedeni sol kalp hastalığı (Grup 2 PH) olmasına rağmen, yaşamı tehdit eden komplikasyonlar sıklıkla Grup 1 (pulmoner arteriyel hipertansiyon) ve Grup 4 (kronik tromboembolik pulmoner hipertansiyon) olan hastalarda görülmektedir. Ancak pulmoner arter dilatasyonuna bağlı gelişen sol ana koroner arterin (LMCA) eksternal basıya uğraması, nadir olmakla birlikte miyokardiyal iskemiye ve ani kardiyak ölüme yol açması nedeniyle hayatı tehdit eden bir komplikasyondur. Ayrıca PH tek bir klinik antiteden daha fazlası olup, aynı hastada zaman içinde birden fazla alt grubun gelişebileceği karmaşık bir mekanizmaya sahiptir. Bu karmaşık mekanizma, hastaya teşhis koyarken bizleri zorlarken ve hayatı tehdit eden komplikasyonlarla da karşı karşıya getirmektedir. Bu vakada; kliniğimize progresif nefes darlığı ve son zamanlarda artan anjina şikayeti ile başvuran, LMCA ostial stenozu saptandıktan sonra IVUS eşliğinde stent implantasyonu ile başarılı bir şekilde tedavi edilen bir pulmoner arteriyel hipertansiyon hastasını sunmaktayız. İlerleyen takiplerinde hastaya, yeni tanı primer antifosfolipid sendromuna sekonder gelişen kronik tromboembolik pulmoner hipertansiyon nedeniyle pulmoner endarterektomi operasyonu uygulanmıştır.

Anahtar Kelimeler: Kronik tromboembolik pulmoner hipertansiyon, perkütan koroner girişimler, pulmoner endarterektomi, pulmoner hipertansiyon

Pulmonary arterial hypertension (PAH) is still an important cause of mortality and morbidity, despite all progress in diagnosis and treatment.¹ Patients may present with variety of symptoms that can mimic other cardiovascular or respiratory system diseases. Among these symptoms, the presence of angina is quite important. The most common pathophysiological mechanism of angina in PAH patients is oxygen supply-demand mismatch due to the right ventricular hypertrophy and low-cardiac output. However, compression of the left main coronary artery (LMCA) by dilated pulmonary artery may cause angina and should be considered in the differential diagnosis.


CASE REPORT OLGU SUNUMU

Hidayet Ozan Arabacı¹ 

Aybike Gül Taşdelen¹ 

İdil Buğday¹ 

Attıla Ülkücü² 

Ümit Yaşar Sinan¹ 

Bedrettin Yıldızeli³ 

Mehmet Serdar Küçüköğlü¹ 

¹Department of Cardiology, Istanbul University-Cerrahpaşa Institute of Cardiology, Istanbul, Türkiye

²Department of Emergency, Yedikule Chest Diseases and Thoracic Surgery Training and Research Hospital, Istanbul, Türkiye

³Department of Thoracic Surgery, Marmara University, Faculty of Medicine, Istanbul, Türkiye

Corresponding author:

Hidayet Ozan Arabacı

✉ drhidayetozanarabaci@gmail.com

Received: March 30, 2023

Accepted: July 3, 2023

Cite this article as: Arabacı HO, Taşdelen AG, Buğday İ, et al. A breathtaking case of pulmonary hypertension with frightening complications and intertwining different etiologies. *Türk Kardiyol Dern Ars.* 2023;51(7):488-492.

DOI:10.5543/tkda.2023.22477



Available online at archivestsc.com.
Content of this journal is licensed under a Creative Commons Attribution - NonCommercial-NoDerivatives 4.0 International License.

Chronic thromboembolic pulmonary hypertension (CTEPH) is a complex cause of PH that can be the sole cause of pulmonary hypertension (PH), or it can be added to the causes of other PH subgroups.¹ It should be kept in mind, especially in cases of sudden worsening PH. Antiphospholipid antibody syndrome (AFAS) is an important cause of thromboembolism that should be investigated in every patient evaluated with the diagnosis of CTEPH.¹

Here, we present a PAH patient with LMCA compression syndrome treated with intravascular ultrasound (IVUS)-guided percutaneous coronary interventions (PCI). During the follow-ups, the patient underwent the pulmonary endarterectomy operation due to the diagnosis of CTEPH secondary to newly diagnosed primary antiphospholipid syndrome (APS). To the best of our knowledge, this is the youngest PAH patient who has LMCA compression syndrome, treated with PCI in the literature.

Case Report

A 23-year-old female patient with idiopathic PAH (the patient has been followed in our clinic for 6 years with a diagnosis of

idiopathic PAH) was admitted to our emergency department with complaints of progressive dyspnea, chest pain, and fatigue for the past 3-4 days. She was on triple combination therapy with ambrisentan 10 mg once daily (o.d.), tadalafil 40 mg o.d., and selexipag 1000 mg twice daily (b.i.d.). The electrocardiogram revealed sinus tachycardia, right axis deviation, and right ventricle strain (ST segment depression and negative T wave on V1-V4 derivation). On physical examination, the blood pressure was 92 mmHg for systolic and 57 mmHg for diastolic, and systemic oxygen saturation was 88%. The patient was hospitalized due to clinical worsening of the PH. There was mild troponin (TnI:0.019 ng/mL) and significant natriuretic peptide (NT-proBNP:9465 pg/mL) increase. On transthoracic echocardiography, enlargement of the right heart chambers, RV hypertrophy, septal flattening (D-sign), increased systolic pulmonary artery pressure (sPAP:110 mmHg), and mild RV dysfunction (TAPSE: 18 mm, S': 14 cm per second) were detected (Video 1).

The patient's functional capacity was WHO FC III and 6-min walking diameter was 238 m. Since the patient had intermediate-high risk according to the 4-strata follow-up risk score, a right heart catheterization and coronary angiography were decided to perform before treatment escalation. On coronary angiography, slit-like lesion causing 90% of stenosis on LMCA ostium was observed (Figure 1 and Video 2). In addition, dense vascular collaterals extending from the left anterior descending artery (LAD) and right coronary artery proximal to the distal pulmonary arteries were detected in CA. On hemodynamic evaluation, mean pulmonary arterial pressure (mPAP) was 85 mmHg, the pulmonary vascular resistance (PVR) was 38.9 Wood Unit (WU), left ventricular (LV) end-diastolic pressure was 8 mmHg, right atrial pressure was 24 mmHg, and cardiac index was 1.2 liter per minute per meter square (Table 1). Since the patients had high risk according to clinical and hemodynamic risk parameters, treatment escalation with switch from oral prostanoid (selexipag) to parenteral prostanoid (intravenous epoprostenol) was planned. Before the initiation of iv. epoprostenol, we first decided to treat ostial LMCA stenosis

ABBREVIATIONS

6MWD	6-minute walk distance
AFAS	Antiphospholipid antibody syndrome
ANA	Antinuclear Antibody
Ao	Aorta
aPL	Antiphospholipid antibodies
Bid	Twice a day
CA	Coronary angiography
CCP	Cyclic Citrullinated Peptide
CCTA	Coronary computed tomography angiography
CI	Cardiac index
CT	Computed tomography
CTEPH	Chronic thromboembolic pulmonary hypertension
DNA	Deoxyribonucleic acid
EBU	Extra back-up
ECG	Electrocardiogram
Fr	French
IPAH	Idiopathic pulmonary arterial hypertension
IVIG	Intravenous immunoglobulin
IVUS	Intravascular ultrasound
LAD	Left anterior descending artery
LMCA	Left main coronary artery
LPA	Left pulmonary artery
LV	Left ventricle
LVEDP	Left ventricular end-diastolic pressure
MPA	Main pulmonary artery
mPAP	Mean pulmonary arterial pressure
Od	Once a day
PA	Pulmonary artery
PAH	Pulmonary arterial hypertension
PCI	Percutaneous coronary interventions
PH	Pulmonary hypertension
PLT	Platelet
PVR	Pulmonary vascular resistance
RAP	Right atrial pressure
RCA	Right coronary artery
RHC	Right heart catheterization
RPA	Right pulmonary artery
RV	Right ventricle
RV	Right Ventricle
SCD	Sudden cardiac death
SLE	Systemic lupus erythematosus
sPAP	Systolic pulmonary arterial pressure
TAPSE	Tricuspid annular plane systolic excursion
WHO FC	World Health Organization Functional Capacity

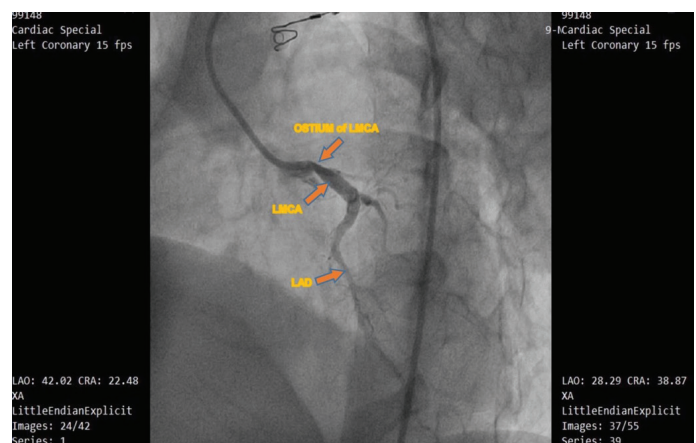


Figure 1. Coronary angiography is showing LMCA ostial stenosis caused by compression of LMCA by enlarged PA. (LMCA: left main coronary artery, LAD: left anterior descending artery, PA: pulmonary artery) (Orange Arrows: Top arrow shows ostium of LMCA, middle and below arrows show coronary vessels).

Table 1. Findings of the Right Heart Catheterization

Definition	Phase (mmHg)	Mean (mmHg)	SatO ₂
AORT	90/65	73	92.6
LV	90/0-8		93.2
LVEDP		8	
PA	140/50	85	49.8
RV	140/0-15		57.7
RA		14	51.4
VCS			48.2
CO = 2.0 l/min	PO = 2.0 l/min	CI = 1.2/min/m²	Stroke Volume Index = 12.5 ml/min/m²
SWR = 29.5 WU	PWR = 38.9 WU	Heart Rate = 96 bpm	

CI, cardiac index; CO, cardiac output; LV, left ventricle; LVEDP, left ventricle end-diastolic pressure; RA, right atrium; RV, right ventricle; PO, pulmonary output; PWR, Pulmonary vascular resistance; SO, systemic output; SWR, systemic vascular resistance; VCS, vena cava superior.

with PCI, because the patient was describing persistent chest pain even at rest, conforming to Class 4 angina. To evaluate LMCA and PA intercourse and take-off angle of LMCA, coronary computed tomography angiography was performed. In the computed tomography (CT) angiography, the diameter of the pulmonary artery was measured as 47 mm, and as a result of the examinations in the coronal sections, compression of the dilated pulmonary artery to the ostial region of the LMCA was observed and the take-off angle of LMCA was determined as 19.8° (Figure 2a and b). Before PCI, oral 600 mg clopidogrel and 300 mg of acetylsalicylic acid were loaded. A 7Fr L 3.5 EBU catheter was inserted into the LMCA. A 0.014-inch guidewire was advanced from the LMCA to the distal LAD. Afterward, evaluation with IVUS showed no intimal hyperplasia or plaque formation, and there was dynamic ostial stenosis of LMCA during systole due to enlarged PA compression. After a dilatation with a 3.0*10 mm semi-compliant balloon, 4.0*12 mm Resolute Onyx (Medtronic, CA) DES was implanted to LMCA (Video 3). Finally, post-dilatation with 5.0*8 mm Apollo NC balloon (BrosMed Medical, PRC) was used for post-dilatation. Final IVUS imaging showed well-positioned stent struts on LMCA. After PCI, the patient was taken to the coronary intensive care unit and evaluated for treatment escalation and possible diagnosis of CTEPH. Due to the very high pulmonary vascular resistance (PVR), the presence of dense collaterals extending from the coronary arteries to the pulmonary arteries, and the acute worsening of the patient, it was thought, the patient might develop CTEPH on the diagnosis of idiopathic PAH. The patient's thorax CT, which was taken in 2016, was re-evaluated, and CT pulmonary angiography was planned again since there were no findings in favor of CTEPH. According to the CT result, main pulmonary artery (MPA): 47 mm, right pulmonary artery: 32 mm, left pulmonary artery: 31 mm was measured; on observing concentric, web-shaped filling defects (these defects were evaluated as compatible with CTEPH.) in the distal right MPA and proximal lower lobar branches and proximal left lower lobe segmental branch, enoxaparin 0.6 bid was given to the patient with the diagnosis of CTEPH. The treatment of the right heart failure was optimized. On the 4th day of the follow-up, the patient was planned to be evaluated by hematology, due

to the PLT number decreased below 100,000/mm³. As a result of the evaluations, the platelet count of 40,000/mm³ was detected in the peripheral smear, and enoxaparin treatment was discontinued. After the diagnosis of CTEPH, comprehensive

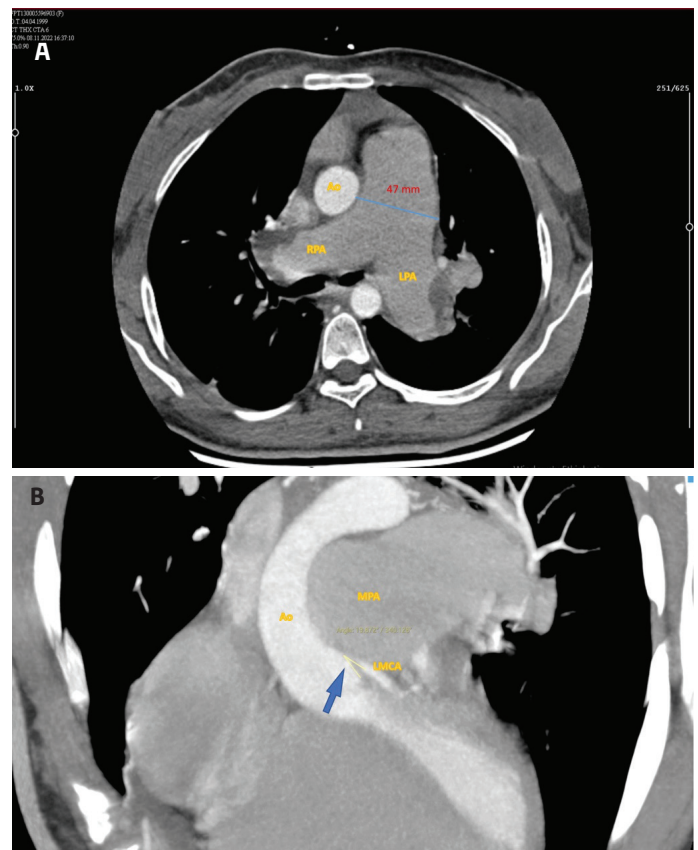


Figure 2. (A) A CT shows aneurysmatic dilatation of the main and left/right pulmonary artery. Diameter of enlarged main pulmonary artery measured 47 mm. (B) A CT shows inferiorly displaced LMCA due to an enlarged pulmonary artery and measured LMCA take off-angle 19.8° (blue arrow) (Ao: Aort, RPA: right pulmonary artery, LPA: left pulmonary artery, MPA: main pulmonary artery, LMCA: left main coronary artery).

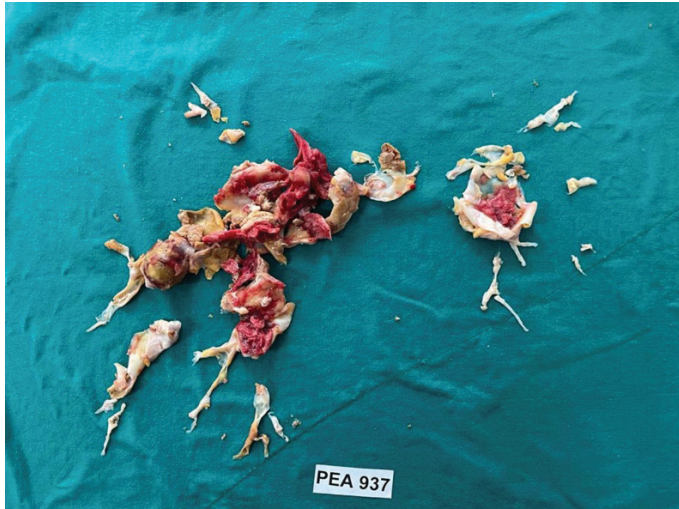

Figure 3. Pulmonary endarterectomy specimen.

rheumatological and hematological blood parameters were requested to investigate the underlying etiological cause. The diagnosis of primary APS was made on the detection of antinuclear Antibody (+), anti-cardiolipin (+), anti-ds-DNA (-), lupus anticoagulant (-), C3(-), C4(-), and anti-Cyclic Citrullinated Peptide (-). Enoxaparin was replaced with warfarin 5 mg. As the thrombocytopenia deepened, first dexamethasone administration, then IVIG treatment was planned, and decided to add rituximab to the treatment if necessary. During the intensive care follow-ups, CTEPH developing secondary to primary AFAS on idiopathic pulmonary arterial hypertension (IPAH) was confirmed, on the evaluation of pulmonary arterial tree, stenosis at mid-proximal levels as suitable for surgical treatment; it was decided to plan the pulmonary endarterectomy procedure. Pulmonary endarterectomy was performed on the patient by the thoracic surgery department. The operation was started with median sternotomy, cardiopulmonary bypass was provided after aortic and bicaval cannulation. The patient was cooled down to 20°C, deep hypothermia was initiated, and then right and left pulmonary arteriotomy was performed, and total circulatory arrest was initiated. Endarterectomy was performed successfully from proximal to distal, and the procedure was completed, and the patient was followed up in the intensive care unit. It was observed that the removed endarterectomy material was compatible with CTEPH (Figure 3). Post-operative transthoracic echocardiography showed that dilatation in the right heart chambers diminished, right ventricular systolic functions recovered, and paradoxical motion of the interventricular septum with D-sign decreased. The phosphodiesterase inhibitor was discontinued and riociguat was added, and the patient was planned to continue warfarin treatment for life. After the hospital follow-up period, which lasted for approximately 20 days, the patient was discharged with medical treatment and close outpatient clinic controls planned.

Informed consent was obtained from the patient.

Discussion

LMCA compression due to PA dilatation in PH patients is encountered with increasing frequency.² Recent progress in

diagnosis and treatment of PH was led to increased survival but consequences of PH like LMCA compression syndrome, can cause sudden cardiac death or LV dysfunction. New-onset exercise angina is an important symptom of LMCA compression.³ Clinically significant LMCA stenosis is defined as 50% or more stenosis.⁴

The incidence of LMCA compression in PH patients was reported as 6% by Galie et al.⁵ and the main PA diameter was larger than 40 mm was the strongest predictor of LMCA compression in this analysis. Mesquita et al.⁶ showed that LMCA stenosis was not related to mPAP or PWR, but was closely related to pulmonary artery diameter (>40 mm) and PA/AA ratio (>1.21). Besides PA diameter, LMCA origin anomaly or narrowed take-off angle poses a risk for LMCA compression syndrome. Kajita et al.⁷ showed that the LMCA ostium was located inferiorly due to pulmonary artery compression in invasive coronary angiography (take-off angle 69.5 ± 150 vs. 22.9 ± 13.40). In our case, the MPA diameter was 47 mm and the LMCA ostial take-off angle was 19.8° , which supports LMCA compression syndrome.

APS is an autoimmune disease characterized by arterial and venous thrombosis with the presence of antiphospholipid antibodies.⁸ The presence of aPL is necessary for diagnosis and they are associated with the hypercoagulable state, leading to thrombosis. APS is classified as primary APS if there is no underlying disease and secondary if there is an associated autoimmune disease such as systemic lupus erythematosus.⁹ The presence of aPL can result in variety of clinical symptoms, such as thrombocytopenia, stillbirth, endocardial pathologies, and recurrent pulmonary embolism. Thrombocytopenia can be present in as many as 23.4% of APS cases.¹⁰ As seen in our case, thrombocytopenia is an important complication that develops on an autoimmune basis in patients with primary AFAS diagnosis.

Multiple deep vein thrombosis attacks and pulmonary embolism are the major risk factors for the development of CTEPH in AFAS patients. According to ESC guidelines, it strongly recommends investigating APS in every patient diagnosed with CTEPH.¹ As known, CTEPH is a subgroup of PH that can be curative. Pulmonary endarterectomy is a curative treatment option in this group of patients who are refractory to medical therapy. In a study including 17 patients with a diagnosis of CTEPH developing secondary to AFAS, after the operation of pulmonary endarterectomy, mean pulmonary artery pressure decreased from 47.82 ± 13.11 mmHg to 22.24 ± 4.56 mmHg ($P < 0.001$), and PVR improved from 756.50 ± 393.91 dyn/s/cm⁻⁵ to 298.31 ± 132.84 dyn/s/cm⁻⁵ ($P < 0.001$). Furthermore, the functional capacity of all patients improved from 269.46 ± 111.7 m to 490 ± 105.34 m on a 6-min walking test.¹¹

Conclusion

LMCA compression syndrome is one of the rare complications that occur as a result of progressive main PA dilatation and can be clinically presented in a wide range from exertional angina to SCD. LMCA compression syndrome should be suspected, especially in PH patients with newly developed anginal complaints, and it is very important to use conventional angiography and CT angiography for its early diagnosis.

PH is a complex disease that can be intertwined with many etiological factors during diagnosis. Patients with a diagnosis of PH may show other subgroup features in their follow-ups for years and CTEPH developing on a thromboembolic background is one of them. AFAS is an etiology that must be investigated in patients with CTEPH. Pulmonary endarterectomy is a curative option in cases of medically refractory PH due to AFAS.

In this case, we described the treatment of LMCA compression due to pulmonary artery dilatation with PCI in a patient followed up with the diagnosis of IPAH. After the newly diagnosed CTEPH due to primary AFAS, we presented its successful treatment with pulmonary endarterectomy. Furthermore, this case was youngest in the literature for LMCA stenting due to PA dilatation.

Informed Consent: Informed consent was obtained from the patient.

Peer-review: Externally peer-reviewed.

Author Contributions: Concept – H.O.A.; Design – U.Y.S.; Supervision – S.K.; Funding – S.K.; Materials – H.O.A., A.G.T., B.Y.; Data Collections and/or Processing – H.O.A., A.G.T., İ.B., A.Ü.; Analysis and/or Interpretation – U.Y.S.; Literature Review – A.G.T., İ.B.; Writing – H.O.A., U.Y.S.; Critical Review – S.K., B.Y.

Conflicts of Interest: No conflict of interest disclosure has been received from the authors.

Funding: The authors declared that this study received no financial support.

Video 1: Transthoracic echocardiography demonstrates significant dilation in the right heart chambers, along with hypertrophy of the free wall of the right ventricle. In addition, there is evident paradoxical motion of the interventricular septum with a significant D-sign observed.

Video 2: Left anterior oblique pose of coronary angiography shows external compression of LMCA ostium.

Video 3: Implantation of drug-eluting stent for LMCA ostial stenosis.

References

- Humbert M, Kovacs G, Hoeper MM, et al.; ESC/ERS Scientific Document Group. 2022 ESC/ERS Guidelines for the diagnosis and treatment of pulmonary hypertension. *Eur Heart J*. 2022;43(38):3618–3731. Erratum in: *Eur Heart J*. 2023;44(15):1312. [\[CrossRef\]](#)
- Vaseghi M, Lee MS, Currier J, Tobis J, Shapiro S, Aboulhosn J. Percutaneous intervention of left main coronary artery compression by pulmonary artery aneurysm. *Catheter Cardiovasc Interv*. 2010;76(3):352–356. [\[CrossRef\]](#)
- Albadri K, Jensen JM, Christiansen EH, Mellemkjær S, Nielsen-Kudsk JE. Left main coronary artery compression in pulmonary arterial hypertension. *Pulm Circ*. 2015;5(4):734–736. [\[CrossRef\]](#)
- Lawton JS, Tamis-Holland JE, Bangalore S, et al. 2021 ACC/AHA/SCAI guideline for coronary artery revascularization: Executive summary: A report of the American College of Cardiology/American Heart Association Joint Committee on clinical practice guidelines. *Circulation*. 2022;145(3):e4–e17. Erratum in: *Circulation*. 2022;145(11):e771. [\[CrossRef\]](#)
- Galiè N, Saia F, Palazzini M, et al. Left main coronary artery compression in patients with pulmonary arterial hypertension and angina. *J Am Coll Cardiol*. 2017;69(23):2808–2817. [\[CrossRef\]](#)
- Mesquita SM, Castro CR, Ikari NM, Oliveira SA, Lopes AA. Likelihood of left main coronary artery compression based on pulmonary trunk diameter in patients with pulmonary hypertension. *Am J Med*. 2004;116(6):369–374. [\[CrossRef\]](#)
- Kajita LJ, Martinez EE, Ambrose JA, et al. Extrinsic compression of the left main coronary artery by a dilated pulmonary artery: Clinical, angiographic, and hemodynamic determinants. *Catheter Cardiovasc Interv*. 2001;52(1):49–54. [\[CrossRef\]](#)
- Miyakis S, Lockshin MD, Atsumi T, et al. International consensus statement on an update of the classification criteria for definite antiphospholipid syndrome (APS). *J Thromb Haemost*. 2006;4(2):295–306. [\[CrossRef\]](#)
- Levine JS, Branch DW, Rauch J. The antiphospholipid syndrome. *N Engl J Med*. 2002;346(10):752–763. [\[CrossRef\]](#)
- Cuadrado MJ, Mujic F, Muñoz E, Khamashta MA, Hughes GR. Thrombocytopenia in the antiphospholipid syndrome. *Ann Rheum Dis*. 1997;56(3):194–196. [\[CrossRef\]](#)
- Taş S, Antal A, Durusoy AF, et al. Pulmonary endarterectomy in patients with antiphospholipid syndrome-associated chronic thromboembolic pulmonary hypertension. *Anatol J Cardiol*. 2022;26(5):394–400.