

Treatment with covered stent of giant femoral artery aneurysm causing deep vein thrombosis

Derin ven trombozuna neden olan dev femoral arter anevrizmasının kaplı stent ile tedavisi

✉ Zeki Şimşek, M.D., ✉ Elnur Alizade, M.D., ✉ İsmail Balaban, M.D.,
✉ Regayip Zehir, M.D., ✉ İbrahim Akın İzgi, M.D., ✉ Selçuk Pala, M.D.

Department of Cardiology, Kartal Koşuyolu High Speciality Trainig and Research Hospital, İstanbul, Turkey

Summary– Femoral artery aneurysm (FAA) is a rare peripheral vascular aneurysm that can lead to thrombosis, embolism and fatal rupture in untreated cases. The clinical presentation of FAA varies from the finding of an asymptomatic mass on routine physical examination to acute limb-threatening ischemia. Presently, a case of FAA that caused deep vein thrombosis and compartment syndrome has been described. Although the current treatment method recommended for FAA is an open surgical procedure, in this case, an endovascular intervention was performed due to high risk of surgical mortality.

Özet– Femoral arter anevrizmaları (FAA), tedavi edilmeyen olgularda tromboz, emboli ve ölümcül rüptüre yol açabilen nadir görülen periferik vasküler anevrizmalardır. FAA'nın klinik prezantasyonu rutin fiziki muayenede saptanan asemptomatik kitleden ekstremiteyi tehdit eden akut iskemiye kadar değişebilmektedir. Bu yazıda, derin ven trombozu ve kompartman sendromuna neden olan bir FAA olgusu sunuldu. FAA'sı için önerilen güncel tedavi şekli açık cerrahi prosedür olmakla birlikte bizim olgumuz yüksek cerrahi mortalite riski nedeni ile endovasküler girişim ile tedavi edildi.

Although it is the second most common type of peripheral aneurysm after those involving the popliteal artery, a femoral artery aneurysm (FAA) is extremely rare. The clinical presentation of FAA varies from the finding of an asymptomatic mass on routine physical examination to acute limb-threatening ischemia. This case report describes a patient with a common FAA causing deep vein thrombosis (DVT) and compartment syndrome and treatment with covered stents.

CASE REPORT

A 75-year-old male patient presented at the outpatient clinic with a 2-week history of right leg swelling and a mass in the right groin that had increased in size over 2 months. A physical examination revealed a tender, pulsatile mass in the right femoral area and diffuse

swelling in the right lower limb with acute compartment syndrome. His medical history revealed coronary artery disease, hypertension, hyperlipidemia and smoking. There was no history of trauma or invasive intervention to the femoral region. Doppler ultrasound revealed superficial and deep femoral vein thrombosis and a 10x8-cm partially thrombosed giant true femoral artery aneurysm. Computed tomography (CT) angiography was performed for enhanced anatomical definition and preoperative planning. Multi-slice CT angiography revealed that a common FAA (105 mm in width x 170 mm in length) was pressing on the femoral vein and femoral nerves (Fig. 1a, b). Discussion in a regional multidisciplinary team meeting led to a decision to perform an

Abbreviations:

ASA	Acetylsalicylic acid
CT	Computed tomography
DVT	Deep vein thrombosis
FAA	Femoral artery aneurysm
SFA	Superficial femoral artery

Received: June 08, 2020 Accepted: September 18, 2020

Correspondence: Dr. Zeki Şimşek. Kartal Koşuyolu Yüksek İhtisas Eğitim ve Araştırma Hastanesi, Kardiyoloji Kliniği, İstanbul, Turkey.

Tel: +90 216 - 500 15 00 e-mail: dr.zeki_simsek@yahoo.com

© 2021 Turkish Society of Cardiology



endovascular intervention because of the high risk of mortality in a surgical operation due to the patient's comorbid diseases, critical illness and hemodynamic instability. Before the procedure, 100 mg of acetylsalicylic acid (ASA) and 600 mg clopidogrel were administered. Angiographic study performed via left common femoral access with a 7-F right Judkins catheter showed a large aneurysm at the connection of the right common femoral artery and the external iliac artery (Fig. 2, Video 1*). The patient was given 10000 IU intravenous unfractionated heparin prior to the procedure. First, a 7-F SheathLess perivascular guiding system (Asahi Intecc Co. Ltd., Seto, Japan) was inserted into the left common femoral artery, and then a 0.035-in hydrophilic guidewire (Radifocus; Terumo Corp., Tokyo, Japan) was inserted inside a 6-F Judkins catheter (Glidecath; Terumo Corp., Tokyo, Japan), and a 6-F left internal mammary artery catheter and a 4-F Navicross support catheter (Ter-

umo Corp., Tokyo, Japan) were used to try to cross from the proximal part of the aneurysm to the distal portion. However, despite multiple attempts, we couldn't cross the hydrophilic guidewire from the right common femoral artery to the superficial artery inside the aneurysm. A retrograde approach to the right superficial femoral artery (SFA) was performed using a 21-G micropuncture needle (Cook Medical Inc., Bloomington, IN, USA) under ultrasound guidance and 6-F sheath was deployed. A 0.035-inch hydrophilic guidewire (Radifocus; Terumo Corp., Tokyo, Japan) was advanced directly from the SFA to the common iliac artery inside the aneurysm with the 6-F Judkins catheter, and the hydrophilic guidewire was used in conjunction with a 7-F sheathless catheter with a peripheral snare (Amplatz Gooseneck Snare; Medtronic Inc., Minneapolis, MN, USA) at the level of the common iliac artery (Fig. 3, Video 2*). Our initial intention was to deploy a long endovascular stent or a long, flexible, covered stent to close this large aneurysm, but unfortunately, the patient's critical condition and the lack of availability of these long stents made the procedure impossible. Therefore, 6.0x59-mm, 10x59-mm and 10x59-mm (Advanta V12; Atrium Medical Corp., Hudson, NH, USA) covered stents were implanted from the SFA to the site of the aneurysm. Finally, a 10x59-mm Advanta V12 covered stent was implanted from the external iliac artery into the stent inside the aneurysm.

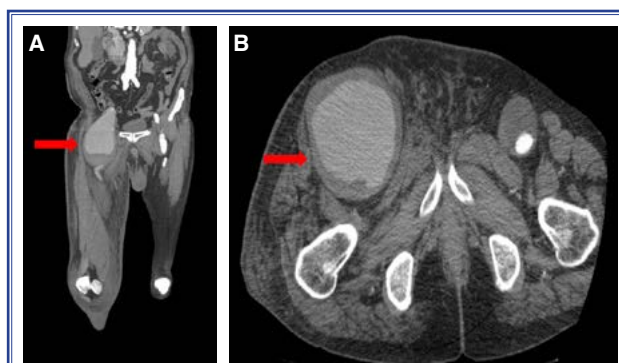


Figure 1. (A, B) A plain computed tomography image revealing a giant common femoral artery aneurysm (arrow).

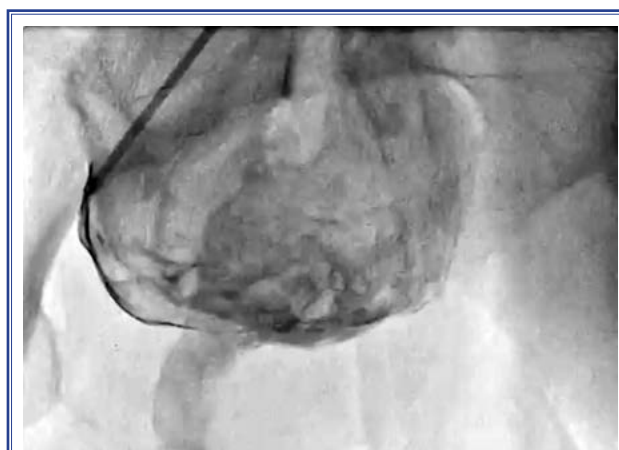

Figure 2. An angiography image of a huge aneurysm at the connection of the right common femoral artery and the external iliac artery.

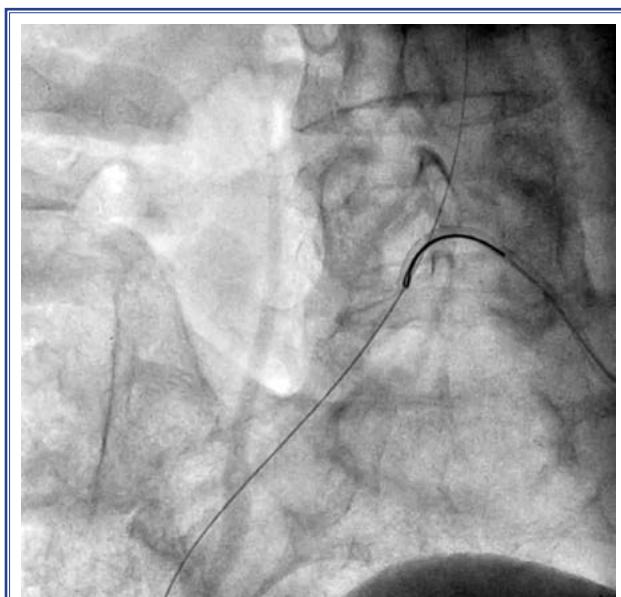


Figure 3. An image of the hydrophilic guidewire and 7-F sheathless catheter with a peripheral snare.

Another angiographic study showed a complete seal of the aneurysm without any endoleak detected (Fig. 4, Video 3*). After the procedure, the patient was followed up in the cardiology clinic for 7 days. Leg elevation was applied and 100 mg/day ASA, 75 mg/day clopidogrel and enoxaparin 6000 IU twice a day were administered during hospitalization. The compartment syndrome and leg swelling decreased and the patient was discharged for ASA 100 mg/day, clopidogrel 75 mg/day, and rivaroxaban 20 mg/day. A control CT scan 1 month later indicated that the stents were intact without any leakage (Fig. 5).

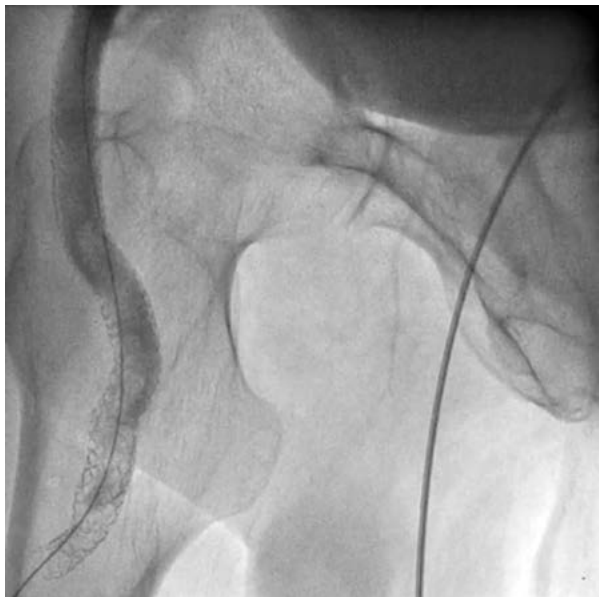

Figure 4. The final angiographic image shows a complete seal of the aneurysm with no endoleak.

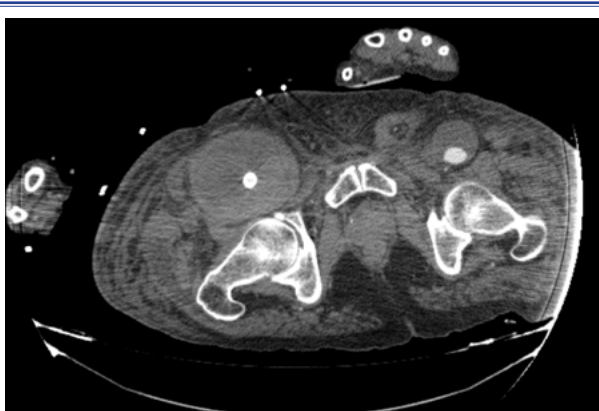


Figure 5. A postoperative computed tomography angiogram image illustrating the successfully implanted covered stents and lack of leakage.

DISCUSSION

Peripheral artery aneurysm is defined as an enlargement of the normal diameter of the artery of 50% or an increase in artery diameter of more than 2 cm.^[1] True femoral artery aneurysms are uncommon, occurring in approximately 5 per 100,000 patients, and include dilation of all layers of the vessel wall.^[2] In contrast, pseudoaneurysms do not involve all of the vessel wall layers. Femoral artery pseudoaneurysms are more common in clinical practice and frequently occur after iatrogenic trauma caused by diagnostic or interventional arterial procedures. The risk factors for FAA are similar to those of other large vessel aneurysms (abdominal aorta, iliac, popliteal), and include older age, male gender, smoking, hypertension, hyperlipidemia, coronary heart disease and peripheral artery disease.^[3,4] Other risk factors include vasculitis and connective tissue disease (e.g., Marfan's syndrome or vasculo-Behçet's syndrome).^[5-7] The clinical presentation of FAA varies from the finding of an asymptomatic mass on routine physical examination to acute limb-threatening ischemia. Patients may notice a new pulsatile mass in the groin region or symptoms such as pain over the mass from compression of the surrounding structures (e.g., the femoral nerve). In our case, since our patient had no history of trauma or femoral intervention to the femoral region, it was thought that the aneurysm might be a real aneurysm, but magnetic resonance imaging is required for a definitive distinction of real and false aneurysm. DVT due to FAA is an extremely rare condition that develops due to direct compression of the aneurysm on a segment of the venous system. It should be taken into consideration as a differential diagnosis of DVT. Although there are literature reports of DVT caused by a superficial femoral artery or deep femoral artery aneurysm,^[8,9] to the best of our knowledge, our case is the first report in the literature of DVT and compartment syndrome caused by aneurysm of the main femoral artery. Symptomatic FAA is largely treated by open surgical repair. The decision to perform FAA repair is based largely upon the diameter of the aneurysm and any associated symptoms, and the location of the aneurysm influences repair options. Most small (<3.0 cm), asymptomatic FAAs can be safely monitored with an annual clinical evaluation and vascular imaging. For large (≥ 3.0 cm), asymptomatic FAAs, repair (typically open surgical) is suggested

for good-risk surgical candidates with a FAA rupture or other symptoms attributable to the aneurysm (e.g., pain, ischemia). Repair is also indicated for an intact symptomatic FAA in order to prevent future complications from rupture, thrombosis, or embolization. Endovascular treatment of an FAA is limited, due to the risk of future stent fracture or migration due to repeated hip flexion. Thus, stent placement in the common femoral artery is generally avoided. In addition, the short length of the common femoral artery makes it difficult to obtain an adequate seal while preserving flow into both the superficial and deep femoral arteries.^[10] Endovascular repair has primarily been performed in urgent situations involving aneurysm rupture or for patients who are hemodynamically unstable, critically ill, or not likely to tolerate traditional open repair, as in the present case.^[11]

Conclusion

An aneurysm of the common femoral artery can compress the femoral vein, resulting in venous stasis, and it should be considered in the differential diagnosis of DVT and compartment syndrome. Repair of a FAA is typically performed using an open surgical approach. Endovascular repair has generally been limited to urgent cases involving aneurysm rupture and patients who cannot tolerate traditional open repair, provided it is anatomically feasible .

*Supplementary video file associated with this article can be found in the online version of the journal.

Peer-review: Externally peer-reviewed.

Conflict-of-interest: None.

Informed Consent: Written informed consent was obtained from the patient for the publication of the case report and the accompanying images.

Authorship contributions: Concept: Z.Ş.; Design: Z.Ş.; Supervision: A.İ.; Materials: E.A.; Data collection: İ.B.; Literature search: R.Z.; Writing: Z.Ş.; Critical revision: S.P.

REFERENCES

1. Canbaz S. Periferik Arter Anevrizmaları. In: Duran E, editor. Kalp ve Damar Cerrahisi. İstanbul: Çapa Tıp Kitabevi; 2004. p.783–98.
2. Lawrence PF, Lorenzo-Rivero S, Lyon JL. The incidence of iliac, femoral, and popliteal artery aneurysms in hospitalized patients. *J Vasc Surg* 1995;22:409–6.
3. Lawrence PF, Harlander-Locke MP, Oderich GS, Humphries MD, Landry GJ, Ballard JL, et al. The current management of isolated degenerative femoral artery aneurysms is too aggressive for their natural history. *J Vasc Surg* 2014;59:343–9.
4. Graham LM, Zelenock GB, Whitehouse WM Jr, Erlanson EE, Dent TL, Lindenauer SM, et al. Clinical significance of arteriosclerotic femoral artery aneurysms. *Arch Surg* 1980;115:502–7..
5. Tüzün H, Beşirli K, Sayin A, FS Vural, V Hamuryudan, N Hizli et al. Management of aneurysms in Behçet's syndrome: an analysis of 24 patients. *Surgery* 1997;121:150–6.
6. Hatrick AG, Malcolm PN, Burnand KG, Irvine AT. A superficial femoral artery aneurysm in a patient with Marfan's syndrome. *Eur J Vasc Endovasc Surg* 1998;15:459–60.
7. Luebke T, Aleksic M, Brunkwall J. Superficial femoral artery aneurysm: a rare complication of Wegener granulomatosis. *Vascular* 2009;17:213–7.
8. Mercado-Alamo A, Zaitoun A, Neupane S, Davis T. Superficial Femoral Artery Aneurysm as a Cause of Deep Vein Thrombosis with a Covered Stent. *J Invasive Cardiol* 2018;30:E124–5.
9. Connor D, Sharp M, Rajagopalan S. Profunda Femoris Artery Aneurysm Causing Local Deep Venous Thrombosis. *J Vasc Surg* 2013;57:1402
10. Mohan IV, Stephen MS. Peripheral arterial aneurysms: open or endovascular surgery? *Prog Cardiovasc Dis* 2013;56:36–56.
11. Kasirajan K, Marek JM, Langsfeld M. Behçet's disease: endovascular management of a ruptured peripheral arterial aneurysm. *J Vasc Surg* 2001;34:1127–9.

Keywords: Compartment syndrome; covered stent; deep vein thrombosis; femoral artery aneurysm.

Anahtar sözcükler: Kompartman sendromu; kaplı stent; derin ven trombozu; femoral arter anevrizması.