

Multimodality imaging of a recurrent case of right-sided cardiac leiomyosarcoma with an unusual clinical course

Sıradışı klinik seyirli tekrarlayan sağ taraflı kardiyak leiomiyosarkomlu olgunun çok yöntemli görüntülenmesi

Mehmet Ali Astarcioglu, M.D., Macit Kalçık, M.D., Mustafa Ozan Gürsoy, M.D.,
Sabahattin Gündüz, M.D., Mehmet Özkan, M.D.

Department of Cardiology, Kartal Kosuyolu Heart Training and Research Hospital, İstanbul

Summary– Primary cardiac sarcoma is an uncommon entity and is related with poor long-term survival. Presented here is an unusual case of right atrial leiomyosarcoma which almost completely occluded both the right atrium and ventricle and destroyed the tricuspid valve. Multimodality imaging was used to characterize the mass and guide surgical management. A combination of two radical surgical excisions and both radiation and chemotherapy resulted in a better long-term outcome. The patient was one of the longest survivors.

Özet– Primer kalp sarkomu kötü uzun süreli sağkalım ile ilişkili nadir bir durumdur. Neredeyse tamamen sağ atriyum ve ventrikülü tıkayan ve triküspit kapağı parçalayan sağ atriyum leiomiyosarkomu bulunan nadir bir olgu sunuldu. Çok cihazlı görüntüleme kitleyi belirlemek ve cerrahi tedavisini yönlendirmek için kullanıldı. İki radikal cerrahi eksizyon, radyasyon ve kemoterapi tedavisinin kombinasyonunun uzun vadeli sonuçları daha iyi idi. Hastamız en uzun sağkalıma sahip olgulardan biriydi.

Primary cardiac sarcomas are extremely rare, and the few reported cases have been treated surgically.^[1] Leiomyosarcoma is a highly aggressive and locally invasive tumor with a mean survival time of 6 months in untreated patients.^[2]

We presented a case of a pathologically proven right-sided leiomyosarcoma associated with subtotal occlusion of both right atrial and ventricular cavities and complete destruction of the tricuspid valve. The longest ever period of remission was observed after aggressive surgical resection and subsequent adjuvant radiochemotherapy.

CASE REPORT

A 40-year-old woman presented to our clinic with 1-month history of progressively worsening dyspnea at rest. Physical examination revealed a rough diastolic murmur in the third left intercostal space at the left sternal border on auscultation. Her electrocardiogra-

phy and chest radiography were unremarkable. Two-dimensional transthoracic echocardiography (2D TTE) with Doppler imaging revealed a mass causing significant right ventricular inflow tract obstruction. Two-dimensional transesophageal echocardiography confirmed the presence of a multilobular mass arising from the interatrial septum. The mass filled up the right atrial cavity, extended through the right ventricular cavity and was causing obstruction of the tricuspid valve (Figure 1a). Real-time 3-dimensional TEE view provided exact spatial information about the shape and contour of the intracardiac mass (Figure 1b, Video*). Computed tomography (CT) scan did not show any mass in the extracardiac area. Cardiac magnetic resonance imaging (MRI) with gadolinium contrast revealed a mass measuring 9x6x3 cm exhib-

Abbreviations:

2D TTE	Two-dimensional transthoracic echocardiography
CT	Computed tomography
MRI	Magnetic resonance imaging
RA	Right atrium
RV	Right ventricle

Received: October 30, 2014 Accepted: February 24, 2015

Correspondence: Dr. Mehmet Ali Astarcioglu. Zeytinlik Caddesi, Emrah Sokak, 7/20, Atalar, Kartal, İstanbul.

Tel: +90 216 - 459 44 40 e-mail: maliastarcioğlu@hotmail.com

© 2015 Turkish Society of Cardiology



iting a broad base of attachment and intramural location (Figure 1c and d).

A cauliflower-like mass within the right atrium (RA) and extending to the right ventricle (RV) was observed during surgery and completely removed (Figure 2a). The histopathological study revealed a spindle cell neoplasm, consistent with leiomyosarcoma, invading the underlying myocardium (Figure 2b). The patient was discharged home on the 17th

postoperative day in a stable condition with planning for anticycline-based chemotherapy and radiation. Follow-up serial TEE studies at 6, 12, 18, 24, 30 and 36 months showed no residual RA and RV mass, but there was severe tricuspid regurgitation.

After a 42-month period of uneventful clinical and laboratory follow-up, the patient was readmitted with dyspnea. 2D TTE and MRI revealed a relapsed tumor in the RA, while CT scanning did not show any

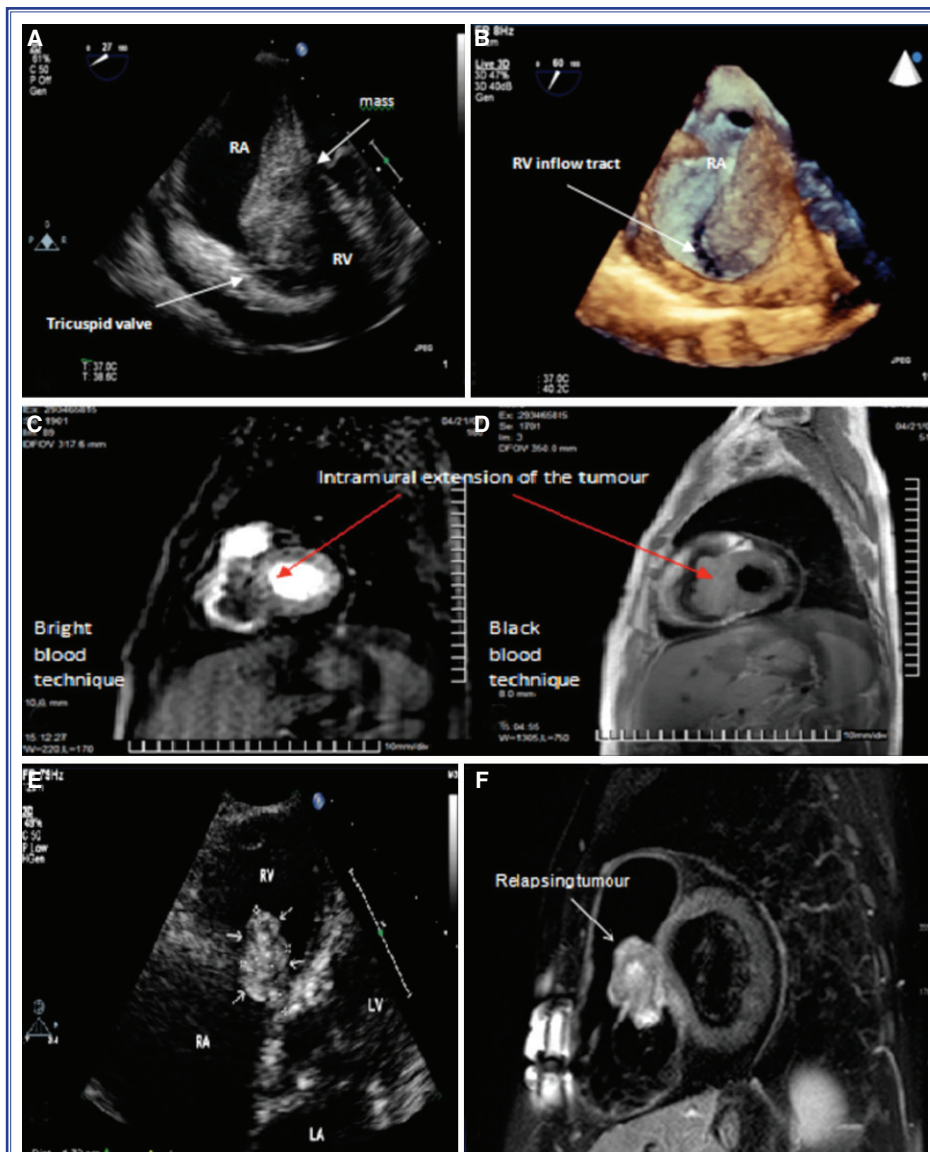
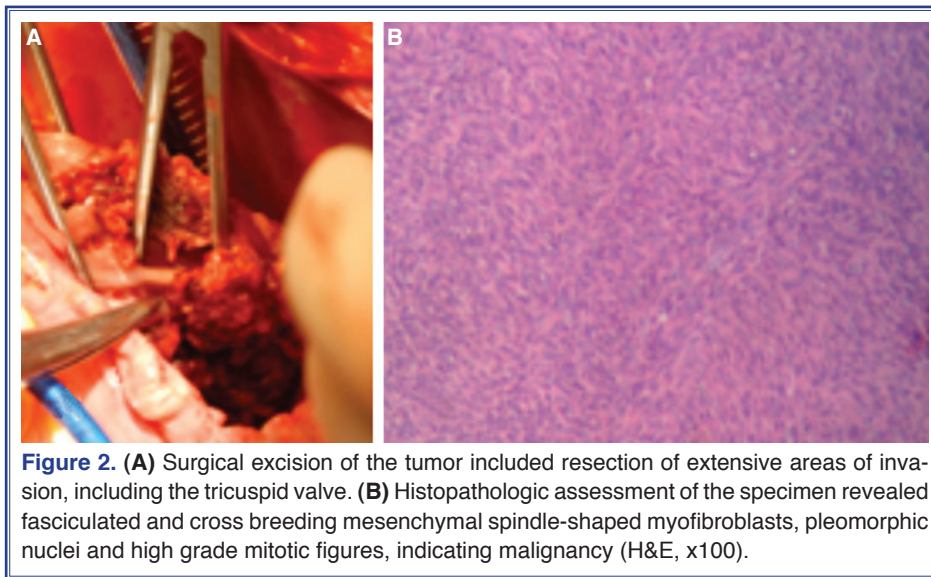


Figure 1. (A) Transesophageal echocardiography revealed a right atrial tumor extending from the septum through the tricuspid valve into the right ventricle. (B) Real-time 3D transesophageal echocardiographic view of the right atrium provided exact spatial information about the shape and contour of the intracardiac mass. Cardiac MRI showed the intramural extension of the tumour by bright blood (C) and black blood MRI technique (D). Imaging of the relapsed tumor with TTE (E) and MRI (F).



extracardiac mass (Figure 1e and f). The tumor was subtotally resected and the patient underwent chemotherapy. Histopathological examination of the tumor showed a leiomyosarcoma. The patient eventually died due to RV heart failure.

DISCUSSION

Cardiac leiomyosarcoma is a rare entity, with 76% of tumors detected in the left atrium, 16% in the right atrium, and 8% diffusely in the ventricles.^[3] Primary leiomyosarcomas are highly aggressive and infiltrate adjacent structures. Although most patients die within 1 year of diagnosis, Glaoui et al. have reported an 8-year survival duration after combined surgical and adjuvant radiochemotherapy.^[4]

While echocardiography is currently a widely-used method for diagnosing cardiac masses, differential diagnosis of cardiac tumors often presents a challenge for the sonographer. When malignancy is suspected, MRI and CT remain essential for operative planning and identification of tumor extension. As demonstrated in our case, the use of gadolinium increases the conspicuity of the tumor by showing different contrast enhancement with respect to the surrounding normal myocardium. Furthermore, it permits differentiation of thrombus from tumor, as thrombus would not be enhanced.^[5]

In our case report, the site of origin of the tumor was the right atrium, which is rare. The presentation was consistent with thromboembolic events frequently

associated with this tumor site. Other possible presentations include progressive or sudden right-sided cardiac failure on the account of tricuspid valve blockage by the tumor, or paroxysmal atrial arrhythmias. Echocardiographic imaging is the most sensitive imaging technique, with the ability to identify tumors as small as 3 mm. The spatial relationship between the mass and adjacent structures could be seen clearly in preoperative 2D and 3D echocardiography, but tissue characterization could not be demonstrated. The primary contribution of MRI in our case was to delineate the anatomical extension of tumor invasion. Inadequately evaluated by echocardiography, the extension of the tumor underneath the myocardium and the broad base of attachment were and were completely assessed by MRI.^[6] A malignant neoplasm was suspected on the basis of MRI findings and a radical excision was planned.

The combination of two radical surgical excisions and both radiation and chemotherapy resulted in a relatively better long-term outcome. To our knowledge, our patient was one of the longest survivors in the literature.

We conclude that the use of echocardiography in conjunction with MRI can provide very valuable data in evaluation of intracardiac masses. MRI may differentiate between malign and benign tumors and provide better anatomical information for preoperative planning. We suggest that cardiac MRI should be performed in all cases of suspected cardiac tumor unless contraindicated.

This report suggests that multimodality imaging and treatment protocol can improve survival in patients with leiomyosarcoma.

Conflict-of-interest issues regarding the authorship or article: None declared.

***Supplementary video file associated with this article can be found in the online version of the journal.**

REFERENCES

1. Rosai J. Rosai and Ackerman's Surgical Pathology. 8th ed. St. Louis: Mosby-Year Book; 1996. p. 2182–8.
2. Mayer F, Aebert H, Rudert M, Königsrainer A, Horger M, Kanz L, et al. Primary malignant sarcomas of the heart and great vessels in adult patients—a single-center experience. *Oncologist* 2007;12:1134–42. [CrossRef](#)
3. Zhang PJ, Brooks JS, Goldblum JR, Yoder B, Seethala R, Pawel B, et al. Primary cardiac sarcomas: a clinicopathologic analysis of a series with follow-up information in 17 patients and emphasis on long-term survival. *Hum Pathol* 2008;39:1385–95. [CrossRef](#)
4. Glaoui M, Benbrahim Z, Belbaraka R, Naciri S, Errihani H, Lescene A. An uncommon long-term survival case of primary cardiac leiomyosarcoma. *World J Surg Oncol* 2014;12:338.
5. Araoz PA, Eklund HE, Welch TJ, Breen JF. CT and MR imaging of primary cardiac malignancies. *Radiographics* 1999;19:1421–34. [CrossRef](#)
6. Winther C, Timmermans-Wielenga V, Daugaard S, Mortensen SA, Sander K, Andersen CB. Primary cardiac tumors: a clinicopathologic evaluation of four cases. *Cardiovasc Pathol* 2011;20:63–7. [CrossRef](#)

Key words: Echocardiography, transesophageal; magnetic resonance imaging; leiomyosarcoma.

Anahtar sözcükler: Ekokardiyografi, transözefajiyal; manyetik rezonans görüntüleme; leomiyosarkom.