

Percutaneous thrombin injection treatment of a femoral artery pseudoaneurysm with simultaneous arterial balloon occlusion: Case report and review of the literature

Femoral arter psödoanevrizmasının eş zamanlı olarak artere balon tıkaması uygulanarak perkütan trombin enjeksiyonu ile tedavisi: Olgu sunumu ve literatürün gözden geçirilmesi

Onur Ergun, M.D., Pınar Çeltikçi, M.D., İdil Güneş Tatar, M.D., Metin Yılmaz, M.D.,[#] Baki Hekimoğlu, M.D.

Department of Radiology, Dışkapı Yıldırım Beyazıt Training and Research Hospital, Ankara, Turkey

[#]Department of Cardiovascular Surgery, Dışkapı Yıldırım Beyazıt Training and Research Hospital, Ankara, Turkey

Summary– Iatrogenic femoral artery pseudoaneurysm at the level of the hip joint in a 52-year-old patient was treated by ultrasound-guided percutaneous thrombin injection, while a balloon was inflated at the neck of the pseudoaneurysm under fluoroscopy, to prevent thrombin leakage to the arterial system.

Özet– İyatrojenik femoral arter psödoanevrizması olan 52 yaşındaki hastanın tedavisi, ultrasonografi eşliğinde perkütan trombin enjeksiyonu esnasında trombinin arteriyel sisteme kaçışını engellemek amacıyla femoral arterde anevrizma boynu seviyesinde anjiyografik olarak balon şişirilerek gerçekleştirildi.

Iatrogenic femoral artery pseudoaneurysm (IFAP) is a well-known

Abbreviations:

CDUS Color Doppler ultrasonography
IFAP Iatrogenic femoral artery pseudoaneurysm
SFA Superficial femoral artery
UGCT Ultrasound-guided compression treatment

complication of endovascular procedures involving femoral artery catheterization for diagnostic or therapeutic intervention. Reported incidence of IFAP is 0.05–2% in cases of diagnostic catheterization and 2–7.7% following coronary or peripheral intervention.^[1] Frequent use of potent anticoagulant and antiplatelet agents during and after the intervention, and utilization of larger sheaths for therapeutic procedures, increases the incidence of this complication.^[1] Traditional treatment of IFAP that has failed to spontaneously resolve is surgical repair, associated with increased morbidity.^[1] Recently favored are minimally invasive endovascular methods.

Presently described was a case of IFAP with a short neck, treated by ultrasound-guided percutane-

ous thrombin injection, while a balloon was inflated at the pseudoaneurysm neck under fluoroscopy, to prevent thrombin leakage to the parent artery.

CASE REPORT

A 52-year-old male patient underwent diagnostic coronary angiography via right femoral artery access and was discharged from the hospital the following day. One week after the procedure, the patient was admitted to the cardiology outpatient clinic with increased pain and swelling at his right groin. Color Doppler ultrasonography (CDUS) revealed a pseudoaneurysm communicating with the right superficial femoral artery (SFA), just distal to the femoral bifurcation, approximately 8 centimeters in diameter, with no sign of thrombosis within the lumen. The pseudoaneurysm sac was located close to the parent artery, with no visible neck. Ultrasound-guided compression treatment (UGCT) was attempted for 1 week. Control CDUS showed that the pseudoaneurysm sac was partially

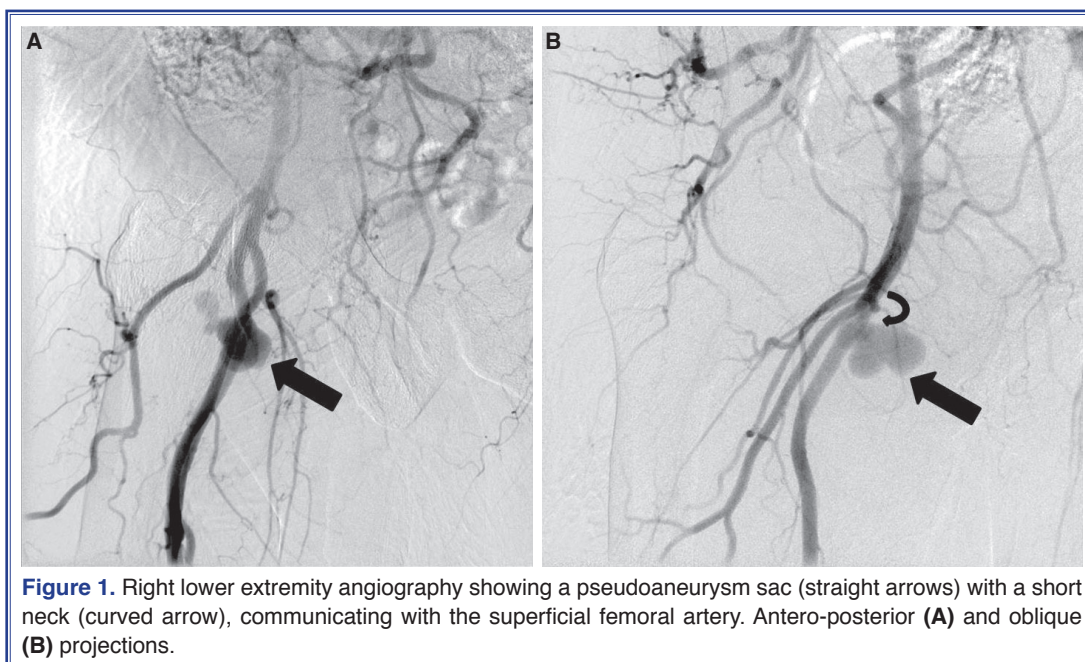
Received: January 19, 2016 Accepted: March 11, 2016

Correspondence: Dr. Onur Ergun. Dışkapı Yıldırım Beyazıt Eğitim ve Araştırma Hastanesi, Radyoloji Kliniği, Dışkapı, Ankara, Turkey.

Tel: +90 312 - 596 26 18 e-mail: onurergun@yahoo.com

© 2016 Turkish Society of Cardiology

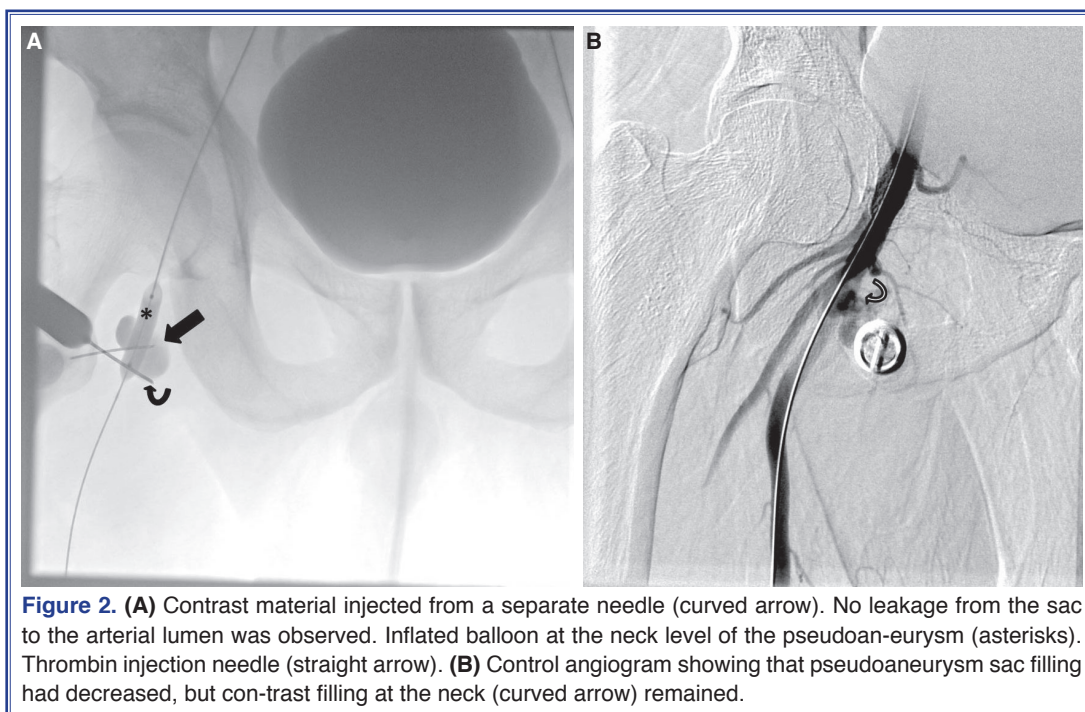




thrombosed, with a filling lumen of 3x2 cm adjacent to the parent artery. UGCT was applied for an additional week, but no change was observed in the filling of pseudoaneurysm.

The patient was referred to the interventional radiology unit for percutaneous, ultrasound-guided thrombin injection. As there was a close relation between

the sac and the parent artery, with no visible neck, percutaneous ultrasound-guided thrombin injection in isolation was thought to bear risk of thrombin leakage to the arterial system. Diagnostic right lower extremity angiography was planned to more accurately assess the pseudoaneurysm sac and its relation with the parent artery. Right lower extremity angiograms obtained with left femoral artery access revealed a pseudoan-



eurysm sac with a short neck communicating with the SFA (Figure 1a, b). Percutaneous ultrasound-guided thrombin injection with simultaneous temporary balloon occlusion of the SFA at the level of the pseudoaneurysm neck was planned.

After placement of 6-F 45-cm sheath (Super Arrow-Flex; Teleflex Medical Europe Ltd., Athlone, Ireland) in the right external iliac artery over left common femoral artery access, a 7-mm x 3-cm balloon catheter (PowerFlex Pro; Cordis Corporation, Hialeah, FL, USA) was inserted at the level of the pseudoaneurysm neck. An 18-G needle was placed in the pseudoaneurysm sac using ultrasonographic guidance, for thrombin injection. Following balloon inflation, contrast material was injected from another needle, in order to ensure the lack of leakage from the sac to the arterial lumen (Figure 2a). Thrombin injection was performed using ultrasonographic guidance while the balloon remained inflated for 1 minute. Control angiogram showed that pseudoaneurysm sac filling had decreased, but that contrast filling remained at the neck (Figure 2b). The needle was repositioned to the neck of the pseudoaneurysm, and the procedure was repeated. Control angiogram showed presence of neither pseudoaneurysm sac nor neck filling (Figure 3a, b). No embolism was observed in the SFA or distal arteries of the right lower extremity. A total of 5000 units of IV heparin was administered during the pro-

cedure to prevent thromboembolic complications. The patient was hospitalized overnight and discharged the following day with recommendation of bed rest. Control CDUS performed at 1 week and 1 month postprocedure showed no filling in the pseudoaneurysm sac, and the patient's complaints were relieved.

DISCUSSION

IFAP occurs when arterial wall defect on the puncture site fails to seal, causing a pulsatile hematoma formation communicating with the arterial lumen, which is confined by surrounding tissues. IFAP usually results from low puncture of the common femoral artery or puncture of the SFA, performed in order to provide access for angiographic procedures. Obesity, arterial hypertension, female sex, and antithrombotic therapy are also risk factors.^[2] These lesions usually present with a pulsatile mass or thrill located at the puncture site. In addition to patient discomfort and delayed hospital discharge, IFAP may cause complications such as rupture, distal embolization, femoral vein compression, neuropathy, or local skin ischemia.^[3,4] Patients with clinical findings suggestive of IFAP should be evaluated with CDUS. CDUS criteria for IFAP diagnosis consists of swirling color flow in a mass separate from the femoral artery, color flow within the tract connecting the mass to the artery, and the typical tofro wave-form in the neck.^[4]

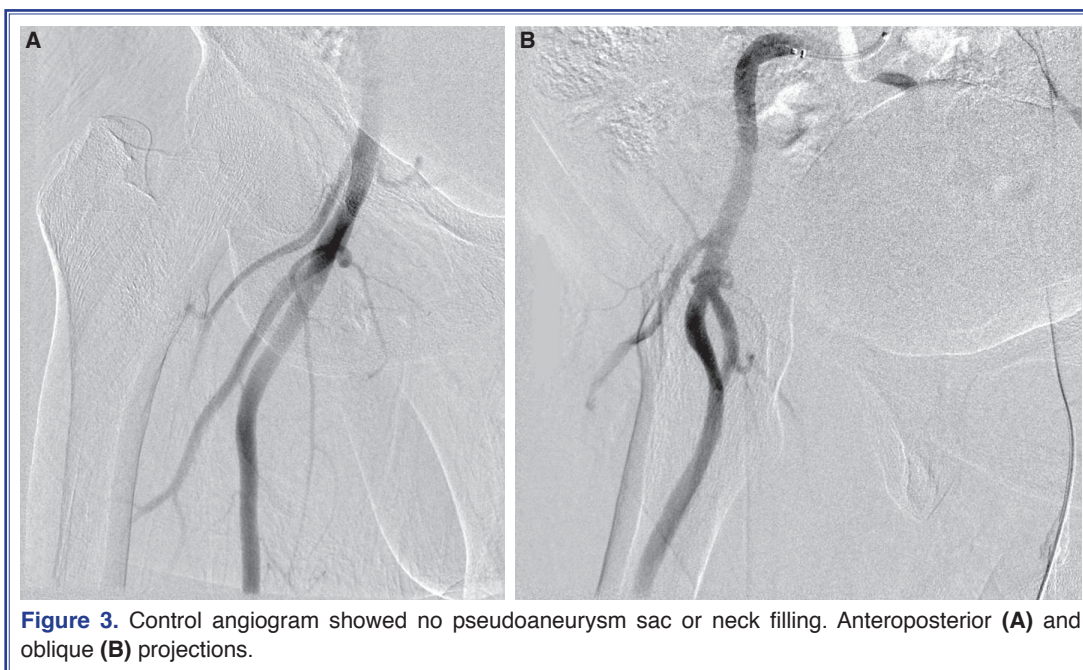


Figure 3. Control angiogram showed no pseudoaneurysm sac or neck filling. Anteroposterior (A) and oblique (B) projections.

IFAP usually has a stable natural course, tending to thrombose spontaneously over time.^[5] In the event of persistence, there are several treatment options. Surgical repair is the traditional approach to femoral pseudoaneurysms, and is an effective method. However, as IFAPs tend to resolve spontaneously, and due to the increased rate of morbidity, surgery should be considered as a treatment option for more unstable types of femoral pseudoaneurysms, such as those secondary to major trauma or infection.^[4] In the past decades, several non-surgical, minimally invasive treatment options have been developed, including UGCT, ultrasound-guided thrombin injection, coil embolization, and covered stent insertion.^[6]

UGCT is a safe and effective method, considered to be a first-line IFAP treatment of choice. However, there are several limitations; it is painful, the neck must be compressed for several minutes, and success rate is lower in patients on anticoagulants.^[4] As an alternative, ultrasound-guided thrombin injection is an efficient method, first described by Cope et al. in 1986 for the treatment of pseudoaneurysms.^[7] The method became popular, nearly a decade after the publication, due to the speed and simplicity of its application, and low rates of associated complication.^[8] Unfortunately, complications do include allergic reaction to bovine thrombin, or more commonly, leakage to the arterial system, which may result in thrombosis of the parent artery or distal embolization. Theoretically, if the pseudoaneurysm is connected to the parent artery with a long and narrow neck, risk of leakage is decreased.^[3] However, a short neck poses greater risk of this complication, as in the present case. To prevent this complication, slow injection of the thrombin under careful Doppler flow examination of the cavity is recommended, as is compression of the neck if possible.^[3,8] If the neck is not visible, or compression is not sufficient, temporary balloon inflation at the neck level is recommended, to prevent thromboembolism.^[9]

Combined use of parent artery balloon occlusion and occlusive agent injections for pseudoaneurysms throughout the body has been reported several times. The most frequently reported location for this procedure is the femoral artery. Samal et al. reported 4 cases of femoral pseudoaneurysms treated with percutaneous thrombin injection and transient balloon occlusion at the origin of the pseudoaneurysm.^[10] All pseudoaneurysms were secondary to diagnostic procedures,

which were combined with therapeutic intervention in some cases. The authors considered UGCT unsuitable for reasons including underlying severe vascular disease, anticoagulant therapy for concomitant conditions (i.e., deep vein thrombosis), and size and tenderness of the lesion. Contralateral femoral artery access was used for balloon catheter and thrombin injection, performed percutaneously. All 4 procedures were successful, without any complications or recurrence. Nakai et al. treated 3 postcatheterization femoral artery pseudoaneurysms with percutaneous n-butyl cyanoacrylate and lipiodol injection (at a ratio of 1:3) under balloon inflation at the femoral artery, after failed attempts at UGCT.^[11] Bhat et al. reported a complicated example of the same procedure in a patient with femoral artery pseudoaneurysm secondary to unsuccessful attempts at insertion of femoral venous line for dialysis.^[12] Following second temporary balloon occlusion for repeated thrombin injection, SFA occlusion was detected. The problem was resolved by immediate aspiration of the thrombus.

Treatment of upper extremity pseudoaneurysm using this technique has also been reported. Aytekin et al. reported a case of radial artery pseudoaneurysm surrounded with a hematoma at the elbow level, formed after a hemodialysis session in a patient with a surgically created arteriovenous fistula in her wrist.^[13] They were unable reach the lesion via the transfemoral route due to the tortuosity of the radial artery, which was secondary to the fistula. Therefore, after retrograde catheterization of the radial artery and inflation of a balloon at the neck level, n-butyl cyanoacrylate and lipiodol were percutaneously injected (1:3 ratio) with ultrasonographic guidance. Complete occlusion of the pseudoaneurysm was achieved, with no sign of distal embolization. A painless small subcutaneous mass formation at the pseudoaneurysm site on follow-up was reported.

Clark et al. reported 2 cases of brachial artery pseudoaneurysms in patients with arteriovenous hemodialysis fistulas formed secondary to arterial dialysis cannula insertion.^[14] One case was treated using ultrasound-guided thrombin injection combined with balloon inflation at the neck level, the other with ultrasound-guided compression of the neck. Balloon inflation was selected in the first case because the swelling of the arm prevented effective compression of the neck. Elford et al. reported a case of axillary artery

pseudoaneurysm formed after inadvertent puncture of the artery during pacemaker insertion via the subclavian vein.^[15] UGCT was impossible due to proximity of the clavicle to the lesion. Ultrasound-guided thrombin injection was performed following isolation of the pseudoaneurysm from the parent artery by balloon inflation. Mittleider et al. reported a femoral artery pseudoaneurysm that connected with the femoral vein by an arteriovenous fistula.^[16] They treated the pseudoaneurysm using ultrasound-guided thrombin injection combined with balloon occlusion of the femoral vein at the level of the arteriovenous fistula.

In addition to peripheral arterial applications of this procedure, Holder et al. reported a case of carotid artery pseudoaneurysm secondary to accidental carotid artery puncture during internal jugular vein cannulation, treated successfully using this technique.^[17] UGCT trial had failed, and surgery was considered risky, given the patient's poor condition. Thrombin injection was selected over stent-graft placement due to the long neck of the pseudoaneurysm. The common carotid artery was occluded for 10 seconds at the level of the neck, while thrombin was percutaneously injected under ultrasonographic guidance, resulting in instantaneous thrombosis of the lesion. No neurological symptoms were reported.

Owen et al. published a case series of 25 pseudoaneurysms treated by ultrasound-guided injection of thrombin or tissue adhesive. In 19 cases, protective balloon occlusion of the pseudoaneurysm neck was performed during the injection of tissue adhesive.^[18] Pseudoaneurysms were located at the femoral, tibio-peroneal, posterior tibial, and popliteal arteries. Previous UGCT had failed in all patients, and all pseudoaneurysms were successfully treated, with no embolic complications. One patient developed contralateral femoral pseudoaneurysm secondary to additional puncture. Three femoral pseudoaneurysms were occluded by balloon occlusion of the neck, with 1 requiring additional injection of tissue adhesive.

Use of balloon to cover the pseudoaneurysm neck during thrombin injection in order to protect the native vessel was first reported by Loose and Haslam,^[9] and the need for this measure has been widely discussed. Owen et al. concluded that the protective intervention is unnecessary, as the only complication occurred secondary to additional intervention.^[18] In the case reported by Bhat et al., distal thrombosis oc-

curred in spite of the protective procedure.^[12] However, other authors prefer the protective measure of balloon occlusion, advocating this use in the avoidance of distal embolic complications. Holder et al., in a report concerning carotid pseudoaneurysm, pointed out that pseudoaneurysm location and potential risks should be considered.

This technique bears potential additional complications, such as contralateral puncture site-related problems (pseudoaneurysm or hematoma formation, infection, etc.), parent artery rupture, dissection secondary to balloon inflation, parent artery thrombosis, distal embolism, and pseudoaneurysm rupture.^[12,18]

In the present case, the location of the pseudoaneurysm was very close to the hip joint, rendering treatment with covered stent-graft unreasonable. Given the size of the pseudoaneurysm, coil embolization of the sac was considered not to be cost-effective. When considering thrombin injection in isolation, the pseudoaneurysm was too large to effectively compress, and had a short neck that could hardly be visualized on ultrasonography, increasing the risk of leakage of the injected thrombin. For these reasons, we decided to combine ultrasound-guided thrombin injection with simultaneous balloon inflation at the neck level. While this additional intervention provided a safer procedure, it requires additional arterial puncture, which can be considered a disadvantage.

When UGCT is unsuccessful or impossible, when distal embolism creates a high risk of increase in morbidity and mortality, or when the pseudoaneurysm neck is wide, short, or both, we believe that thrombin injection should be combined with balloon occlusion.

Conclusion

Ultrasound-guided thrombin injection with simultaneous balloon inflation at the neck level provides a safe and efficient treatment for large IFAPs, particularly in those with a short or wide neck. However, larger studies are needed to determine if the combined procedure truly decreases the risk for thromboembolism, or increases morbidity, given the additional intervention.

Conflict-of-interest issues regarding the authorship or article: None declared.

REFERENCES

1. Webber GW, Jang J, Gustavson S, Olin JW. Contemporary

- management of postcatheterization pseudoaneurysms. *Circulation* 2007;115:2666–74. [Crossref](#)
2. Słonina J, Obremska M, Zaleska-Dorobisz U, Agrawal A, Malczewska J, Koźmińska U, et al. Personal experiences in direct ultrasound-guided injection of thrombin into the lumen of pseudoaneurysm as a method of treatment in case of iatrogenic femoral artery damage. *Pol J Radiol* 2010;75:33–7.
 3. Ferguson JD, Whatling PJ, Martin V, Walton J, Banning AP. Ultrasound guided percutaneous thrombin injection of iatrogenic femoral artery pseudoaneurysms after coronary angiography and intervention. *Heart* 2001;85:5. [Crossref](#)
 4. Eisenberg L, Paulson EK, Kliewer MA, Hudson MP, DeLong DM, Carroll BA. Sonographically guided compression repair of pseudoaneurysms: further experience from a single institution. *AJR Am J Roentgenol* 1999;173:1567–73. [Crossref](#)
 5. Paulson EK, Hertzberg BS, Paine SS, Carroll BA. Femoral artery pseudoaneurysms: value of color Doppler sonography in predicting which ones will thrombose without treatment. *AJR Am J Roentgenol* 1992;159:1077–81. [Crossref](#)
 6. Hamraoui K, Ernst SM, van Dessel PF, Kelder JC, ten Berg JM, Suttorp MJ, et al. Efficacy and safety of percutaneous treatment of iatrogenic femoral artery pseudoaneurysm by biodegradable collagen injection. *J Am Coll Cardiol* 2002;39:1297–304. [Crossref](#)
 7. Cope C, Zeit R. Coagulation of aneurysms by direct percutaneous thrombin injection. *AJR Am J Roentgenol* 1986;147:383–7. [Crossref](#)
 8. Aytakin C, Firat A, Yildirim E, Kirbas I, Boyvat F. Ultrasound-guided glue injection as alternative treatment of femoral pseudoaneurysms. *Cardiovasc Intervent Radiol* 2004;27:612–5.
 9. Loose HW, Haslam PJ. The management of peripheral arterial aneurysms using percutaneous injection of fibrin adhesive. *Br J Radiol* 1998;71:1255–9. [Crossref](#)
 10. Samal AK, White CJ, Collins TJ, Ramee SR, Jenkins JS. Treatment of femoral artery pseudoaneurysm with percutaneous thrombin injection. *Catheter Cardiovasc Interv* 2001;53:259–63. [Crossref](#)
 11. Nakai M, Sato M, Sanda H, Ikoma A, Kawai N, Minamiguchi H, et al. Percutaneous fluoroscopically guided n-butyl cyanoacrylate (NBCA) injection for iatrogenic femoral arterial pseudoaneurysm under temporary balloon occlusion of arterial blood flow. *Jpn J Radiol* 2012;30:365–9. [Crossref](#)
 12. Bhat R, Chakraverty S. Femoral artery thrombosis following percutaneous treatment with thrombin injection of a femoral artery pseudoaneurysm: a case report. *Cardiovasc Intervent Radiol* 2007;30:789–92. [Crossref](#)
 13. Aytakin C, Boyvat F, Gebedek O, Coskun M. Balloon-assisted ultrasound-guided direct percutaneous embolization of a peripheral pseudoaneurysm with n-butyl cyanoacrylate. *Eur Radiol* 2002;12 Suppl 3:185–8.
 14. Clark TW, Abraham RJ. Thrombin injection for treatment of brachial artery pseudoaneurysm at the site of a hemodialysis fistula: report of two patients. *Cardiovasc Intervent Radiol* 2000;23:396–400. [Crossref](#)
 15. Elford J, Burrell C, Roobottom C. Ultrasound guided percutaneous thrombin injection for the treatment of iatrogenic pseudoaneurysms. *Heart* 1999;82:526–7. [Crossref](#)
 16. Mittleider D, Cicuto K, Dykes T. Percutaneous thrombin injection of a femoral artery pseudoaneurysm with simultaneous venous balloon occlusion of a communicating arteriovenous fistula. *Cardiovasc Intervent Radiol* 2008;31 Suppl 2:S115–9.
 17. Holder R, Hilton D, Martin J, Harris PL, Rowlands PC, McWilliams RG. Percutaneous thrombin injection of carotid artery pseudoaneurysm. *J Endovasc Ther* 2002;9:25–8. [Crossref](#)
 18. Owen RJ, Haslam PJ, Elliott ST, Rose JD, Loose HW. Percutaneous ablation of peripheral pseudoaneurysms using thrombin: a simple and effective solution. *Cardiovasc Intervent Radiol* 2000;23:441–6. [Crossref](#)
- Keywords:** Endovascular procedures; pseudoaneurysm; thrombin.
- Anahtar sözcükler:** Endovasküler işlemler; psödoanevrizma; trombin.