

Case series of three different scenarios with drug-induced Brugada patterns: fact or fiction?

İlaç kaynaklı Brugada fenotipi, üç farklı senaryonun olgu serisi: Gerçek ya da kurgu?

Serkan Asil, M.D.,¹ Uğur Canpolat, M.D.,² Ergün Barış Kaya, M.D.,²
Kudret Aytemir, M.D.,² Giray Kabakçı, M.D.²

¹Department of Cardiology, Gülhane Training and Research Hospital, Ankara, Turkey

²Department of Cardiology, Hacettepe University Faculty of Medicine, Ankara, Turkey

Summary– Brugada syndrome is an inherited cardiac arrhythmia condition characterized by coved-type ST elevation and J point elevation of at least 2 mm in at least 2 of the right precordial electrocardiogram (ECG) leads (V1–3). An increasing number of noncardiac agents, including psychotropic and anesthetic drugs, have been shown to induce a characteristic Brugada ECG pattern, predisposing the patient to fatal ventricular arrhythmias. However, there are scarce data regarding the clinical significance. In this case series, a typical Brugada pattern was unmasked by lithium, valproic acid, and thiocolchicoside; however, the clinical scenario was different in all 3 cases, ranging from an asymptomatic patient to sudden cardiac arrest.

Brugada syndrome (BS) is an inherited cardiac arrhythmia condition characterized by coved-type ST elevation and J point elevation of at least 2 mm in at least 2 of the right precordial electrocardiogram (ECG) leads (V1–3) that is unrelated to ischemia, electrolyte disturbance, or obvious structural heart disease. A Brugada pattern on ECG can occur either spontaneously or after a provocative drug test with intravenous administration of sodium channel blockers (such as ajmaline, flecainide, procainamide, or pilsicainide).^[1] In addition to diagnostic agents, there are lists of other well-known drugs (antidepressants, antihistaminics, anesthetics/analgesics, and antispasmodic agents, etc.) that should be avoided by BS patients when possible, due to the potential induction of a Bru-

Özet– Brugada sendromu sağ prekordiyal EKG derivasyonlarının (V1-3) en az ikisinde ≥ 2 mm coved tipte J noktası ve ST yükselmesi ile karakterize kalıtsal bir kalp hastalığıdır. Psikotropik ve anestetik ilaçlar da dahil olmak üzere artan sayıda kalp dışı ilacın ölümcül ventrikül aritmilerine yatkınlığı artıran Brugada fenokopisini tetiklediği gösterilmiştir. Ancak bu durumun klinik önemi ile ilgili net veri bulunmamaktadır. Bu olgu serisinde hastalarımızdaki tipik Brugada paterninin; lityum, valproik asit ve tiyokolşikosid ile maskeleyebileceği düşünülmüştür. Ancak klinik senaryonun her üç olguda da farklı olduğu, semptomsuz ve ani kalp durması arasında değiştiği izlenmiştir.

gada ECG pattern or fatal arrhythmia. However, there are scarce data regarding the clinical significance. This is a case series of 3 patients for whom a diagnosis of BS was unmasked after the administration of drugs from 3 different groups (lithium, valproic acid, and thiocolchicoside).

Abbreviations:

BS	Brugada syndrome
ECG	Electrocardiogram
RBBB	Right bundle branch block
SCD	Sudden cardiac death
VF	Ventricular fibrillation
VT	Ventricular tachycardia

CASE REPORT

Case 1– A 48-year-old woman presented at the outpatient clinic with the complaint of short-duration episodes of palpitations. She had been diagnosed with

Received: December 13, 2016 Accepted: March 13, 2017

Correspondence: Dr. Serkan Asil. Kırkkonaklar Mahallesi, 354. Cadde, No: 6/2, 06100 Ankara, Turkey.

Tel: +90 312 - 304 20 00 e-mail: dr_serkanasil@hotmail.com

© 2017 Turkish Society of Cardiology



bipolar disorder 4 years earlier and was taking lithium. Laboratory and echocardiographic findings were normal and the lithium level was 0.91 mmol/L (therapeutic range: 0.6–1.2 mmol/L). ECG performed on admission showed sinus rhythm with an incomplete right bundle branch block (RBBB) and spontaneous, coved-type ST segment elevation in ≥ 2 leads among the right precordial leads (type 1 Brugada pattern) (Figure 1a). Her family history was negative for sudden cardiac death (SCD) and she had not experienced any syncopal episode. No episode of arrhythmia was seen in the results of 24-hour Holter monitoring. After a consultation with the psychiatry outpatient clinic, a 1-week halt of the lithium therapy and repetition of the ECG was planned. One week later, resting ECG revealed no abnormality in V1-2 derivations (Figure 1b). The patient then underwent ajmaline provocation test; the result was negative for typical Brugada patterns (Figure 1c). The patient was diagnosed as asymptomatic drug-induced type 1 Brugada pattern according to the last expert consensus on the Brugada ECG phenocopies.^[2] Clinical follow-up was recommended, along with cessation of and replacement for lithium therapy. On subsequent follow-up visits, the ECG indicated only incomplete RBBB and the patient remained asymptomatic for 3 years.

Case 2— A 38-year-old man presented with the complaints of palpitations and atypical chest discomfort. His past medical history was negative for syncope or pre-syncope, but he had a diagnosis of generalized epileptic seizures and had been taking valproic acid for 2 years. The family history was negative for SCD. A physical examination revealed no abnormality. Laboratory test, chest X-ray, and transthoracic echocardiography results were within normal limits.

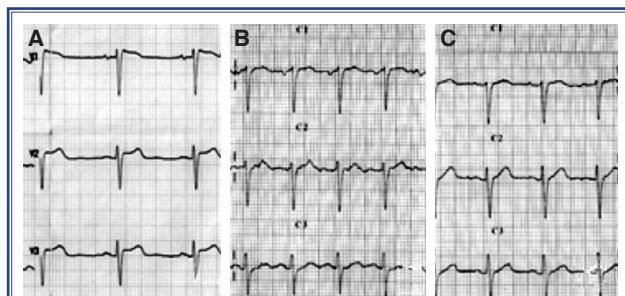


Figure 1. (A) Electrocardiogram (ECG) of the patient at admission to the hospital consistent with Brugada type 1 pattern. (B) Second ECG with normal findings after cessation of lithium. (C) After the ajmaline challenge test, the ECG showed normal findings.

On admission, ECG showed sinus rhythm (70 bpm), and saddle-back-type ST segment elevation at V1-2 derivations (type 2 Brugada pattern) (Figure 2a). Therefore, ajmaline provocation test was planned. ECG performed after shifting V1-2 leads to the second intercostal space also revealed a type 1 Brugada pattern in V1-2 derivations (Figure 2b). The ajmaline drug challenge also confirmed the type 1 Brugada pattern in V1-2 derivations (Figure 2c). The patient was diagnosed as asymptomatic Type 1 Brugada pattern. Close clinical follow-up was planned and he was warned to avoid modulating factors, like drugs or fever. Consultation with a neurologist was also scheduled to discuss switching from the use of valproic acid to another anti-epileptic drug.

Case 3— A 42-year-old male patient presented at the emergency room due to cardiopulmonary arrest just

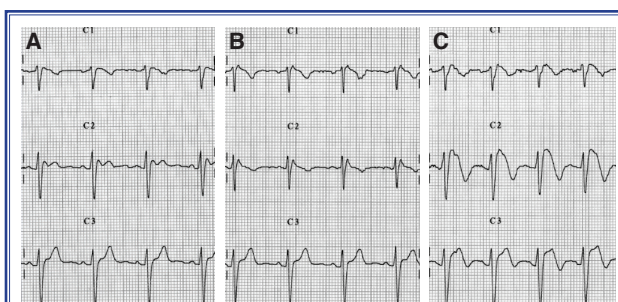


Figure 2. (A) At baseline, a saddleback-type ST segment (type 2) is present in the right precordial leads. (B) Electrocardiogram with right precordial leads shifted to the second intercostal space revealed a type 1 Brugada pattern in the V1-2 derivations. (C) Ajmaline drug challenge test showing a type 1 Brugada pattern in the V1-2 derivations.

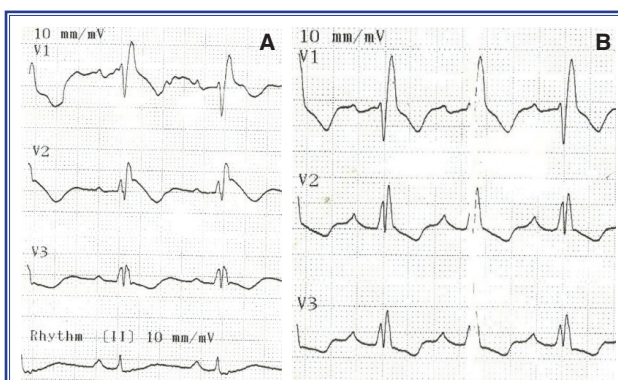


Figure 3. (A) Electrocardiogram (ECG) of the patient at admission to the hospital consistent with coved-type ST segment elevation at V1-2 derivations. (B) Subsequent ECG indicated a sinus rhythm and right bundle branch block without ST segment elevation.

after administration of thiocolchicoside (Muscoflex 8-mg capsule; Bilim İlaç Sanayi ve Ticaret A.Ş., İstanbul, Turkey) for neck spasms. His past medical history was unremarkable, including prescription medications and OTCs. Family history included the sudden premature death of his uncle at the age of 35 years for an unknown reason. His initial examination revealed a blood pressure of 110/75 mmHg, a pulse rate of 80 bpm, and normal neurological and other system examinations. On admission, a resting ECG demonstrated a sinus rhythm (63 bpm), complete RBBB, and coved-type ST segment elevation at V1-2 derivations (type 1 Brugada pattern) (Figure 3a). Echocardiography demonstrated normal function and diameter of both ventricles and atria, and mild regurgitation in the mitral and tricuspid valves. Laboratory tests, including a cardiac panel and D-dimer level, revealed no abnormality. The patient was hospitalized in the coronary care unit for 2 days. His follow-up ECG on the second day of hospitalization showed a sinus rhythm (84 bpm) and RBBB without ST segment elevation (Figure 3b). Cardiac magnetic resonance imaging was performed to exclude structural abnormalities, such as arrhythmogenic right ventricular dysplasia, and yielded normal findings. Treadmill exercise test produced no arrhythmic episode during maximal exertion. He was diagnosed as BS, and an implantable cardioverter defibrillator was successfully implanted for secondary prophylaxis.^[2] The remainder of his hospital stay was uneventful. He was reminded to abstain from drugs and conditions as indicated on the website <http://www.brugadadrugs.org/>. The patient was admitted to the emergency room with an appropriate ICD shock after a febrile episode of lobar pneumonia 6 months after ICD implantation.

DISCUSSION

BS is diagnosed in patients with ST segment elevation with type 1 morphology of ≥ 2 mm in 1 or more leads among the right precordial leads V1 and/or V2 positioned in the second, third, or fourth intercostal space.^[1] The ECG signature of BS is dynamic and often concealed, but it can be unmasked by sodium channel blockers, such as flecainide, ajmaline, and procainamide.^[1] BS is considered to be responsible for 4% to 12% of all SCDs, and for at least 20% of deaths that occur in patients with structurally normal hearts.^[3]

Currently, ICD implantation is the only effective therapy for patients with spontaneous, type 1 ECG pattern and aborted sudden cardiac arrest, documented spontaneous sustained ventricular tachycardia (VT), or syncope of arrhythmic origin.^[1] Accumulating data have shown that an increasing number of drugs commonly prescribed in routine clinical practice unmask or induce a characteristic ECG pattern of BS, which predisposes the patient to ventricular arrhythmia.^[4]

Lithium is widely used for the primary treatment of bipolar disorders. Lithium can cause a wide range of cardiac side effects, including QT interval prolongation, ST segment and T wave changes, bradycardia, sinus node dysfunction, atrioventricular block, and ventricular fibrillation (VF).^[5] It has been reported that lithium may induce typical Brugada patterns on ECG, even in suggested therapeutic doses.^[6] The clinical presentation ranges from isolated, asymptomatic ECG patterns to cardiac syncope and SCD.^[6] Discontinuation of lithium results in normalization of the ECG or conversion to type 2 or 3 Brugada ECG pattern.^[7] Lithium has been demonstrated to block the sodium channels in a dose-dependent manner.^[7] In patient 1, the type 1 Brugada ECG pattern only became apparent while under lithium treatment and normalized just after removal of the drug. This case supports the reported causal relationship between lithium and the unmasking of type 1 Brugada pattern.

There are no reports of valproic acid exacerbating or unmasking BS at therapeutic or toxic doses. Valproic acid has multiple cellular mechanisms of action, consistent with its broad clinical effectiveness. One mechanism of action is similar to that of both phenytoin and carbamazepine, and appears to be mediated by a prolonged recovery of voltage-activated sodium channels from inactivation, increasing brain gamma-aminobutyric acid (GABA) concentrations at clinically relevant doses, and acting against T-type calcium currents.^[8] There is no specific information on the cardiac sodium or calcium channel-blocking properties of valproic acid. Unlike in the first case, the use of valproic acid was continued in this patient by the neurologist. Thus, we do not know whether interruption of the drug would cause any change in the ECG. To our knowledge, this is the first case illustrating an association between valproic acid and a Brugada pattern on ECG.

Thiocolchicoside is a muscle relaxant with anti-

inflammatory and analgesic effects.^[9] It acts as a competitive GABAA receptor antagonist and a glycine receptor antagonist with similar potency, as well as being an antagonist for nicotinic acetylcholine receptors to a much lesser extent.^[10] It is a powerful convulsant, and should not be used in seizure-prone individuals. Although the impact of various centrally acting, anti-spastic agents on sodium channels is known, there are no data regarding the effect of thiocholicoside on sodium channels and no report of an association with Brugada pattern on ECG. To the best of our knowledge, this case is the first in the literature showing a direct relationship between thiocholicoside and BS, and it should be listed among the drugs to be avoided by patients with BS.

A Brugada ECG pattern has been attributed to differences in action potential duration and configuration between the endocardium and the epicardium, mainly in the right ventricle.^[11] In theory, a reduction in sodium or L-type calcium, or an increase in potassium current (dominant in the epicardium) would produce a striking abbreviation of the epicardial action potential, which would lead to an epicardial-endocardial heterogeneity of repolarization that would cause ST segment elevation. To date, not just reductions in sodium current caused by drugs or mutations in SCN5A, but also other drugs and mutations may be associated with a Brugada pattern, such as valproic acid and thiocholicoside. Königstein et al. reported that male sex, psychotropic agents, and drug overdose are risk factors.^[12] According to the same study results, the most commonly reported agent was intravenous propofol, and the oral agents were lithium and amitriptyline.^[12]

According to a J wave syndromes expert consensus report, it was recommended that when a type 1 ST segment elevation is unmasked using a sodium channel blocker, diagnosis of BS also requires that the patient also present with 1 of the following: documented VF or polymorphic VT, syncope of probable arrhythmic cause, a family history of SCD at <45 years old with negative autopsy, coved-type ECG in family members, or nocturnal agonal respiration. Inducibility of VT/VF with 1 or 2 premature beats supports the diagnosis of BS under these circumstances.^[2] These recommendations are emphasized to prevent unnecessary implantable cardioverter defibrillator therapy in these patients with low SCD risk.^[2]

Conclusion

A drug-induced Brugada pattern or Brugada phenotype should be considered a predictor of SCD, and thus should prompt critical reevaluation of the risks and benefits of the suspicious medication. We think that a typical Brugada pattern in our patients was unmasked by lithium, valproic acid, and thiocholicoside. The literature data are still inadequate with regard to the prognosis of drug-induced Brugada pattern patients. Interruption of use of the drug is an effective preventive strategy in most cases of drug-induced BS.

Conflict-of-interest: None declared.

REFERENCES

1. Priori SG, Blomström-Lundqvist C, Mazzanti A, Blom N, Borggrefe M, Camm J, et al. 2015 ESC Guidelines for the management of patients with ventricular arrhythmias and the prevention of sudden cardiac death: The Task Force for the Management of Patients with Ventricular Arrhythmias and the Prevention of Sudden Cardiac Death of the European Society of Cardiology (ESC) Endorsed by: Association for European Paediatric and Congenital Cardiology (AEPC). *Europace* 2015;17:1601–87. [\[CrossRef\]](#)
2. Antzelevitch C, Yan G-X, Ackerman MJ, Borggrefe M, Corrado D, Guo J, et al. J-Wave syndromes expert consensus conference report: Emerging concepts and gaps in knowledge. *J Arrhythm* 2016;32:315–39. [\[CrossRef\]](#)
3. Letsas KP, Kavvouras C, Kollias G, Tsikrikas S, Korantzopoulos P, Efremidis M, et al. Drug-Induced Brugada Syndrome by Noncardiac Agents. *Pacing and Clinical Electrophysiology* 2013;36:1570–7. [\[CrossRef\]](#)
4. Postema PG, Wolpert C, Amin AS, Probst V, Borggrefe M, Roden DM, et al. Drugs and Brugada syndrome patients: review of the literature, recommendations, and an up-to-date website (www.brugadadrugs.org). *Heart Rhythm* 2009;6:1335–41. [\[CrossRef\]](#)
5. Mateer JR, Clark MR. Lithium toxicity with rarely reported ECG manifestations. *Ann Emerg Med* 1982;11:208–11.
6. Wright D, Salehian O. Brugada-type electrocardiographic changes induced by long-term lithium use. *Circulation* 2010;122:418–9. [\[CrossRef\]](#)
7. Darbar D, Yang T, Churchwell K, Wilde AA, Roden DM. Unmasking of Brugada syndrome by lithium. *Circulation* 2005;112:1527–31. [\[CrossRef\]](#)
8. Löscher W. Basic pharmacology of valproate. *CNS drugs* 2002;16:669–94. [\[CrossRef\]](#)
9. Ketenci A, Basat H, Esmailzadeh S. The efficacy of topical thiocholicoside (Muscoril) in the treatment of acute cervical myofascial pain syndrome: a single-blind, randomized, prospective, phase IV clinical study. *Agri* 2009;21:95–103.

10. Carta M, Murru L, Botta P, Talani G, Sechi G, De Riu P, et al. The muscle relaxant thiocolchicoside is an antagonist of GABA A receptor function in the central nervous system. *Neuropharmacology* 2006;51:805–15. [CrossRef]
 11. Antzelevitch C, Brugada P, Brugada J, Brugada R, Towbin JA, Nademanee K. Brugada syndrome: 1992–2002: a historical perspective. *J Am Coll Cardiol* 2003;41:1665–71. [CrossRef]
 12. Konigstein M, Rosso R, Topaz G, Postema PG, Friedensohn L, Heller K, et al. Drug-induced Brugada syndrome: Clinical characteristics and risk factors. *Heart Rhythm* 2016;13:1083–7. [CrossRef]
-
- Keywords:** Brugada syndrome; drug-induced; electrocardiography.
- Anahtar sözcükler:** Brugada sendromu; ilaç; elektrokardiyografi.