

JUVENILE GRANULOSA CELL TUMOR IN A WOMAN WITH MAFFUCCI SYNDROME; THE ELDEST CASE IN LITERATURE

Behiye Pinar Cilesiz GOKSEDEF¹, Safak Yilmaz BARAN¹, Ahmet TARLACI², Mihriban GURBUZEL², Ahmet CETIN¹

¹ Department of Gynecology and Obstetric, Haseki Teaching and Research Hospital, Istanbul

² Department of Pathology, Haseki Teaching and Research Hospital, Istanbul

SUMMARY

Maffucci syndrome is a rare disorder associated with multiple enchondromatosis and soft tissue hemangiomas. An association of enchondromatosis and juvenile granulosa cell tumor (JGCT) at a young age has been previously reported. Four cases of Maffucci syndrome with JGCT were reported in the literature until 2009 and the eldest patients with Maffucci syndrome and JGCT was 21 years old. We report eldest patient with Maffucci syndrome who developed a JGCT in the literature.

Key words: enchondromatosis, granulosa cell tumor, hemangiomas, maffucci syndrome

Journal of Turkish Society of Obstetrics and Gynecology, (J Turk Soc Obstet Gynecol), 2012; Vol: 9, Issue: Supplement, Pages: 36- 9

MAFUCCI SENDROMLU KADIN HASTADA JUVENİL GRANÜLOZA HÜCRELİ TÜMÖR: LİTERATÜRDEKİ EN YAŞLI OLGU

ÖZET

Maffucci sendromu, multipl encondromatozis ve yumuşak doku hemanjiomları ile ilişkili nadir görülen bir sendromdur. Genç yaştaki olgularda encondromatozis ile juvenil granuloza hücreli tümör (JGHT) ilişkisi daha önce bildirilmiştir. 2009'a kadar olan literatürde; JGHT gelişen Maffucci sendromlu dört olgu bulunmaktadır ve en yaşlı hasta 21 yaşındadır. Biz bu çalışmada Maffucci sendromu olup, JGHT gelişen en yaşlı hastayı sunacağız.

Anahtar kelimeler: encondromatozis, granuloza hücreli tumor, hemanjioma maffucci sendromu

Türk Jinekoloji ve Obstetrik Derneği Dergisi, (J Turk Soc Obstet Gynecol), 2012; Cilt: 9, Sayı: Ek 1, Sayfa: 36- 9

INTRODUCTION

Granulosa cell tumors are uncommon sex cord-stromal ovarian tumors up 3% of all ovarian malignancies. Their prognosis is generally good, local extend, and high survival rates seems, although late recurrences are common⁽¹⁾. Granulosa cell tumors can be divided into adult granulosa cell tumor and juvenile granulosa cell tumor (JGCT). Ollier disease is a rare disorder associated with the presence of multiple enchondromas

(intraosseous, usually benign cartilaginous tumors that develop in the metaphyseal ends of tubular bones). The condition in which multiple enchondromatosis is associated with soft tissue hemangiomas is known as Maffucci syndrome^(2,3). Both Maffucci syndrome and Ollier disease are nonfamilial congenital dysplasia of cartilage and sometimes the differential diagnosis between Maffucci syndrome and Ollier disease can be difficult because haemangiomas may be deep subcutaneous and asymptomatic. Some cases of Ollier

Address for Correspondence: Şafak Yılmaz Baran, Haseki Eğitim ve Araştırma Hastanesi, Kadın Hastalıkları ve Doğum Kliniği, İstanbul

Phone: + 90 (505) 583 08 56

e-mail: sayilmaz129@hotmail.com

Received: 02 September 2011, revised: 04 January 2012, accepted: 20 March 2012, online publication:

disease were changed to Maffucci syndrome later with the discovery of haemangioma. Maffucci syndrome shows female tendency and no mental or psychiatric abnormalities have been noted, about 200 cases have been described in the literature to date. The disease has a slow progression pattern throughout first two decades. Progression of the lesions usually stops by 30 years of age^(4,5).

An association of enchondromatosis and JGCT at a young age has been previously reported. Nine cases of Ollier disease⁽⁶⁻¹³⁾ and 4 cases of Maffucci syndrome⁽¹⁴⁻¹⁷⁾ with JGCT were reported in the literature until 2009 and the eldest patients with Maffucci syndrome and JGCT was 21 years old⁽¹⁵⁾.

We present a 25 year-old women with JGCT who was first qualified as Ollier disease at her 5 and 10 years later, with the association of hemangiomas, the diagnosis was changed as the Maffucci syndrome.

CASE

A -25- year old women presented with prolonged menstrual bleeding after two months amenorrhea period. Her past medical history was complicated with Maffucci's syndrome. Her disease was diagnosed as Ollier's syndrome because of her enchondromatosis at first decade of her life. Then she gradually developed a red nodule in size of a soybean on the hypothenar of her left hand, then she was observed to have similar nodules on the left hand and foot which gradually increased in size, which were defined as hemanjiomas with angiographic evaluation, and the her diagnosis was changed as Maffucci's syndrome (Figure 1). A recent physical examination showed that tumefaction and deformity were noted on the left hand. There were multiple, various sized bluish, movable, non tender nodules on the palm, dorsum, fingers of the left hand and medial malleolus, heel of the left foot.

Her gynecologic history was unremarkable. Gynecologic examination showed annular intact hymen and vaginal examination was not performed. Endometrial thickening was 19 mm, a 56x48 mm solid, regular shaped mass which placed in left adnexial area and mild ascites were seen in abdominal ultrasonography. Magnetic resonance imaging (MRI) study was indicated 47x56x72 mm solid mass with contrast uptake placed left ovarian area (Figure 2). Her

CA 125 level was 76 IU/ml, Inhibin-B level was >1000 pg/ml, estradiol level was 176 pg/ml.

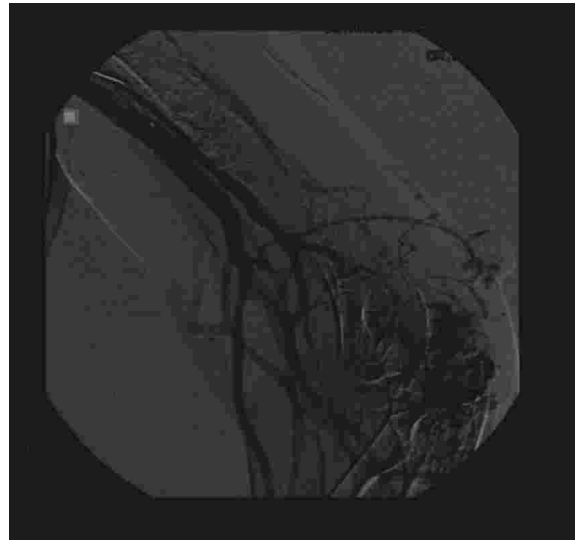


Figure 1:

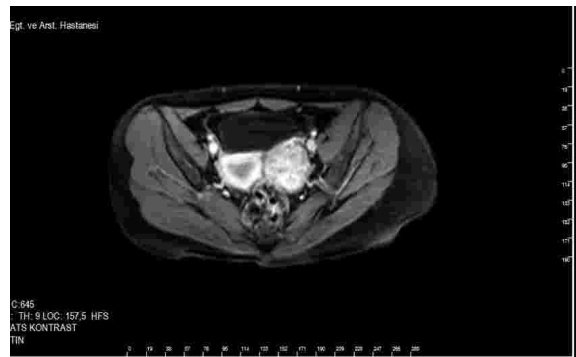


Figure 2:

Patients underwent to diagnostic laparoscopy and frozen section from the ovarian tumor biopsy. Laparoscopy revealed a 7x6 cm solid, soft, regular shaped, mobile left ovarian mass and 150 ml ascites and frozen section indicated granulosa cell tumor of the ovary. Operative approach was converted to laparotomy and cytologic sampling, left salpingoophorectomy, pelvic lymphadenectomy and omentectomy were performed same time.

Final pathologic examination showed left ovary have been placed by a soft, yellow-brown, lobulated solid mass in 7 cm diameter with irregular follicle-like structures. The round-to-oval tumor cells lining the follicles like structures showed big, anaplastic nuclei which lacked prominent nuclear grooves with vacuolated (luteinized) cytoplasm (Figure 3). Immunohistochemical stains showed positive intracytoplasmic staining with inhibin (Figure 4), callicrein and cytokeratin but negative staining with

EMA. No tumor invasion was seen at ovarian capsule, lenf nodes and omentum. The final diagnosis was stage 1 a juvenile granulosa cell tumor. Patient was warned about risk of concomitant endometrial hyperplasia, but she refused the endometrial sampling with defloration of hymen. Then gestagen treatment was added of six months (16-25 days of the cycle, Medroxyprogesteron acetate 10 mg per day). Further adjuvant treatment was not needed. No evidence of disease was detected at her 12th month follow up.

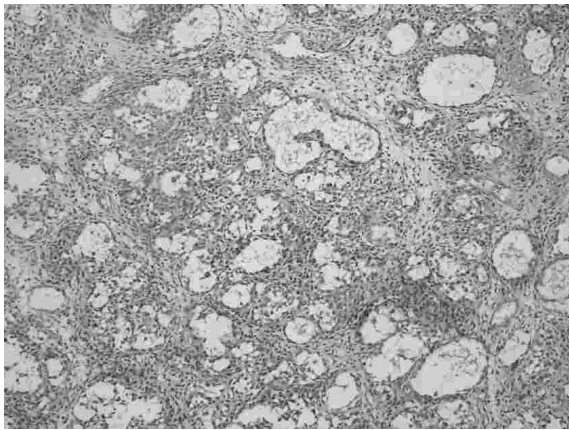


Figure 3:

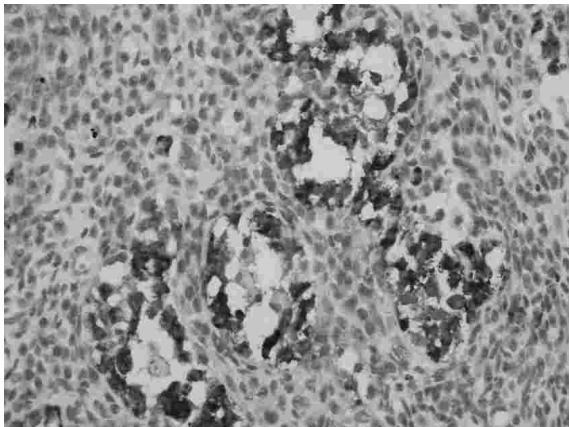


Figure 4:

DISCUSSION

Curative therapy for ovarian granulosa cell tumor is surgery. Unilateral salpingo-oophorectomy with preservation of the contralateral ovary and the uterus is now considered adequate surgical treatment for young patients with granulosa ovarian tumor, even in cases of advanced disease, because of the sensitivity of the tumor to chemotherapy, and no systematic ovarian biopsy need be performed where the

contralateral ovary is macroscopically normal.

Patients with Maffucci syndrome are susceptible to the development of malignant tumors, which may be malignant transformation of the pre existing lesions such as chondrosarcoma (more than 20 % of the patients developed chondrosarcoma), vascular sarcoma or fibrosarcoma. Some patients develop malignancies, unrelated to bone or soft tissue, such as ovarian sex cord stromal tumor, cerebral glioma, pancreatic adenocarcinoma and nasopharyngeal carcinoma⁽¹⁶⁾. Also some data showed that JGCTs were also associated with other mesodermal dysplastic conditions such as microcephaly, micrognathia, facial asymmetry, ambiguous genitalia and Potter's syndrome. It is noteworthy that; in the 13 reported cases and our case had that the ovarian tumors originated on the same side as the pronounced skeletal abnormality. So it is conceivable that JGCTs and mesodermal dysplasia relationship is more than coincidental.

Hormone (Estrogen) secreting ovarian stromal tumors may be resulted with endometrial hyperplasia. In our case, increased endometrial thickening was determined but endometrial biopsy could not be performed because of her virginity. Gestagen treatment was admitted for six months and follow-up the endometrium with ultrasonography was performed. At her 4 months follow-up, endometrial thickening was measured as 9 mm and she denied intermenstruel bleeding. In conclusion, in the light of literature and our experience, owing to a higher risk of granulosa cell tumors in women with Maffucci syndrome, these girls or women should be offered an annual gynecologic check-up and warned for signs of hyperestrogenism.

REFERENCES

1. Segal R, DePetrillo AD, Thomas G. Clinical review of adult granulosa cell tumors of the ovary. *Gynecol Oncol* 1995; 56: 338- 44.
2. Maffucci A. Di un caso di enchondroma ed angioma multiplo. *Movimento Medico Shirurico*. 1881; 399.
3. Sendur OF, Turan Y, Odabasi BB, Berkit IK. A case of Ollier disease with non-small cell lung cancer and review of the literature. *Rheumatol Int*. 2010 Mar;30(5): 699- 703.
4. Kuwahara RT, Skinner RB. Maffucci syndrome: A case report. *Cutis* 2002; 69: 21- 2.
5. Maffucci syndrome. *Intern Med*. 2010; 49(1): 85- 6. 2010 Jan

1. Amezyan T, Bassou D, Abouzahir A, Fatihi J, Akhaddar A, Mahassin F, Ghafir D, Ohayon V. A young woman with M Gell JS, Stannard MW, Ramnani DM, Bradshaw KD. Juvenile granulosa cell tumor in a 13-year-old girl with enchondromatosis (Ollier's disease): a case report. *J Pediatr Adolesc Gynecol* 1998; 11: 147- 50.
7. Asirvatham R, Rooney RJ, Watts HG. Ollier's disease with secondary chondrosarcoma associated with ovarian tumour. *Int Orthop* 1991; 15: 393- 5.
8. Le Gall C, Bouvier R, Chappuis JP, Hermier M. Ollier's disease and juvenile ovarian granulosa tumor. *Arch Fr Pediatr* 1991; 48: 115- 8.
9. Velasco-Oses A, Alonso-Alvaro A, Blanco-Pozo A, Nogales FF Jr. Ollier's disease associated with ovarian juvenile granulosa cell tumors. *Cancer* 1988; 62: 222- 5.
10. Schwartz HS, Zimmerman NB, Simon MA, Wroble RR, Millar EA, Bonfiglio M. The malignant potential of enchondromatosis. *J Bone Joint Surg* 1987; 69: 269- 74.
11. Vaz R, Turner C. Ollier disease (enchondromatosis) associated with ovarian juvenile granulosa cell tumor and precocious pseudopuberty. *J Pediatrics* 1986; 108: 945- 7.
12. Pounder DJ, Iyer PV, Davy MLJ. Bilateral juvenile granulose cell tumours associated with skeletal enchondromas. *Aust NZ J Obstet Gynaecol* 1985; 25: 123- 6.
13. Tamimi HK, Bolen JW. Enchondromatosis (Ollier's disease) and ovarian juvenile granulosa cell tumour. A case report and review of the literature. *Cancer* 1984; 53: 1605- 8.
14. Lewis RJ, Ketcham AS. Maffucci's syndrome: functional and neoplastic significance. Case report and review of the literature. *J Bone Joint Surg* 1973; 55: 1465- 79.
15. Yuan J, Lin X, Xu J, Zhu J, Zheng WL. Ovarian juvenile granulosa cell tumor associated with Maffucci's syndrome: case report. *Chinese Med J* 2004; 117: 1592- 4.
16. Hachi H, Othmany A, Douayri A, Bouchikhi C, Tijami F, Laâlou L, et al. Association of ovarian juvenile granulosa cell tumor with Maffucci's syndrome. *Gynecol Obstet Fertil.* 2002; 30: 692- 5.
17. Tanaka Y, Sasaki Y, Nishihira H, Izawa T, Nishi T. Ovarian juvenile granulosa cell tumor associated with Maffucci's syndrome. *Am J Clin Pathol* 1992; 97: 523- 7.