

MINILAPAROSCOPIC TOTAL HYSTERECTOMY

Fatih SENDAG, Ali AKDEMİR, Enes TAYLAN, Kemal OZTEKİN

Department of Obstetrics and Gynecology, Ege University Faculty of Medicine, Izmir

SUMMARY

Hysterectomy is one of the most common gynecological procedures in the world and because of well-known many advantages such as shorter hospital stay and faster recovery, decreased postoperative pain and better cosmetic results laparoscopic approach is being widely performed. One of these current procedures is minilaparoscopic total hysterectomy. To the best of our knowledge, this case is the first minilaparoscopic total hysterectomy case in our country performed to a patient diagnosed with uterin fibroid. In this case report we evaluated the technique, advantages and disadvantages of the minilaparoscopic hysterectomy.

Key words: hysterectomy, laparoscopy, minilaparoscopy

Journal of Turkish Society of Obstetrics and Gynecology, (J Turk Soc Obstet Gynecol), 2014; Vol: 11, Issue: Pages:

MİNİ LAPAROSKOPİK TOTAL HİSTEREKTOMİ

ÖZET

Histerektomi dünyada en çok yapılan jinekolojik operasyonlardan biridir. Günümüzde kısa hastanede yatış süresi ve hızlı iyileşme, daha az postoperatif ağrı ve daha iyi kozmetik sonuçlar gibi bilinen pek çok avantajı nedeniyle laparoskopik yaklaşım giderek yaygınlaşmaktadır. Bu güncel tekniklerden biri ise minilaparoskopik histerektomi operasyonudur. Bildiğimiz kadarıyla ülkemizde ilk kez kliniğimizde minilaparoskopik yaklaşımla uterin myom nedeniyle yapılan bir total laparoskopik histerektomi operasyon tekniği, avantajları ve dezavantajları açısından değerlendirilmiştir.

Anahtar kelimeler: histerektomi, laparoskopi, minilaparoskopi

Türk Jinekoloji ve Obstetrik Derneği Dergisi, (J Turk Soc Obstet Gynecol), 2014; Cilt: 11, Sayı: Sayfa:

INTRODUCTION

Hysterectomy is one of the most commonly performed gynecological operations in our country as well as in the world. Nowadays, especially in hysterectomy operations due to benign causes, a transition from open surgery to laparoscopic surgery is noticeable. Among the main reasons for this, shorter length of hospital stay, less postoperative pain and an earlier return to daily life, less bleeding, and better cosmetic results can be mentioned⁽¹⁻³⁾. Laparoscopic surgery can be applied with different procedures, such as single-port and minilaparoscopy techniques, besides the standard surgical procedure. The aim of these techniques is to reduce tissue trauma and decrease the risk of port-site hernia^(4,5). In minilaparoscopy technique, the standard diameter of 5 mm of trocar is decreased to 3 mm and the number of trocars used, depending on the surgeon's experience, is minimized, as well. Although the decrease in the diameter of trocars would provide advantages in regard to minimally invasive procedure, it does not cause any disadvantages to the surgeon^(6,7).

To the best of our knowledge, it is the first case in our country that total hysterectomy with minilaparoscopy was performed. We present here our case and the operation technique we have used and we intend to evaluate our perioperative and postoperative results.

CASE

A 47 year-old female patient was referred to our clinic with complain of menometrorrhagia resistant to medical treatment. Transvaginal ultrasound examination revealed an intramural leiomyoma on the anterior wall of the uterus, measuring 25 x 30 mm in size and compressing endometrium. Medical history of our patient included Diabetes Mellitus and hypertension and 2 cesarean deliveries. Furthermore, she was scheduled for a hysterectomy and bilateral salpingo-oophorectomy with mini laparoscopy technique. The patient's BMI was 25.2, preoperative hemoglobin and hematocrit values were, respectively, 9.3gr/dl and 28.3%.

TECHNIQUE

Under intrathecal general anesthesia, and in dorso lithotomy position, pneumoperitoneum was established via the insertion of a Veress needle through umbilicus into the abdomen. Then, 5 mm laparoscopic trocar was inserted through umbilicus, through which optical system was placed into the abdominal cavity. Under optical inspection, a total of 3 trocars (Karl Storz Endoscope - 3 mm trocar set) were directly placed into the abdomen at bilateral lower quadrants and at the left side of the level of the umbilicus, without any skin incision. Similar to the classic laparoscopic total hysterectomy and bilateral salpingo-oophorectomy technique, bilateral ureters were dissected and traced, and then bilateral infundibulopelvic ligaments, uterine arteries, cardinal ligaments were cauterized with classic bipolar electro-surgical forceps and cut with laparoscopic scissors. By using monopolar hook over sacrouterine ligaments, anterior and posterior colpotomy were performed and uterus and ovaries were removed in total. Vaginal cuff was separately sutured with number 0 Vicryl intracorporeally (Figure 1). Total uterine weight was measured as 170 g. The operation lasted for a total of 2 hours and 20 minutes and intraoperative blood loss was measured as about 12 ml. Postoperative control hemoglobin and hematocrit levels were 9 g/dl and 26.7%, respectively. No blood transfusion was required and no intraoperative or postoperative complications such as fever, deep vein thrombosis, and infection developed. The patient was discharged with full recovery 24 hours after the operation.

Figure 1a: Ureter dissection (Left).

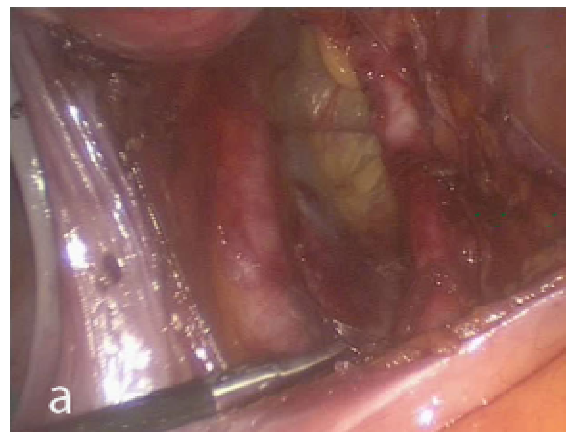
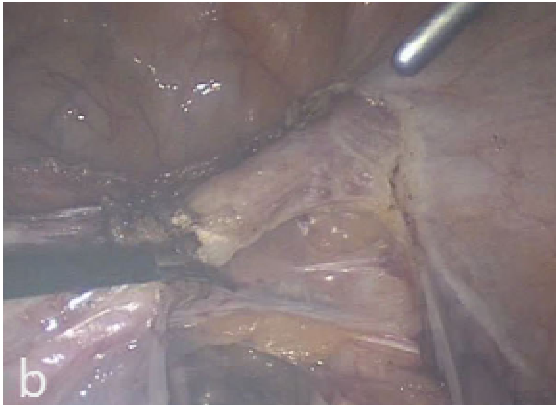
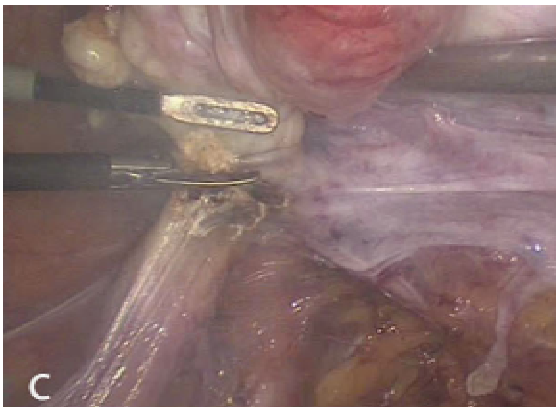
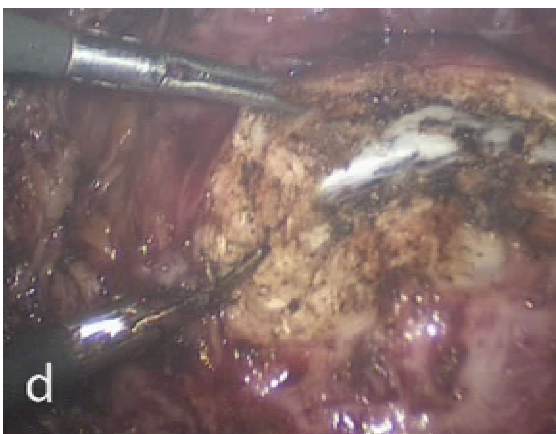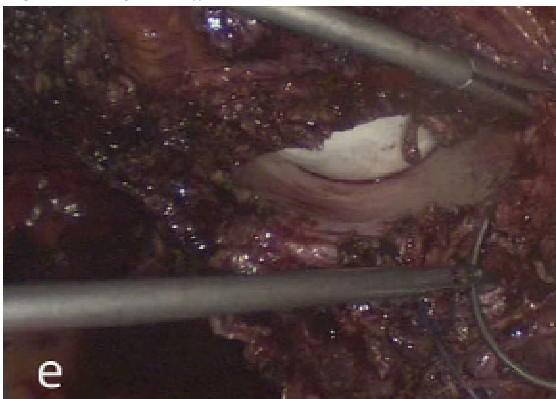
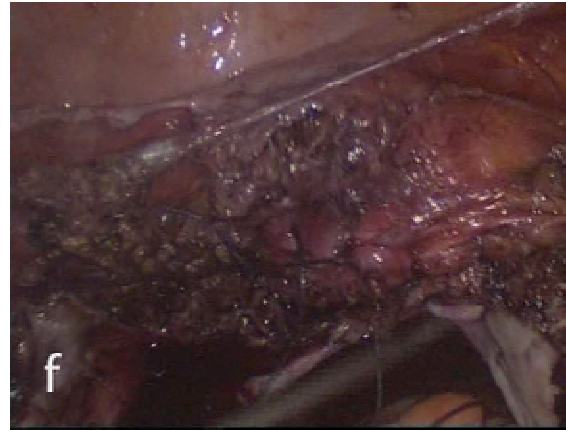


Figure 1b: Cutting Round ligament (Right).**Figure 1c:** Cutting Infundibulopelvic ligament (Left).**Figure 1d:** Colpotomy.**Figure 1e:** Vaginal Cuff Saturation.**Figure 1f:** Vaginal Cuff after suturation.

DISCUSSION

Minilaparoscopic surgery technique has evolved especially in recent years to improve minimally invasive operations even further to less invasive procedures. In this technique, the two main objectives are defined as to reduce the trauma due to port placements as much as possible (by reducing the diameter of the trocar), and reduce total number of port placements. Although various conflicting studies are available in the literature, Ghezzi et al.⁽⁶⁻⁸⁾ have examined mini-laparoscopy technique with regard to hysterectomy and salpingo-oophorectomy and have demonstrated many advantages in various aspects. In their study, Fanfani et al.⁽⁹⁾ have demonstrated that a decrease in the number and the diameter of ports can significantly reduce postoperative pain and analgesic requirement. However, they have stated that no significant difference was determined between minilaparoscopy and standard laparoscopic surgery with respect to postoperative recovery period and duration hospital stay. Some researchers have reported no difference between mini-laparoscopic hysterectomy and conventional laparoscopic surgery in terms of duration of operation, whereas some others have remarked that operation time can be longer for mini-laparoscopic hysterectomy. In our case, the operation lasted for 140 minute, which is longer than conventional laparoscopic hysterectomy. Among the reasons for that, we may mention that minilaparoscopy technique lacks the power of vascular sealing and cutting instruments, which function with advanced bipolar technology, particularly used in laparoscopic hysterectomies. In minilaparoscopic hysterectomy, conventional bipolar forceps provide vascular

coagulation and subsequently the coagulated section is cut by laparoscopic scissors and hysterectomy is carried out. For this reason, the overall operation time is observed to increase to a certain extent in the minilaparoscopic hysterectomy.

Regarding cosmetic results of mini-laparoscopic hysterectomy, limited data is available in the literature indicating its advantages compared to classic laparoscopic approach.

Although this is a case report, it is worth mentioning that our patient was satisfied with the postoperative cosmetic results.

Minilaparoscopic surgery is a new promising technique, and as the surgeons gain experience and conduct many more studies, its advantages and disadvantages are expected to be largely revealed and clarified in the coming years.

REFERENCES

1. Kluivers KB, Johnson NP, Chien P, Vierhout ME, Bongers M, Mol BW. Comparison of laparoscopic and abdominal hysterectomy in terms of quality of life: a systematic review. *Eur J Obstet Gynecol Reprod Biol* 2008;136(1):3-8.
2. Johnson N, Barlow D, Lethaby A, Tavender E, Curr E, Garry R. Surgical approach to hysterectomy for benign gynaecological disease. *Cochrane Database Syst Rev* 2006;(2):CD003677.
3. Johnson N, Barlow D, Lethaby A, Tavender E, Curr L, Garry R. Methods of hysterectomy: systematic review and meta-analysis of randomised controlled trials. *BMJ* 2005;330:1478.
4. Pelosi MA, Pelosi MA 3rd. Laparoscopic supracervical hysterectomy using a single-umbilical puncture (mini-laparoscopy). *J Reprod Med* 1992;37(9):777-84.
5. Hosono S, Osaka H. Minilaparoscopic versus conventional laparoscopic cholecystectomy: a meta-analysis of randomized controlled trials. *J Laparoendosc Adv Surg Tech A* 2007;17(2):191-9.
6. Ghezzi F, Cromi A, Siesto G, Uccella S, Boni L, Serati M et al. Minilaparoscopic versus conventional laparoscopic hysterectomy: results of a randomized trial. *J Minim Invasive Gynecol* 2011;18(4):455-61.
7. Ghezzi F, Cromi A, Colombo G, Uccella S, Bergamini V, Serati M, et al. Minimizing ancillary ports size in gynecologic laparoscopy: a randomized trial. *J Minim Invasive Gynecol* 2005;12(6):480-5.
8. Ghezzi F, Uccella S, Casarin J, Cromi A. Microlaparoscopic bilateral adnexectomy: A 3-mm umbilical port and a pair of 2-mm ancillary trocars served as conduits. *Am J Obstet Gynecol* 2013.pii: S0002-9378(13)00840-5.
9. Fanfani F, Fagotti A, Rossitto C, Gagliardi ML, Ercoli A, Gallotta V, et al. Laparoscopic, minilaparoscopic and single-port hysterectomy: perioperative outcomes. *Surg Endosc* 2012;26(12):3592-6.