

RUPTURED SPONTANEOUS HETEROTROPIC PREGNANCY

Ozlem ERTEN, Hulya DEDE, Volkan KURTARAN, Bulent YIRCI, Orhan GELISEN, Umit GOKTOLGA

Etilik Zubeyde Hanım Teaching and Research Hospital; Obstetrics and Gynecology, Ankara, Turkey

SUMMARY

Introduction: Heterotopic pregnancy is a condition of the co-existence of different gestations. With the widespread use of assisted reproductive techniques its incidence is increasing.

Case: A 30-year-old woman, gravida 2 para 1, with spontaneous pregnancy at 7 weeks and 6 days gestational age according to the last menstruation, applied to our emergency department with abdominal pain and vaginal bleeding. The medical history includes a caesarean surgery, intrauterine device (IUD) usage and a procedure of intrauterine insemination (IUI) following the ovulation induction by clomiphene citrate resulting with unsuccessful pregnancy, he patient who got pregnant spontaneously and had a single five-weeks intrauterine pregnancy at the application. The patient was diagnosed with ruptured heterotopic pregnancy and treated with laparoscopic salpingectomy. Upon the consent and request of the family, intrauterine pregnancy was evacuated. No complications occurred in the postoperative period. Pathological examination of evacuation material was reported consistent with heterotopic pregnancy.

Conclusion: Regardless of the presence of any risk factors in pregnant women diagnosed with intrauterine pregnancy, adnexa and pelvic structures should be examined in detail. The detection of intrauterine pregnancy in the ultrasonography does not eliminate heterotopic pregnancy. Early diagnosis before development of complications has a life saving importance.

Key words: heterotopic pregnancy, intrauterine pregnancy, ultrasound

Journal of Turkish Society of Obstetrics and Gynecology, (J Turk Soc Obstet Gynecol), 2012; Vol: 9, Issue: 4, Pages: 227- 30

RÜPTÜRE SPONTAN HETEROTOPIK GEBELİK

ÖZET

Giriş: Heterotopik gebelik farklı gestasyonların birlikte bulunması durumudur. Yardımcı üreme tekniklerinin yaygın kullanımıyla günümüzde insidansı artmaktadır.

Olgu: 30 yaşında gravida 2 para 1, son adet tarihine göre 7 haftalık spontan gebeliği olan hasta karın ağrısı ve vajinal kanama şikayetiyle acil servisimize başvurdu. Hastanın özgeçmişinde; geçirilmiş sezaryen operasyonu, rahim içi araç (RİA) kullanımı ve klomifen sitrat ile ovulasyon indüksiyonu sonrasında, gebelik elde edilemeyen intrauterin inseminasyon (IUI) uygulaması vardı. İki yıl sonra spontan gebe kalan ve başvuruda beş haftalık intrauterin tek canlı gebeliği olan hasta, rüptüre heterotopik gebelik tanısı alarak, laparoskopik salpenjektomi ile tedavi edildi. Ailenin onam ve talebi üzerine intrauterin gebelik tahliye edildi. Postoperatif dönemde problem yaşanmadı. Tahliye materyalinin patolojik incelemesi heterotopik gebelikle uyumlu rapor edildi.

Sonuç: İntrauterin gebelik tanısı alan her gebede risk faktörü olsun veya olmasın adneklerin ve pelvik yapıların detaylı incelenmesi gerekmektedir. İntrauterin gebeliğin ultrasonda izlenmesi heterotopik gebeliği ekarte ettirmektedir. Komplikasyonlar gelişmeden tanı koyabilmek hayat kurtarıcı öneme sahiptir.

Anahtar kelimeler: heterotopik gebelik, intrauterin gebelik, ultrasonografi

Türk Jinekoloji ve Obstetrik Derneği Dergisi, (J Turk Soc Obstet Gynecol), 2012; Cilt: 9, Sayı: 4, Sayfa: 227- 30

Address for Correspondence: Özlem Erten, Etilik Zübeyde Hanım Kadın Hastalıkları Eğitim ve Araştırma Hastanesi, Etilik Keçiören 06010, Ankara
Phone: +90 (505) 585 61 93
e-mail: odle822002@yahoo.com

Received: 09 April 2011, revised: 18 April 2012, accepted: 14 June 2012, online publication: 15 June 2012

INTRODUCTION

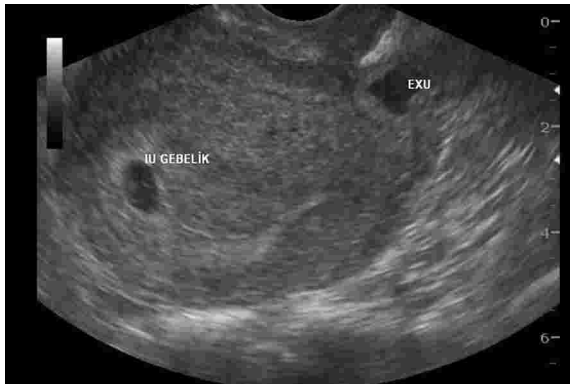Heterotopic pregnancy is the condition of having two or more pregnancy focuses simultaneously. Whereas the incidence with spontaneous conception is 1/30000, this ratio can reach up to 1/100 with assisted reproductive techniques^(1,2). Hence, it means that from now on we will face more heterotopic pregnancy cases.

A spontaneous heterotopic pregnancy case with tubal rupture development has been presented. The importance of clinical and ultrasonographic evaluation pelvic and adnexal structures in all pregnancy applications during their early weeks has been emphasized.

Case

30 year old gravida 2 para 1 patient applied to the emergency clinic of our hospital with abdominopelvic pain and miscarriage suspicion. The patient who was 7 weeks spontaneous pregnant according to the last menstrual period date had in her history a c-section operation five years ago, RIA usage of two years and a failed conception attempt two years ago with clomiphene citrate induction and IUI application. The patient had defense and rebound sensitivity during the abdominal examination and the collum movements were determined to be severely pained during the gynecological examination. There was also minor vaginal bleeding in the form of staining.

In the ultrasonographic evaluation, there was a 5 week fetus with cardiac activity and fluid collection in the uterine cavity and the formation of a heterogeneous echo in the right adnexal area, however widespread free fluid collection inside the paraovarian region, Douglas cavity and abdomen (Picture 1).

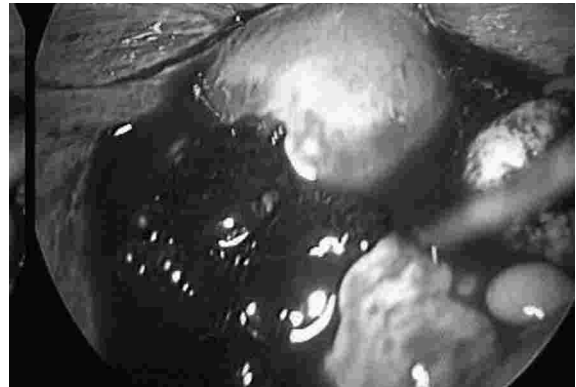


Picture 1: Ultrasound image of heterotopic pregnancy.

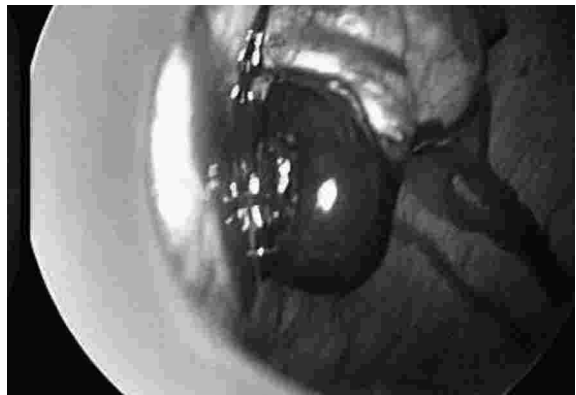
The patient was hospitalized with tubal rupture with a prediagnosis of heterotopic pregnancy. Arterial blood pressure was 120/80 mm/Hg at service acceptance and

pulse was 84/min. Whereas during the emergency service application hemoglobin (Hb) level was 12,3 gr/dl, white blood cell and platelet count were normal, Hb:10,8 gr/dl evaluation was made during service follow-up and the patient was immediately taken into laparoscopic surgery.

During intraoperative observation, there was about 1000 cc hemorrhagic fluid and active bleeding inside the abdomen (Picture 2). Ectopic pregnancy material was observed with a size of about 4x4 cm and was ruptured from the ampullar part of right adnexal region (Picture 3). Right salpingectomy, abdomen cleansing and bleeding control was made (Picture 4). With the consent and request of the family, intrauterine pregnancy was evacuated by manual vacuum aspiration method after the laparoscopy. There were no intraoperative or postoperative complications. Hemoglobin value on the first postoperative day was 10,0 gr/dl and the patient was discharged with an overall good condition. There were no problems in the controls after discharge. The patient was called for regular postoperative controls and her hemoglobin value was 13,2 gr/dl however the ultrasonographic and gynecologic examination were evaluated normal. She was informed in detail regarding the possible obstetric and gynecologic situations that might arise in her next pregnancy.

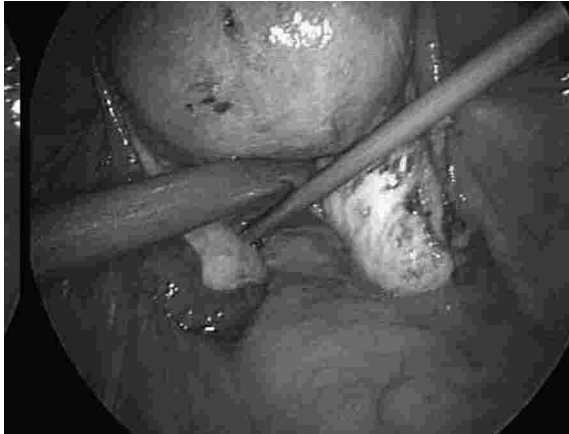

Picture 2: Widespread hemorrhage in the abdomen.



Picture 3: Ectopic pregnancy material.

The histopathology of the sample recorded as salpingectomy was reported as tubal pregnancy material; the histopathology of the sample recorded as curettage material; chorionic element and decidua.



Picture 4: Image of the abdomen after salpingectomy.

DISCUSSION

Heterotopic pregnancy is the condition of having different gestations simultaneously. Heterotopic pregnancy may be tubal, ovarian, abdominal, cervical or cornual located. It can occur as more than one ectopic pregnancy focuses simultaneously whereas simultaneous intrauterine pregnancy is also possible (3,4).

Risk factors are the same as those of ectopic pregnancy. Past surgeries, ectopic pregnancy history in past pregnancies, pelvic inflammatory diseases, use of IUD, ovulation induction history are some of the risk factors (5). The rate of ectopic pregnancy cases has increased today due to sexually transmitted diseases, sexual relations with multiple partners at an early age and assisted reproductive techniques (5). In the studies carried out it has been determined that past surgical histories are the most common (5). However, heterotopic pregnancy can also occur without any risk factors (6).

70% of heterotopic pregnancies are diagnosed during the 5th and 8th weeks of pregnancies, 20 % during the 9th and 10th weeks and 10 % during the 11th week and beyond (2).

According to whether there is clinical rupture or not, it can range from asymptomatic situation to shock table (7). Vaginal bleeding and abdominopelvic pain accompanied by delayed menstruation should remind one of ectopic pregnancy (8). During the emergency service application of the case, first abortus imminens, abortus insipiens, incomplete abortion, hemorrhagic

corpus luteum cyst have been considered in differential diagnosis, however there was abdominopelvic sensitivity, heterogeneous formation in the right adnex and the intrauterine live fetus with fluid and coagulum led us to consider heterotopic pregnancy. Transvaginal ultrasonographic evaluation is indispensable in the case of heterotopic pregnancy (9). Heterotopic pregnancy should be considered in cases of pelvic free fluid and pain. Whereas other supporting diagnosis methods of β hCG and progesteron measurement are helpful in diagnosing ectopic pregnancy but they are not meaningful to use for heterotopic pregnancy since it may arise due to simultaneous intrauterine pregnancy.

Laparoscopy or laparotomy are preferred surgical methods according to the clinical status of the patient.

Laparoscopic surgery has many advantages in heterotopic pregnancy such as the fact that it has a minimal effect on the uterus of the pregnant patient, that there is a minimum blood loss, that it decreases postoperative abortus risk, the decrease of thromboembolic complication risks due to early recovery and mobilization, less requirement of potent analgesics during the postoperative period pain control, that there is no abdominal incision and that the hospitalization period is short (10). In addition, with the development in laparoscopy and the increase in relevant experience, treatment of cases such as tuba rupture which were previously treated using laparotomy has become more secure with the use of laparoscopy (11).

Laparoscopy was preferred since the vital findings of our case were stable, the laparoscopy equipment and environment were sufficient and could rapidly be prepared and the fact that our clinic had doctors and personnel who could perform this operation in a very short amount of time.

The ectopic component of heterotopic pregnancy is generally ampulla located. Surgical procedure ranges from salpingostomy in the conservative approach to salpingectomy in cases for which radical extirpation is aimed (10). However, since during postoperative period follow-ups high levels of β hCG raise doubts as to whether they are due to intrauterine pregnancy or incomplete removed intratubal conception material, salpingectomy is preferred instead of salpingostomy (10). Even though the continuation of intrauterine pregnancy was not considered in our case, salpingectomy was applied since the patient had more than one risk factor along with an

ectopic pregnancy history with a %5-8(12) possibility of ectopic pregnancy that can repeat in the same tuba or that can persist.

The general approach in heterotopic pregnancies is to preserve the intrauterine pregnancy. Proper method to continue or terminate the intrauterine pregnancy can be planned following the informed consent of the family. If the continuation of intrauterine pregnancy is planned, agents such as methotrexate, prostaglandins and RU-486 should not be used; local potassium chloride or hyperosmolar glucose injection⁽¹³⁾ can be used in case the tube is intact^(6,14).

Result

In this case, the necessity of ultrasonographic pelvic and adnexal evaluation is emphasized due to the increase of heterotopic pregnancy incidence. Early diagnosis is a life saver for the prevention of complications in heterotopic pregnancy complications.

REFERENCES

1. Bright DA, Craupp FB: Heterotopic pregnancy: a re-evaluation. *J Am Board Fam Pract* 1990; 3: 125- 8.
2. TalJ, HaddadS, GordonN, Timor-TritschI. Heterotopic pregnancy after ovulation induction and assisted reproductive technologies: a literature review from 1971 to 1993. *Fertil Steril* 1996; 66: 112.
3. Habana A, Dokras A, Giraldo JL, Jones EE. Cornual heterotopic pregnancy: contemporary management options. *Am J Obstet Gynecol* 2000; 182: 1264- 70.
4. Wang PH, Chao HT, Tseng JY, Yang TS, Chang SP, Yuan CC. Laparoscopic surgery for heterotopic pregnancies: a case report and a brief review. *Eur J Obstet Gynecol Reprod Biol* 1998; 80: 267- 71.
5. Yenen M.C, Dede M, Göktoğa Ü, Küçük T, Alanbay İ, Pabuçcu R. Ektopik gebelikte risk faktörleri. *Gülhane Tıp Dergisi* 2003; 45: 244- 8.
6. Tandon R, Goel P, Kumar Saha P, Devi L. Spontaneous heterotopic pregnancy with tubal rupture: a case report and review of the literature. *Journal of Medical Case Reports* 2009; 3: 8153.
7. Birkhahn RH, Gaeta TJ, Van Deusen SK, et al: The ability of traditional vital signs and shock index to identify ruptured ectopic pregnancy. *Am J Obstet Gynecol* 2003; 189: 1293- 6.
8. Barnhart, KT. Ectopic Pregnancy. *N Engl J Med* 2009; 361: 379- 87.
9. Lavanya R, Deepika K, Patil M. Successful pregnancy following medical management of heterotopic pregnancy. *J Hum Reprod Sci.* 2009; 2(1):35- 40.
10. Pschera H, Kandemir S. Laparoscopic treatment of heterotopic pregnancies: Benefits, complications and safety aspects. *J Turkish German Gynecol Assoc.* 2005; 6 (2): 90- 4.
11. Sagiv R, Debby A, Sadan O, et al: Laparoscopic surgery for extrauterine pregnancy in hemodynamically unstable patients. *J Am Assoc Gynecol Laparosc* 2001; 8: 529- 32.
12. Rulin MC: Is salpingostomy the surgical treatment of choice for unruptured tubal pregnancy? *Obstet Gynecol* 1995; 86: 1010- 3.
13. Gjelland K, Hordnes K, Tjugum J, et al: Treatment of ectopic pregnancy by local injection of hypertonic glucose: a randomized trial comparing administration guided by transvaginal ultrasound or laparoscopy. *Acta Obstet Gynecol Scand* 1995; 74: 629- 34.
14. Scheiber MD, Cedars MI. Successful non-surgical management of a heterotopic abdominal pregnancy following embryo transfer with cryopreserve-thawed embryos. *Hum Reprod* 1999; 14: 1375- 7.