

## CERVICAL ECTOPIC PREGNANCY: THREE CASE REPORTS

Elcin İşlek SECEN, Huseyin Levent KESKIN, Ayse Filiz AVSAR

Department of Obstetrics and Gynecology, Ataturk Education and Research Hospital, Ankara, Turkey

### SUMMARY

*Cervical ectopic pregnancy, a rare situation that constitutes %0,2 of all ectopic pregnancies and initiative high maternal mortality. Early diagnosis and appropriate treatment in this patients is life saving and helps to preserve fertility .This paper describes diagnosis, follow up and conservative treatment of three cervical ectopic pregnancy cases.*

**Key words:** cervical ectopic pregnancy, treatment

*Journal of Turkish Society of Obstetrics and Gynecology, (J Turk Soc Obstet Gynecol), 2012; Vol: 9 Issue: 2 Pages: 124- 7*

### SERVİKAL EKTOPIK GEBELİK: ÜÇ OLGU SUNUMU

#### ÖZET

*Servikal ektopik gebelik, ektopik gebeliklerin %0.2'sini oluşturan ve yüksek maternal mortalite ile seyreden nadir görülen bir durumdur. Erken tanı ve uygun tedavi şekli bu hastalarda hem hayat kurtarıcı hem de fertilitiyi koruyucu olabilmektedir. Burada üç servikal ektopik gebelik olgusunun tanısının konulması, takipleri ve uygulanan konservatif tedaviler üzerinde durulmuştur.*

**Anahtar kelimeler:** servikal ektopik gebelik, tedavi

*Türk Jinekoloji ve Obstetrik Derneği Dergisi, (J Turk Soc Obstet Gynecol), 2012; Cilt: 9 Sayı: 2 Sayfa: 124- 7*

### INTRODUCTION

Ectopic pregnancy rate is 1.97% in all pregnancies and is one of the major causes of maternal mortality and morbidity. In this pregnancy, the most common type is tubal (95%) and cervical pregnancies occur in 0.2% of ectopic pregnancies<sup>(1)</sup>. The incidence of cervical pregnancy occurs in 1 in every 2500 to 1 in every 10000 pregnancies. The early diagnosis and treatment of cervical pregnancy is life-saving in most of the time and also important for fertility preservation. In order to protect the fertility in many conservative treatment options are also available. In this study, three cervical ectopic pregnancy cases are reported who treated with systemic methotrexate and cervical curettage.

### CASE 1

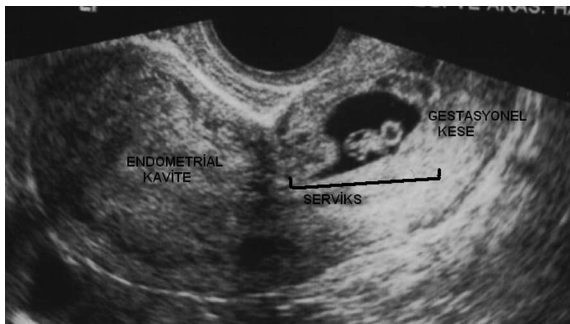
A 26-year-old patient (A.Ç), was admitted with complaints of vaginal bleeding continued approximately for 15 days. 2 pregnancies had ended with the story of obstetric cesarean delivery. According to the last menstrual period, patient had a delay of approximately 7-8 days. One week ago the case's medical records in transvaginal ultrasonography (TVUSG), intrauterine fetal heartbeat was irregular, gestational sac was identified and was followed with the diagnosis of abortion imminence. The cervix was hypertrophic and dark colored in the speculum examination. In the gestational sac (9.5 mm diameter, 5 weeks), which was located in the cervix, fetal heartbeat monitored in

---

**Address for Correspondence:** Elçin İşlek Seçen. Mutluköy mah. Ağaçseven sok. Elit apt. no: 7 Ümitköy, Ankara  
Phone: + 90 (506) 763 79 03  
e-mail: elcinislek@hotmail.com

Received: 21 December 2010, revised: 12 May 2011, accepted: 13 June 2011, online publication: 21 June 2011

accordance with the embryo (CRL: 3.3 mm, 6 weeks) was observed. Endometrial thickness was approximately 4 mm and uterine cavity was empty (Figure 1). On this finding, previously identified intrauterine gestational sac, later shifted to the area over the cervical internal os and invaded the front wall of cervix was considered. Cases  $\beta$ -hCG value was over 5000 mIU / ml. Full blood count and biochemical values were normal. Patients diagnosed with cervical pregnancy with vaginal bleeding, the material was evacuated with cervical curettage. Then 18F Foley catheter placed in the cervical canal and the bleeding was controlled. The same day, 50 mg/m<sup>2</sup> dose (80 mg) methotrexate was applied. After the methotrexate in 2nd day the value of  $\beta$ -hCG 3966 mIU / ml were measured. Foley catheter which was placed in the cervical canal was removed. 4<sup>th</sup> day, the value of  $\beta$ -hCG was 2346 mIU / ml and patient was discharged without vaginal bleeding. The pathology report was interpreted as the necrotic decidua and placental tissue.  $\beta$ -hCG level was 1072 at the end of Week 1 of the patient. Month 1, the control of  $\beta$ -hCG level was found negative and the patient had normal gynecological examination and TVUSG.

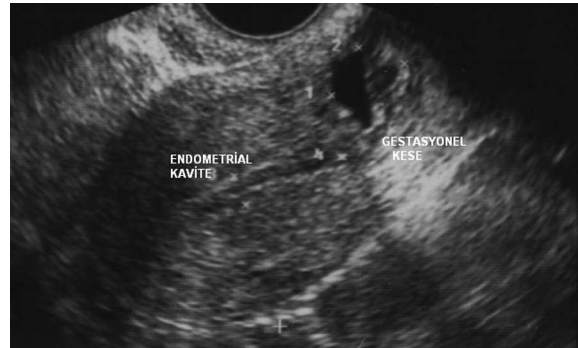

**Figure 1:** TVUSG image (the gestational sac was invaded the front wall of the cervix and the endometrial cavity was empty).

### CASE 2

A 34-year-old (N.S), G: 4, P: 2, D & C: 1, was admitted with spotting vaginal bleeding and pelvic pain which was continued for 2 days. Patient with a history of previous cesarean section 5 years ago in TVUSG the gestational sac which was separated from the cervical canal and invaded the cervix front wall was observed. Endometrial thickness was measured as 5.1 mm (Figure 2).  $\beta$ -hCG value of the case was 5514 mIU / ml and the progesterone value was 8.1 ng / ml.  $\beta$ -hCG value of the case 2 days before was 4253 mIU / ml.

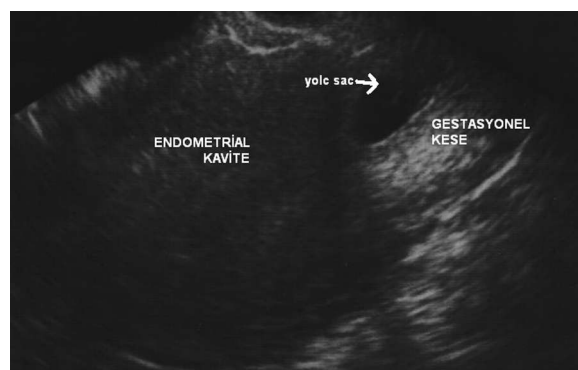Methotrexate 50 mg/m<sup>2</sup> was applied the patient who had normal laboratory values. In the follow up the  $\beta$ -hCG value regressed and no complication was detected.



**Figure 2:** TVUSG image (cervical internal os closed, the gestational sac was invaded the front wall of the cervix and the endometrial cavity was empty).

### CASE 3

A 41-year-old (A.Ö), G: 3, P: 1, D & C: 1, who had a history of cesarean section 9 years ago, was admitted with complaints of latency menstruation of 10 days. In the gynecological examination of the patient revealed no pathological findings and in TVUSG gestational sac which was located on the cervix and had yolk sac about 3 mm in diameter, were observed. The embryonic pole was not observed (figure 3). The  $\beta$ -hCG value was 19263 mIU / ml. With normal Laboratory values the cervical curettage was performed. 3rd day after curettage, the  $\beta$ -hCG value was 2208 mIU / ml, the patient who had normal ultrasound findings and no vaginal bleeding was discharged. 7<sup>th</sup> day the value of  $\beta$ -hCG was 413 mIU / ml. decidual and placental tissues was interpreted as the result of pathology.



**Figure 3:** TVUSG image (the endometrial cavity was empty and the gestational sac located in the cervical canal).

## DISCUSSION

Cervical pregnancy is a life-threatening and a rare type of ectopic pregnancy. Clinical diagnosis of cervical pregnancy is difficult. In general, the diagnosis made incidentally during a routine ultrasound or preliminary diagnosis of after incomplete abortion with curettage is placed. The most common symptom of cervical pregnancy is vaginal bleeding (91%) and pelvic pain (28%). Early weeks of asymptomatic cervical pregnancies (6%) is detected during a routine ultrasound (2). In etiology, previous dilatation and curettage (the most common cause of 68%), cesarean birth, in vitro fertilization and pregnancy, and had a history of intrauterine device use. These features should be a warning in cervical pregnancy. All of our cases with a history of previous cesarean section and two of these cases had a history of D & C. Diagnosed by ultrasonography, presence of gestational sac and trophoblastic invasion which are located in endocervix (2). During TVUSG to our cases, the gestational sacs were invaded the front wall of the cervix, a closed cervical os and the endometrial cavity viewed as a blank. In addition, in one cases of cervical pregnancy, asymptomatic patient who presented with delay in menstruation has been identified during TVUSG.

The management of cervical pregnancy, the amount of bleeding, gestational age, gestational sac location (the uterine artery proximal to the cervical canal is important for the amount of bleeding), the depth of trophoblast invasion and  $\beta$ -hCG values are important. Approach may be conservative or radical treatment of cervical pregnancy. Radical approach hysterectomy has been used bleeding in patients with life-threatening situations, and if fertility is completed. Conservative approach may be medical or surgical. Surgical procedure; hypogastric or uterine artery embolization, cervical curettage can be applied. Medical options, a cytotoxic drug methotrexate can be used systemic or intraamniotic and intraamniotic potassium chloride can be applied. Systemic methotrexate 50mg/m<sup>2</sup> as a single dose or multiple doses of 1mg/kg (1,3,5. Days) and folinic acid (2,4,6. Days) can be applied. If the treatment administered intraamniotic 50mg of methotrexate or 5 mmol / L potassium chloride is applied(3).

Patients with cervical pregnancy, usually young (average age: 29.9) and have lower parity (nulliparous,

47%) is increasing the importance of fertility protective conservative methods(2). The success of conservative methods is 95.6%(3). In conservative methods, the basic problem is the life-threatening bleeding after the procedure. Aspiration and curettage in the treatment of cervical pregnancy is the most common choice. Approximately, half of the patients applied suction and curettage. However, 21.1% of patients after aspiration and curettage to control bleeding may be required to implement additional methods(3,4). Therefore, in order to control bleeding after the procedure, the buffer with the foley catheter into the cervical canal and local prostaglandin and hemostasis methods such as sutures are used. Cases, where these methods fail, the internal iliac artery ligation or hysterectomy surgery can be used for control the bleeding(5,6). Our patients underwent treatment of complications developed in any case only applied to methotrexate. Curettage in the first stage of the process is one of the patients with a foley catheter after the procedure because of bleeding with the buffer and applied to methotrexate. Tage applied to other cases, an additional treatment was required and left. The success of methotrexate treatment of cervical ectopic pregnancies, a single dose of methotrexate in the treatment of multidose this rate was 83%, 54% roll. Adjuvant methotrexate in the treatment of conservative methods applied to these rates is up to 94%. Dilatation and curettage alone is performed in cases 75% success rate. Local injection of methotrexate or potassium chloride, either alone or in conjunction with dilatation curettage is recommended as initial therapy in patients with fetal cardiac activity. Early conservative treatment methods identified in cases of cervical ectopic pregnancy without affecting the safe and effective method of fertility has been shown to(3,7,8). In our cases of cervical pregnancy, 5-7 weeks of pregnancy through the detection of patients with conservative approaches to the fertility preserved, prevented the development of serious complications.

## REFERENCES

1. Breen JL. A 21 year survey of 654 ectopic pregnancies. Am J Obstet Gynecol 2002; 106: 1004- 19.
2. Ushakov FB, Elchalal U, Aceman PJ, Schenker JG. Cervical pregnancy: Past and future. Obstet Gynecol Surv 1997; 52:

- 45- 59.
3. Kirk E, Condous G, Haider Z, Syed A, Ojha K, Bourne T. The conservative management of cervical ectopic pregnancies *Ultrasound Obstet Gynecol* 2006; 27: 430- 7.
  4. Mun S, Taner C, Mızrak T, Şenyuva İ, Özgenç Y, Çelimli F. Servikal gebelik: Olgu sunumu. *Perinatoloji Dergisi* 2006; 14: 55- 8.
  5. Maral İ, Sözen U, Balık E. Servikal Gebeliğin Konservatif Tedavisi (Olgu Sunumu). *Turk. Klin Jinekoloj Obst* 1993; 3: 67- 9.
  6. Harman M, Zeteroğlu Ş, Etlik Ö, Arslan İ. Bozulmuş servikal gebelikte arteryel embolizasyon ile tedavi. *Turk J Diagn Intervent Radiol* 2003; 9: 91- 3.
  7. Kim TJ, Seong SJ, Lee KJ, Lee JH, Shin JS, Lim KT. Clinical outcomes of patients treated for cervical pregnancy with or without methotrexate *J Korean Med Sci* 2004; 19: 848- 52.
  8. Tang PP, Liu XY, Chen N, Dai Q, Cui QC, Jin ZY, Lang JH. *Zhonqquo Yi Xue Ke Xue Yuan Xue Bao.* 2010; 32(5): 497- 500.