



## Evaluation of Central and Peripheral Retinal Vascular Changes in the Fellow Eyes of Patients with Unilateral Retinal Vein Occlusions

✉ Mestan Ertop\*, ✉ Fulya Yaylacioğlu Tuncay\*\*, ✉ Yavuz Kemal Arıbaş\*\*\*, ✉ Hüseyin Baran Özdemir\*, ✉ Gökhan Gürelik\*, ✉ Mehmet Emin Atılğan\*, ✉ Şengül Özdek\*

\*Gazi University Faculty of Medicine, Department of Ophthalmology, Ankara, Türkiye

\*\*University of Health Sciences Türkiye, Gülhane Faculty of Medicine, Department of Medical Biology, Ankara, Türkiye

\*\*\*Abdulkadir Yüksel State Hospital, Clinic of Ophthalmology, Gaziantep, Türkiye

### Abstract

**Objectives:** To evaluate the subtle peripheral retinal and macular vascular changes in the fellow eyes of patients with unilateral retinal vein occlusion (RVO).

**Materials and Methods:** This retrospective study included 53 patients with unilateral RVO and 44 age-matched controls. The frequency of peripheral retinal vascular pathologies in both eyes was evaluated using high quality ultra-wide field fluorescein angiography (UWFFA). Macular vascular density, flow area, and foveal avascular zone measurements from optical coherence tomography angiography (OCTA) were analyzed together with laser flare photometry values in patients and controls.

**Results:** Peripheral retinal vascular pathologies were detected on UWFFA in the fellow eyes of 36 (67.9%) patients. No significant central vascular pathologies were detected on OCTA and there was no significant difference in OCTA parameters between the fellow eyes and the controls. Flare values did not differ significantly between the control and the fellow eyes.

**Conclusion:** Two thirds of the fellow eyes of unilateral RVO patients had subtle peripheral retinal vascular changes, while there was no significant microvascular change detected with OCTA in the macula. This suggests that vascular changes caused by systemic vascular disorders probably first start in the peripheral retina of the fellow eyes of patients with RVO.

**Keywords:** Laser flare photometry, optical coherence tomography angiography, retinal vein occlusion, ultra-wide field fluorescein angiography, unilateral

### Introduction

One of the most common and severe retinal vascular diseases is retinal vein occlusion (RVO).<sup>1</sup> Based on the location of the lesion, RVOs are classified as branch retinal vein occlusion (BRVO) and central retinal vein occlusion (CRVO). Although the exact pathogenesis of both BRVO and CRVO has not yet been determined, there are multiple suggested mechanisms and identified risk factors. Systemic conditions such as atherosclerosis, hypertension (HT), diabetes mellitus (DM), and thrombophilia are among the leading risk factors for the development of RVO.<sup>2,3,4,5,6</sup> Patients with RVO also have an increased risk of cardiovascular diseases.<sup>7,8</sup> It was shown that RVO is associated with increased arterial stiffness and significant endothelial dysfunction. This strengthens the theory that systemic arteriosclerosis with endothelial dysfunction has a significant role in the development of RVO.<sup>9</sup> Considering all these systemic etiologies and risk factors in RVO, the fellow eyes of unilateral RVO patients may carry subtle vascular changes and should be at risk of developing RVO. Some epidemiologic studies have confirmed this expectation and reported that the fellow eyes of RVO patients have a significantly increased risk of RVO when compared with the general population and the disease becomes bilateral in 15% of patients over time.<sup>2,10</sup>

Subtle vascular changes in the fellow eyes cannot be detected during routine ophthalmological examination or imaging with routine optical coherence tomography (OCT) and fundus fluorescein angiography (FFA). However, they may be revealed using novel examination techniques like optical coherence

**Cite this article as:** Ertop M, Yaylacioğlu Tuncay F, Arıbaş YK, Özdemir HB, Gürelik G, Atılğan ME, Özdek Ş. Evaluation of Central and Peripheral Retinal Vascular Changes in the Fellow Eyes of Patients with Unilateral Retinal Vein Occlusions. *Turk J Ophthalmol* DOI: 10.4274/tjo.galenos.2023.94389 [Ahead of Print]

**Address for Correspondence:** Şengül Özdek, Gazi University Faculty of Medicine, Department of Ophthalmology, Ankara, Türkiye  
E-mail: sozdek@gazi.edu.tr ORCID-ID: orcid.org/0000-0002-7494-4106  
Received: 23.06.2022 Accepted: 22.03.2023

DOI: 10.4274/tjo.galenos.2023.94389



tomography angiography (OCTA) for macular vascular changes and ultra-widefield fluorescein angiography (UWFFA) for the peripheral retina. OCTA is a newer, non-invasive method for the visualization of retinal vascular layers and may detect subtle changes in the deep capillary plexus at an early stage.<sup>11,12</sup> UWFFA, which shows almost the entire retina (up to 200°) and captures the peripheral retina simultaneously without the need for patient refixation, may reveal subtle vascular changes in the extreme periphery of fellow eyes.<sup>13,14</sup> Lastly, it is well known that blood-retinal and blood-aqueous barriers are disrupted in eyes with RVO. Therefore, there may also be barrier disruption in the fellow eyes of RVO patients during the asymptomatic early period that could be detected via laser flare photometry.<sup>15,16,17</sup> In literature, there are studies evaluating the fellow eyes of patients with unilateral RVO with electrophysiologic tests, microperimetry, and retina layer thickness measurements.<sup>10,18,19,20,21</sup> Additionally, a limited number of angiographic studies were done to reveal retinal or choroidal vascular changes in the fellow eye using UWFFA in BRVO patients, adaptive optics scanning light ophthalmoscope fluorescein angiography in CRVO patients, and OCTA in RVO patients.<sup>21,22,23,24,25</sup> However there is no study evaluating both peripheral and central subtle vascular changes in the fellow eyes of unilateral RVO patients at the same time. Therefore, this study aimed to search for possible blood-eye barrier disruption and subtle peripheral and central retinal vascular changes affecting the fellow eyes of unilateral RVO patients using laser flare photometry, UWFFA, and OCTA.

## Materials and Methods

### Study Design

This retrospective study included adult patients who underwent standard clinical evaluation and treatment for eye diseases. The research protocol was approved by the Gazi University Institutional Ethical Review Board (decision no: 2019-375/11, date: 04.11.2019). The study was designed in compliance with the Declaration of Helsinki.

### Participants

The medical records and images of unilateral RVO patients who applied to the Ophthalmology Clinic of Gazi University Hospital between January 2018 and March 2020 were reviewed. Those with good quality UWFFA, OCTA, and laser flare photometry measurements from both eyes were included. Of 87 patients, 34 were excluded because of diabetic retinopathy, age-related macular degeneration, other retinal vascular diseases, high myopia (spherical equivalent >6 diopters), previous retinal surgery, or any media opacity which prevented high-quality OCTA and UWFFA acquisition from both eyes. Age-matched subjects who presented to the clinic for refraction examination without any significant ocular diseases were included as controls. Eligibility criteria for participants in the control group were having undergone a comprehensive ophthalmic examination with OCTA imaging and laser flare photometry measurements. Best corrected visual acuity (BCVA) <20/25, high myopia (spherical equivalent >6 diopters), significant media opacity, and

any retinal or choroidal pathology were the exclusion criteria for the controls and the fellow eyes.

Demographic data, history of ocular and systemic diseases, drugs used, and RVO duration and previous treatment (for the RVO group) were collected from all participants. BCVA and intraocular pressure (IOP) were noted for both eyes. All participants had bilateral Heidelberg SD-OCT (Heidelberg Engineering Inc., Heidelberg, Germany), OCTA (AngioVue; Optovue Inc., Fremont California, USA), and laser flare photometry measurements (Kowa Company Ltd, Nagoya, Japan). Only participants in the RVO group had Optos 200 Tx (Optos, Dunfermline, Scotland) wide-angle color fundus photography and angiography.

### Ultra-widefield Fluorescein Angiography

UWFFA images were taken by Optos 200 Tx (Optos, Dunfermline, Scotland) after intravenous fluorescein administration and evaluated independently by two physicians (Ş.Ö., M.E.). The presence and extent of capillary non-perfusion, neovascularization, collaterals, hyperfluorescent dots, and late peripheral vascular leakage were recorded for RVO eyes. Patients with a capillary non-perfusion area greater than 10 disc diameters were considered ischemic cases and the others as non-ischemic. In cases of BRVO, the affected area was noted. Images of the fellow eyes were evaluated for the presence of any vascular pathology such as capillary non-perfusion, late leakage, vascular loops or anastomosis, hyperfluorescent dots, and pathological vessels.

### Optical Coherence Tomography Angiography

OCTA images were analyzed based on 6×6 mm images using the RTVue XR Avanti device (ReVue software, version 2015.100.0.35; Optovue Inc., Fremont California, USA). The software automatically divides the tissue into different layers: superficial capillary plexus, deep capillary plexus, outer retinal layer, and choriocapillaris layer. Before any measurements, two ophthalmologists (Ş.Ö., M.E.) independently evaluated the images and checked the segmentation of the retinal layers. For each layer (superficial or deep), vascular density (VD) measurements from six areas (whole, superior, inferior, fovea, parafovea, perifovea) were calculated separately. Superficial and deep capillary plexus foveal avascular zone (FAZ) area, outer retinal flow area (FA), choriocapillaris FA, and central macular thickness (CMT) were provided automatically by the device. Measurements of the FAZ area in the images of RVO eyes could not be standardized due to cystoid macular edema or retinal thinning.

### Statistical Analysis

The SPSS statistical package program (version 22.0 for Windows; IBM Corp., Armonk, NY, USA) was used for statistical analysis. Chi-square test was used for comparisons of categorical variables. Continuous variables were compared with the independent variables t-test, One-Way ANOVA, Kruskal-Wallis test, and Mann-Whitney U test, depending on conformity to normal distribution. The significance level was accepted as  $p < 0.05$ .

**Results**

A total of 53 patients with unilateral RVO (18 patients with CRVO and 35 patients with BRVO) and 44 controls were included in this study. The demographic data of the controls and patients are shown in [Table 1](#). The mean age of the patients was 61.28±11.87 years (range, 26-84 years). Twenty-eight patients (52.8%) were female and 25 (47.2%) were male. HT was observed in 31 patients (58.5%) and DM in 17 patients (32.1%). Seventeen patients (32.1%) were on antiplatelet therapy and 10 (18.8%) of them started antiplatelet therapy before RVO diagnosis. Glaucoma was observed in 13 patients (24.5%). There was no history of additional ocular disease except mild cataract in the patients' fellow eyes.

The control group included 44 eyes of 44 participants. The male/female ratio was 29/15 and the mean age was 59.4±9.1 years (range, 36-73 years). Nineteen (43.2%) of them had HT, 13 (29.5%) had DM, and 6 (13.6%) were on antiplatelet therapy ([Table 1](#)). None of the controls had a history of ocular disease except mild cataract. There was no statistically significant difference between the control group and the study group in terms of mean age, sex, or systemic comorbidities ([Table 1](#)).

The ophthalmologic findings of the groups are shown in [Table 2](#). The mean LogMAR BCVA of the patients was 0.55±0.54 in the RVO eyes and 0.03±0.11 in the fellow eyes (Mann-Whitney U test, p<0.001). There was no significant difference in BCVA or IOP between the fellow eyes and the control group (p>0.05) and no significant difference in IOP between the RVO and fellow eyes (p>0.05). The frequency of pseudoexfoliation and glaucoma did not differ significantly between RVO and fellow eyes (chi-square test, p=0.696 and p=0.143, respectively). The mean duration of RVO was 56.3±50.84 months (range, 4-200 months). Of the 53 patients with unilateral RVO, 12 (22.6%) were treatment-naive, 15 (28.3%) had undergone laser photocoagulation and anti-Vascular endothelial growth factor (VEGF) injections, and 26 (49.1%) had received only anti-VEGF injections.

Laser flare photometry measurements were done at least one month after the anti-VEGF injections or at least two months after laser photocoagulation. The mean laser flare photometry

values were 11.94±8.47 photons per millisecond (ph/ms) in RVO eyes, 7.47±5.64 ph/ms in the fellow eyes, and 6.68±3.51 ph/ms in the control group ([Table 3](#)). The flare photometry values were significantly higher in RVO eyes compared to both fellow eyes and controls (p=0.001). Although flare values were slightly higher in the fellow eyes than the control eyes, the difference was not significant (p=0.935). Flare values in the RVO eyes did not differ significantly based on the type of RVO, extent of ischemia, or previous treatment for RVO ([Table 3](#)).

The UWFFA findings in RVO eyes and fellow eyes are shown in [Table 4](#). There was ischemic RVO in 16 eyes (30.2%), collateral shunting vessels in 14 eyes (31.1%), retinal neovascularization in 3 eyes (5.7%), and panretinal laser photocoagulation scars in 15 eyes (28.3%) with RVO. Four of the 35 BRVO cases were macular (7.5%) and 31 were extramacular (92.5%). Of the extramacular BRVOs, 21 (39.6%) were superotemporal, 8 (15.1%) were inferotemporal, 1 (1.9%) was superior hemispheric, and 1 (1.9%) was inferior hemispheric. On UWFFA of the fellow eyes of RVO patients, the peripheral retina was normal in 17 eyes (32.1%; 7 CRVO, 10 BRVO), whereas some pathological findings could be identified in 36 eyes (67.9%; 11 CRVO, 25 BRVO). Peripheral

**Table 2. Ophthalmological findings of the study eyes**

	RVO eyes (n=53)	Fellow eyes (n=53)	Control eyes (n=44)
<b>Mean ± SD</b>			
BCVA (logMAR)	0.55±0.54	0.03±0.11	0.03±0.06
IOP (mmHg)	17.31±4.42	16.49±3.33	15.32±2.41
<b>n (%)</b>			
Glaucoma	13 (24.5%)	7 (13.2%)	0 (0%)
Pseudoexfoliation	4 (7.6%)	3 (5.7%)	0 (0%)
Pseudophakia	14 (26.4%)	6 (11.3%)	3 (6.8%)
Type of RVO: CRVO/BRVO	18 (34%)/35 (66%)	-	-

BCVA: Best corrected visual acuity, logMAR: Logarithm of the minimum angle of resolution, IOP: Intraocular pressure, RVO: Retinal vein occlusion, CRVO: Central retinal vein occlusion, BRVO: Branch retinal vein occlusion, SD: Standard deviation

**Table 1. Demographic properties and systemic conditions of patients and controls**

	RVO (n=53)	Control (n=44)	p value	
Age (years)	Mean ± SD (range)		0.483	
	61.28±11.87 (26-84)	59.41±9.06 (36-73)		
Gender			0.07	
Male/female	25/28	29/15		
Systemic comorbidities	n (%)		0.99	
	None	12 (22.6%)		10 (22.7%)
	Hypertension	31 (58.5%)		19 (43.2%)
	Diabetes mellitus	17 (32.1%)		13 (29.5%)
	Anti-aggregant/anti-coagulant use	10 (18.8%)		6 (13.63%)

RVO: Retinal vein occlusion, SD: Standard deviation

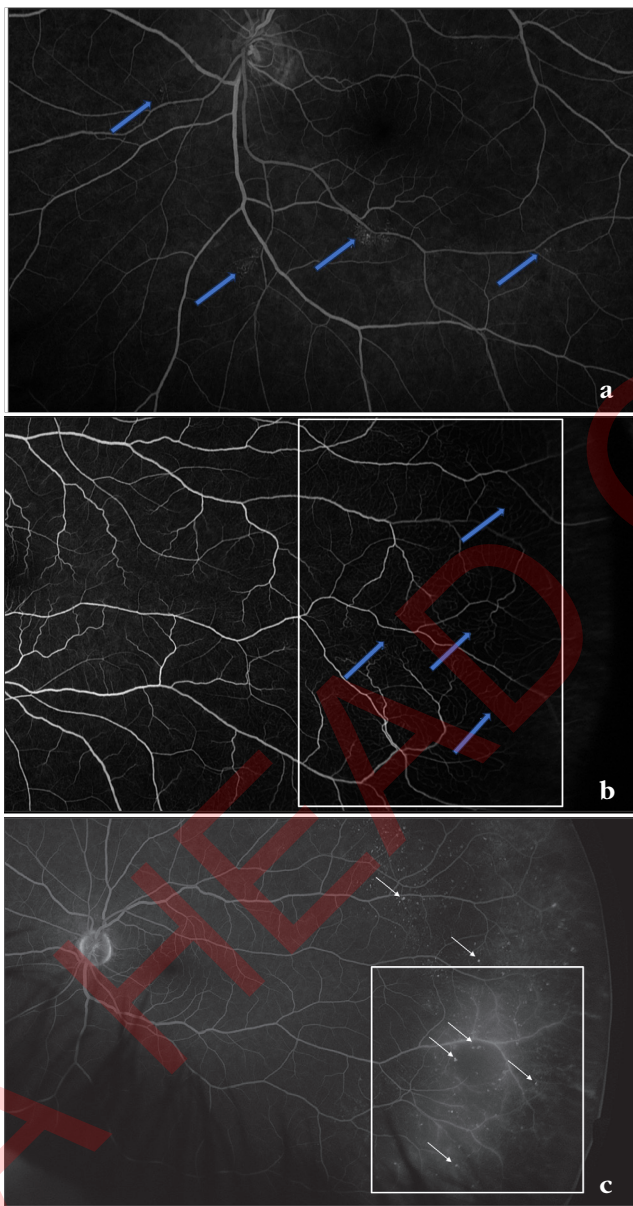
**Table 3. Laser flare photometry values of the study groups**

Compared study groups	Flare (ph/ms)	p value*
BRVO/CRVO	10.23/15.04	0.240
Ischemic RVO/non-ischemic RVO	10.71/12.55	0.366
Previous treatment (+)/(-)		
	Anti-VEGF	11.58/13.06
Laser + anti-VEGF	14.54/10.77	0.119
RVO/control	11.94/6.68	0.001
RVO/fellow eyes	11.94/7.47	0.001
Fellow eyes/controls	7.47/6.68	0.935
Fellow eyes of CRVO/fellow eyes of BRVO	8.35/6.97	0.704

\*Mann-Whitney U test was used for comparisons, BRVO: Branch retinal vein occlusion, CRVO: Central retinal vein occlusion, RVO: Retinal vein occlusion, VEGF: Vascular endothelial growth factor, ph/ms: photons per millisecond

hyperfluorescent dots and varying degrees of disruption in the peripheral capillary bed were the most common pathological findings, observed in 29 (54.7%) and 22 (41.5%) of the fellow eyes, respectively. There were vascular anastomosis or loop-like shunt vessels in 8 (15.1%) eyes and late peripheral vascular leakage in 4 (7.5%) of the fellow eyes (Figure 1). There was no significant difference between the types of RVO in terms of peripheral retinal vascular pathologies observed in the fellow eyes with UWFFA ( $p=0.759$ ) when the BRVO and CRVO patients were evaluated in two groups.

Concerning systemic comorbidities in the 36 patients with



**Figure 1.** Ultra-widefield fluorescein angiography images from the unaffected fellow eyes of patients with retinal vein occlusion: (a) localized microvascular changes; capillary drop-out and microaneurysms (arrows). (b) Vascular anastomoses (arrows) and peripheral capillary drop-out (rectangle). (c) Multiple hyperfluorescent dots (arrows) and late peripheral leakage (rectangle)

fellow eye pathologies, 10 patients (27.8%) had both HT and DM, 13 (36.1%) had HT only, 2 (5.5%) had DM only, and 11 patients (30.6%) had no known systemic diseases. Of the 17 patients without any UWFFA findings in the fellow eyes, 5 (31.3%) of them had no systemic comorbidities. There was no statistically significant difference between the groups with respect to systemic comorbidities ( $p=0.366$ )

OCTA findings are shown in Table 5. The VD values were significantly lower in RVO eyes compared to fellow eyes in almost all areas except foveal VD in the deep capillary plexus. Choriocapillaris FA was lower in RVO eyes and CMT was higher in RVO eyes as compared to the fellow eyes, as expected ( $p<0.001$ ) (Table 5). However, there was no significant difference between VD, FA, FAZ, and CMT values in the control and fellow eyes (Table 5).

### Discussion

This study primarily focused on the peripheral retinal and macular vascular changes in the fellow eyes of patients with unilateral RVO using UWFFA and OCTA. We demonstrated peripheral retinal vascular changes in 67.9% of the fellow eyes of RVO patients using UWFFA. The most commonly detected vascular changes were peripheral hyperfluorescent dots (54.7%) and disruption of the peripheral capillary bed (41.5%). In the literature, there is only one study investigating UWFFA findings in the fellow eye of RVO patients, but it included only patients

**Table 4. Ultra-widefield fundus fluorescein angiography characteristics of RVO patients**

	n	%
<b>RVO eyes</b>		
CRVO	18	34
BRVO	35	66
Inferior hemispheric BRVO	1	1.9
Superior hemispheric BRVO	1	1.9
Inferotemporal BRVO	8	15.1
Superotemporal BRVO	21	39.6
Macular BRVO	4	7.5
Ischemic	16	30.2
Non-ischemic	37	69.8
Neovascularization	3	5.7
Collateral formation	28	52.8
<b>Fellow eyes</b>		
Positive angiography findings	36	67.9
Peripheral hyperfluorescent dots	29	54.7
Peripheral capillary plexus disruption	22	41.5
Peripheral shunt vessels (vascular loops)	8	15.1
Late peripheral leakage	4	7.5
No angiographic findings	17	32.1
BRVO: Branch retinal vein occlusion, CRVO: Central retinal vein occlusion, RVO: Retinal vein occlusion		

**Table 5. Optical coherence tomography angiography findings in RVO eyes, fellow eyes, and healthy control eyes**

	RVO group (n=53)	Fellow eyes (n=53)	Control group (n=44)	p*	p**
<b>Superficial capillary plexus vascular density (%)</b>					
Whole	41.2±6.4	47.5±4.8	48.5±3.2	<0.001	0.260
Superior	41.0±6.3	47.0±5.0	48.5±3.2	<0.001	0.111
Inferior	41.4±7.2	47.8±4.9	48.5±3.2	<0.001	0.437
Fovea	22.1±11.5	18.2±8.2	18.6±7.6	0.047	0.831
Parafovea	41.9±7.9	50.3±5.7	51.2±4.3	<0.001	0.416
Perifovea	41.6±7.1	48.1±4.8	49.1±3.3	<0.001	0.245
<b>Deep capillary plexus vascular density (%)</b>					
Whole	40.1±6.6	44.7±5.6	46.7±6.2	<0.001	0.092
Superior	39.5±7.0	44.5±5.9	46.5±6.3	<0.001	0.107
Inferior	40.3±7.2	44.8±5.8	46.9±6.3	<0.001	0.091
Fovea	34.8±12.2	33.4±9.5	35.1±7.8	0.509	0.35
Parafovea	43.8±8.2	51.0±5.3	52.3±4.5	<0.001	0.204
Perifovea	40.7±7.1	45.7±6.3	47.8±6.9	<0.001	0.122
FAZ area (mm <sup>2</sup> )	0.337±0.243	0.295±0.130	0.289±0.101	0.789	0.826
Outer retinal flow area (mm <sup>2</sup> )	0.688±0.453	0.770±0.399	0.666±0.369	0.234	0.120
Choriocapillaris flow area (mm <sup>2</sup> )	1.86±0.35	2.05±0.18	2.02±0.13	<0.001	0.295
Central macular thickness (µm)	333.43±184.14	248.51±23.84	251.91±26.88	0.007	0.511

\*RVO eyes vs. fellow eyes, \*\*Fellow eyes vs. control eyes, RVO: Retinal vein occlusion, FAZ: Foveal avascular zone

with BRVO.<sup>21</sup> They detected peripheral vascular leakage in 9 of the 81 eyes (11.1%) but did not investigate other peripheral vascular changes in the fellow eyes.<sup>21</sup> In the present study, peripheral late vascular leakage was detected in 7.5% of the fellow eyes, similar to the previously mentioned study.

Systemic vascular diseases like DM and HT may cause microcirculation problems like endothelial dysfunction and peripheral vasoconstriction due to increased vascular resistance, decreased blood flow, and increased plasma viscosity.<sup>26</sup> As the duration of the disease increases, severe atherosclerotic vascular changes occur in the peripheral arteries of hypertensive patients.<sup>27</sup> This information is consistent with our findings of the disrupted peripheral capillary bed and the resultant shunt vessels observed in UWFFA. The presence of peripheral hyperfluorescent spots (probably representing microaneurysms) also suggests localized ischemia caused by HT and DM. Although in this study we observed no statistically significant difference in systemic comorbidities between patients with and without UWFFA findings in the fellow eye, this could be due to the small patient population. Further studies with larger patient populations may show differences between these two groups. Nearly 6% of the patients had HT and 32.5% had DM in the present cohort and this explains why the retinal vascular structures of fellow eyes were also affected to some degree. However, local factors (e.g., crowded disc, arterial compression, increased IOP) remain the main determinants of asymmetric involvement in RVO.<sup>25,28</sup>

Macular microcirculation is better assessed with the recent technology of OCTA as compared to conventional FFA.<sup>11,12</sup>

In the present study we assessed macular microcirculation changes in RVO eyes, fellow eyes, and control eyes with 6x6 mm OCTA images. VD values were significantly lower in RVO eyes as compared to fellow eyes in almost all areas except foveal VD in the deep capillary plexus. This was expected and consistent with the literature.<sup>20,23,29</sup> Koullisis et al.<sup>29</sup> examined the fellow eyes of unilateral RVO patients and demonstrated that VD was lower in the superficial and deep capillary plexus in fellow eyes than in the control group. However, we failed to demonstrate any significant difference in the VD, FA, FAZ, and CMT measurements between the fellow eyes and the control eyes. This discordance with the literature may be caused by the similar distribution of systemic diseases like HT and DM in the control group in our study. Supporting this idea is the fact that the control groups did not have similar systemic diseases to the RVO groups in the previously mentioned studies.<sup>23,29</sup> Patients with HT have been shown to have decreased perifoveal capillary density and decreased capillary blood flow velocity compared to healthy subjects.<sup>18</sup> We believe that OCTA measurements in a 6x6 mm area (which is average macula size) are more helpful to show the vascular status of the entire macula rather than 3x3 mm measurements.

In the present study, we found that aqueous flare values were significantly higher in RVO eyes than fellow eyes (p=0.001). Increased aqueous flare mainly reflects the disruption of the blood-aqueous barrier, which was shown to be damaged in RVO eyes.<sup>15</sup> Flare values have been reported to be even higher in ischemic CRVO than non-ischemic CRVO.<sup>17</sup> However, we failed

to demonstrate any statistically significant difference in aqueous flare values of RVO eyes based on the presence of ischemia and the type of RVO (Table 3). There was no statistically significant difference between the control eyes and the fellow eyes, which suggests that the subtle microvascular changes caused by systemic vascular diseases do not reach a level that could affect the blood-eye barriers to a detectable degree.

#### Study Limitations

First of all, peripheral retinal vascular changes could not be compared with control eyes because we did not perform UWFFA, which is an invasive test, in the control group. Secondly, the duration of RVO and treatment status of the eyes were variable in the patients due to the retrospective nature of the study, and this may have affected OCTA and flare measurements to some extent. Thirdly, the sample size was small.

#### Conclusion

This is the first study to investigate all aspects of retinal microvascular changes in the fellow eyes of patients with RVO as determined with UWFFA (peripheral retina), OCTA (central retina), and laser flare photometry (blood-retina and blood-aqueous barriers). The fellow eyes of unilateral RVO patients demonstrated some peripheral retinal vascular changes such as capillary disruption, hyperreflective dots, peripheral vascular anastomosis and loops, and late leakage in the UWFFA, indicating that systemic factors affect both eyes to some extent. However, microvascular changes in the macula could not be demonstrated with OCTA analysis, suggesting that early subtle vascular changes start to occur first in the peripheral retina in these patients. Aqueous flare values demonstrated that the blood-eye barriers were disrupted in the RVO eyes but not the fellow eyes. Future prospective studies could help to determine whether these subtle findings in the fellow eyes of unilateral RVO patients could be associated with a higher risk of developing bilateral disease.

#### Ethics

**Ethics Committee Approval:** Gazi University Institutional Ethical Review Board (decision no: 2019-375/11, date: 04.11.2019).

**Informed Consent:** Retrospective study.

**Peer-review:** Externally and internally peer-reviewed.

#### Authorship Contributions

Surgical and Medical Practices: Ş.Ö., G.G., M.E., H.B.Ö., Concept: Ş.Ö., F.Y.T., Design: M.E., F.Y.T., Data Collection or Processing: M.E., F.Y.T., M.E.A., Analysis or Interpretation: M.E., F.Y.T., Y.K.A., Literature Search: M.E., F.Y.T., Writing: M.E., F.Y.T., Ş.Ö.

**Conflict of Interest:** No conflict of interest was declared by the authors.

**Financial Disclosure:** The authors declared that this study received no financial support.

#### References

- Rogers S, McIntosh RL, Cheung N, Lim L, Wang JJ, Mitchell P, Kowalski JW, Nguyen H, Wong TY; International Eye Disease Consortium. The prevalence of retinal vein occlusion: pooled data from population studies from the United States, Europe, Asia, and Australia. *Ophthalmology*. 2010;117:313-319.
- Jaulim A, Ahmed B, Khanam T, Chatziralli IP. Branch retinal vein occlusion: epidemiology, pathogenesis, risk factors, clinical features, diagnosis, and complications. An update of the literature. *Retina*. 2013;33:901-910.
- Klein R, Klein BE, Moss SE, Meuer SM. The epidemiology of retinal vein occlusion: the Beaver Dam Eye Study. *Trans Am Ophthalmol Soc*. 2000;98:133-141.
- Hayreh SS, Zimmerman B, McCarthy MJ, Podhajsky P. Systemic diseases associated with various types of retinal vein occlusion. *Am J Ophthalmol*. 2001;131:61-77.
- Kolar P. Risk factors for central and branch retinal vein occlusion: a meta-analysis of published clinical data. *J Ophthalmol*. 2014;2014:724780.
- Marcinkowska A, Cisiecki S, Rozalski M. Platelet and Thrombophilia-Related Risk Factors of Retinal Vein Occlusion. *J Clin Med*. 2021;10:3080.
- Martin SC, Butcher A, Martin N, Farmer J, Dobson PM, Bartlett WA, Jones AF. Cardiovascular risk assessment in patients with retinal vein occlusion. *Br J Ophthalmol*. 2002;86:774-776.
- Tsaloumas MD, Kirwan J, Vinall H, O'Leary MB, Prior P, Kritzinger EE, Dodson PM. Nine year follow-up study of morbidity and mortality in retinal vein occlusion. *Eye (Lond)*. 2000;14:821-827.
- Gouliopoulos N, Siasos G, Moschos MM, Oikonomou E, Rouvas A, Bletsas E, Stampouloglou P, Siasou G, Paraskevopoulos T, Vlasik K, Marinos G, Tousoulis D. Endothelial dysfunction and impaired arterial wall properties in patients with retinal vein occlusion. *Vasc Med*. 2020;25:302-308.
- McIntosh RL, Rogers SL, Lim L, Cheung N, Wang JJ, Mitchell P, Kowalski JW, Nguyen HP, Wong TY. Natural history of central retinal vein occlusion: an evidence-based systematic review. *Ophthalmology*. 2010;117:1113-1123.
- Spaide RF, Klancnik JM Jr, Cooney MJ. Retinal vascular layers imaged by fluorescein angiography and optical coherence tomography angiography. *JAMA Ophthalmol*. 2015;133:45-50.
- Matsunaga D, Yi J, Puliafito CA, Kashani AH. OCT angiography in healthy human subjects. *Ophthalmic Surg Lasers Imaging Retina*. 2014;45:510-515.
- Prasad PS, Oliver SC, Coffee RE, Hubschman JP, Schwartz SD. Ultra wide-field angiographic characteristics of branch retinal and hemicentral retinal vein occlusion. *Ophthalmology*. 2010;117:780-784.
- Tsui I, Kaines A, Schwartz S. Patterns of periphlebitis in intermediate uveitis using ultra wide field fluorescein angiography. *Semin Ophthalmol*. 2009;24:29-33.
- Miyake K, Miyake T, Kayazawa F. Blood-aqueous barrier in eyes with retinal vein occlusion. *Ophthalmology*. 1992;99:906-910.
- Nguyen NX, Kuchle M. Aqueous flare and cells in eyes with retinal vein occlusion—correlation with retinal fluorescein angiographic findings. *Br J Ophthalmol*. 1993;77:280-283.
- Noma H, Mimura T, Tatsugawa M, Shimada K. Aqueous flare and inflammatory factors in macular edema with central retinal vein occlusion: a case series. *BMC Ophthalmol*. 2013;13:78.
- Sakaue H, Katsumi O, Hirose T. Electroretinographic findings in fellow eyes of patients with central retinal vein occlusion. *Arch Ophthalmol*. 1989;107:1459-1462.
- Kim MJ, Woo SJ, Park KH, Kim TW. Retinal nerve fiber layer thickness is decreased in the fellow eyes of patients with unilateral retinal vein occlusion. *Ophthalmology*. 2011;118:706-710.
- Cetin EN, Bozkurt K, Parca O, Pekel G. Automated macular segmentation with spectral domain optical coherence tomography in the fellow eyes of patients with unilateral retinal vein occlusion. *Int Ophthalmol*. 2019;39:2049-2056.
- Yu HY, Lee MW, Kim JT, Lee SC, Lee YH. Comparison of Each Retinal Layer Thicknesses between Eyes with Central Retinal Vein Occlusion and Normal Contralateral Eyes. *Korean J Ophthalmol*. 2022;36:274-281.

21. Tsui I, Bajwa A, Franco-Cardenas V, Pan CK, Kim HY, Schwartz SD. Peripheral fluorescein angiographic findings in fellow eyes of patients with branch retinal vein occlusion. *Int J Inflamm*. 2013;2013:464127.
22. Pinhas A, Dubow M, Shah N, Cheang E, Liu CL, Razeen M, Gan A, Weitz R, Sulai YN, Chui TY, Dubra A, Rosen RB. Fellow eye changes in patients with nonischemic central retinal vein occlusion: assessment of perfused foveal microvascular density and identification of nonperfused capillaries. *Retina*. 2015;35:2028-2036.
23. Adhi M, Filho MA, Louzada RN, Kuehlewein L, de Carlo TE, Bauml CR, Witkin AJ, Sadda SR, Sarraf D, Reichel E, Duker JS, Waheed NK. Retinal Capillary Network and Foveal Avascular Zone in Eyes with Vein Occlusion and Fellow Eyes Analyzed With Optical Coherence Tomography Angiography. *Invest Ophthalmol Vis Sci*. 2016;57:486-494.
24. Atilgan CU, Goker YS, Hondur G, Kosekahya P, Kocer AM, Citirik M. Evaluation of the radial peripapillary capillary density in unilateral branch retinal vein occlusion and the unaffected fellow eyes. *Ther Adv Ophthalmol*. 2022;14:25158414221090092.
25. Aribas YK, Hondur AM, Tezel TH. Choroidal vascularity index and choriocapillary changes in retinal vein occlusions. *Graefes Arch Clin Exp Ophthalmol*. 2020;258:2389-2397.
26. Jung F, Pindur G, Ohlmann P, Spitzer G, Sternitzky R, Franke RP, Leithäuser B, Wolf S, Park JW. Microcirculation in hypertensive patients. *Biorheology*. 2013;50:241-255.
27. Vicaut E. Hypertension and the microcirculation. *Arch Mal Coeur Vaiss*. 2003;96:893-903.
28. Klein R, Moss SE, Meuer SM, Klein BE. The 15-year cumulative incidence of retinal vein occlusion: the Beaver Dam Eye Study. *Arch Ophthalmol*. 2008;126:513-518.
29. Koulisis N, Kim AY, Chu Z, Shahidzadeh A, Burkemper B, Olmos de Koo LC, Moshfeghi AA, Ameri H, Puliafito CA, Isozaki VL, Wang RK, Kashani AH. Quantitative microvascular analysis of retinal venous occlusions by spectral domain optical coherence tomography angiography. *PLoS One*. 2017;12:e0176404.