



## Orbital Cerebrospinal Fluid Leak After Dog Bite: A Case Report

© Bilal Bahadır Akbulut, © Elif Bolat

Ege University Faculty of Medicine, Department of Neurosurgery, İzmir, Türkiye

### Abstract

A 4-year-old boy was referred to our tertiary hospital after a penetrating adnexal injury by a large-breed dog to the left orbital area. There was an increase in lacrimation, which was thought to be due to an inflammatory reaction. However, it was discovered that the lacrimation increased in the reverse-Trendelenburg position and with the Valsalva maneuver. Halo sign and beta transferrin test were positive, which led to the diagnosis of cerebrospinal fluid (CSF) fistula, and the patient was operated using a supraorbital craniotomy. A dural tear was visualized and sutured appropriately, then fibrin glue and an autologous dural graft were applied to the tear. The CSF oculorrhea stopped postoperatively, and the patient was discharged after 10 days of follow-up. The patient had no recurrent CSF leakage at 4-year follow-up. Although CSF oculorrhea is rare and may be difficult to discern from lacrimation, the presence of pneumocephalus and halo sign should suggest fistula repair.

**Keywords:** CSF fistula, penetrating injury, dog bite, case report

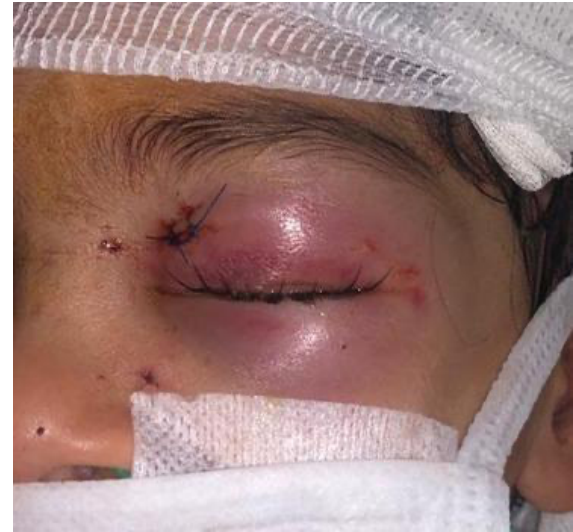### Introduction

A variety of mechanisms may cause a cerebrospinal fluid (CSF) fistula in traumatic injury, and its incidence is 0.5 to 3% in cranial injuries.<sup>1,2</sup> It most commonly presents as rhinorrhea and otorrhea but rarely may present as oculorrhea, especially in patients with direct trauma to the eye.<sup>3</sup>

We present an uncommon case of oculorrhea in a young child admitted after an adnexal penetrating injury by a large-breed dog bite.

### Case Report

A 4-year-old boy was referred to our tertiary care center after a penetrating dog bite to the left eyelid. There was marked periorbital and eyelid edema on the left side. A minor laceration was present at the time of referral, which was primarily closed by the consultant plastic and reconstructive surgeon (Figure 1).



**Figure 1.** The sutured entry wound can be seen adjacent to the patient's left eye, and there is edema over the eyelids

**Cite this article as:** Akbulut BB, Bolat E. Orbital Cerebrospinal Fluid Leak After Dog Bite: A Case Report. Turk J Ophthalmol DOI: 10.4274/tjo.galenos.2024.45087 [Ahead of Print].

**Address for Correspondence:** Bilal Bahadır Akbulut, Ege University Faculty of Medicine, Department of Neurosurgery, İzmir, Türkiye  
**E-mail:** b.bahadirakbulut@gmail.com **ORCID-ID:** orcid.org/0000-0002-7983-5056  
**Received:** 22.02.2024 **Accepted:** 22.04.2024

DOI: 10.4274/tjo.galenos.2024.45087

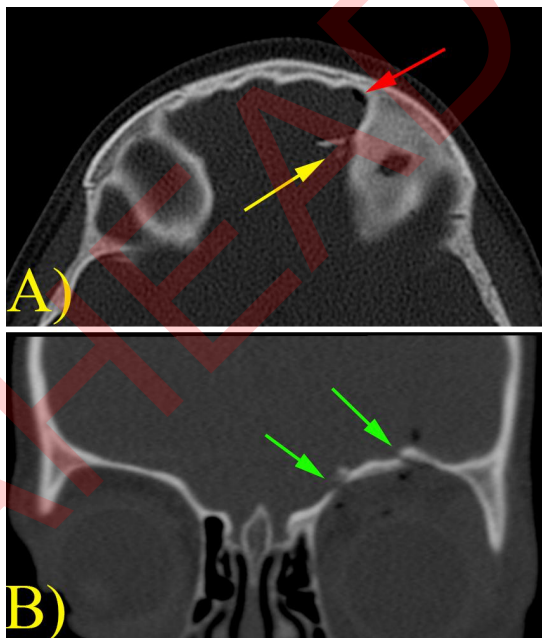


The patient was awake, slightly agitated, and had no neurological signs. An antibiotic regimen of cefotaxime 300 mg/kg/day (Tüm Ekip Pharmaceuticals, İstanbul, Türkiye), vancomycin 40 mg/kg/day (Koçak Pharmaceuticals, İstanbul, Türkiye), and metronidazole 30 mg/kg/day (Osel Pharmaceuticals, İstanbul, Türkiye) was initiated, and tetanus and rabies vaccinations were administered.

The ophthalmological examination showed that the globe was intact and the cornea clear. There was only conjunctival hyperemia and slight chemosis. While the visual examination was suboptimal due to poor patient cooperation, the patient was able to count fingers from at least 30 cm. Fundoscopic examination was unremarkable.

A computed tomography (CT) scan revealed a minor defect in the orbital roof and mild pneumocephalus without hematoma (Figure 2).

An increase in lacrimation was noted during the patient's first examination, but this was thought to be due to an inflammatory reaction after penetrating trauma. However, on follow-up, it was discovered that the lacrimation increased in the reverse-Trendelenburg position and sitting position. This suggested a CSF leak, and a subsequent test for the halo sign was positive. Three-dimensional reconstruction of the CT images yielded a more demonstrative image that increased our suspicion of a dural tear (Figure 3). A beta-2 transferrin test was performed on the clear secretions that were collected, and beta-2 transferrin was identified by immuno-fixation electrophoresis, thus confirming the presence of a CSF leak. No further imaging was performed since the only possible site of CSF leak was identified on the CT scan on admission. The patient was prepared for surgical repair of the dural tear.



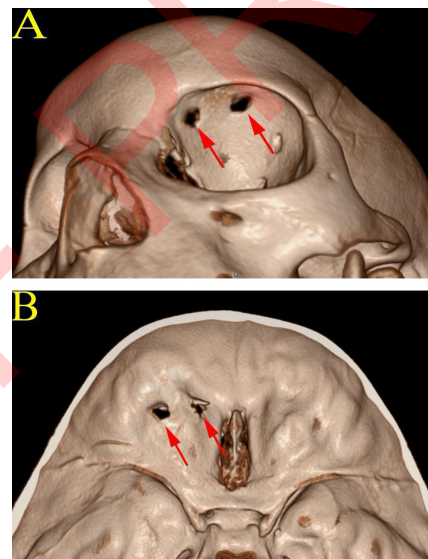
**Figure 2.** Cranial computed tomography scan. In the axial image (A), the pneumocephalus is marked with a red arrow, and the bone defect is marked with a yellow arrow. In the coronal view (B), the bone defect is marked with green arrows

A supraorbital craniotomy was performed via left eyebrow incision. After the dural tear was visualized, it was primarily sutured and supported with fibrin glue and a galeal graft. A routine postoperative CT was obtained to rule out complications (Figure 4).

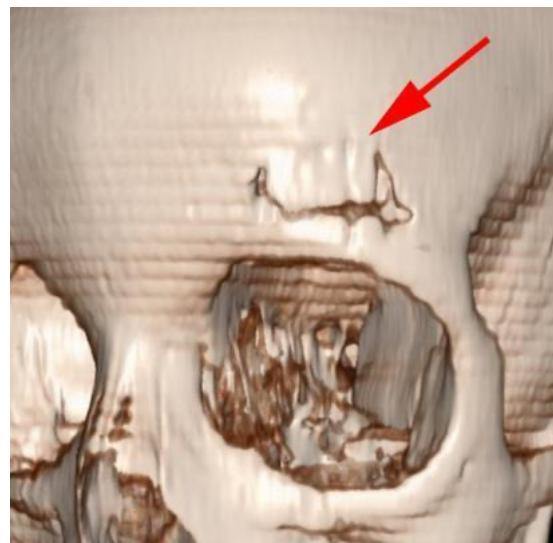
The patient was afebrile both on admission and follow-up. C-reactive protein levels reached a maximum of 12.58 mg/L, while white blood cell count reached a maximum of  $6.38 \times 10^3/\mu\text{L}$ .

Postoperatively, the patient's oculorrhea disappeared, and the patient was discharged after ten days of follow-up.

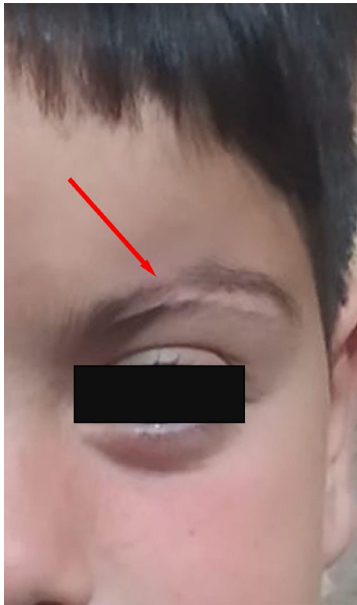The patient had no recurrent CSF fistula or complications at 4-year follow-up. The healed surgical incision is shown in Figure 5.



**Figure 3.** Three-dimensional reconstruction of the cranial computed tomography scan. The defect is visible from the exterior (A) and interior (B) aspects, marked by the red arrows



**Figure 4.** Three-dimensional construction of the postoperative cranial computed tomography scan. Note the small craniotomy (red arrow)



**Figure 5.** The patient's photograph at postoperative 4 years. The incision is indicated by a red arrow

## Discussion

An orbital CSF leak in a pediatric patient following a periorbital dog bite is an uncommon phenomenon. CSF leaks are more commonly associated with cranial trauma or neurosurgical interventions.<sup>1,4</sup> While orbital roof defects occur in surgeries, direct penetrating trauma to the dura overlaying the anterior fossa was probably the underlying cause of this leak. Diagnosing CSF leaks associated with orbital injuries can be challenging, as CSF is not easily distinguishable from other fluids such as tears. In our case, the change in the fluid flow pattern after position change and the positive halo sign were key indicators of the CSF leak.<sup>2</sup>

In this case, supraorbital craniotomy combined with the use of fibrin glue and autologous graft ensured a successful outcome. However, a more extensive approach, such as a bifrontal craniotomy, might be needed to expose more posteriorly

positioned tears.<sup>3,5</sup> Managing CSF leaks in pediatric patients requires careful consideration due to their unique anatomical and physiological characteristics.<sup>6,7</sup>

This case underscores the importance of considering CSF leaks in patients with penetrating orbital trauma. It adds to the limited literature on orbital CSF leaks following animal bites and emphasizes the need for a high index of suspicion and appropriate management in similar cases.

## Ethics

**Informed Consent:** Obtained.

## Authorship Contributions

Surgical and Medical Practices: E.B., Concept: B.B.A., Design: B.B.A., Data Collection or Processing: B.B.A., Analysis or Interpretation: E.B., Literature Search: B.B.A., Writing: B.B.A., E.B.

**Conflict of Interest:** No conflict of interest was declared by the authors.

**Financial Disclosure:** The authors declared that this study received no financial support.

## References

1. Pease M, Marquez Y, Tuchman A, Markarian A, Zada G. Diagnosis and surgical management of traumatic cerebrospinal fluid oculorrhea: case report and systematic review of the literature. *J Neurol Surg Rep.* 2013;74:57-66.
2. Oh JW, Kim SH, Whang K. Traumatic Cerebrospinal Fluid Leak: Diagnosis and Management. *Korean J Neurotrauma.* 2017;13:63-67.
3. Bunevicius A, Bareikis K, Kalasauskas L, Tamasauskas A. Penetrating Anterior Skull Base Fracture Inflicted by a Cow's Horn. *J Neurosci Rural Pract.* 2016;7(Suppl 1):S106-S108.
4. Schlosser RJ, Bolger WE. Nasal cerebrospinal fluid leaks: critical review and surgical considerations. *Laryngoscope.* 2004;114:255-265.
5. Couldwell WT, Weiss MH, Rabb C, Liu JK, Apfelbaum RI, Fukushima T. Variations on the standard transsphenoidal approach to the sellar region, with emphasis on the extended approaches and parasellar approaches: surgical experience in 105 cases. *Neurosurgery.* 2004;55:539-547; discussion 547-550.
6. Wang CS, Brown C, Mitchell RB, Shah G. Diagnosis and management of pediatric nasal CSF leaks and encephaloceles. *Curr Treat Options Allergy.* 2020;7:326-334.
7. Deng W, Liu J, Pang F, Zhang X. Diagnosis and management of pediatric cerebrospinal fluid leakage secondary to inner ear malformations: A report of 13 cases. *Int J Pediatr Otorhinolaryngol.* 2020;135:110049.