



Clinical Presentation of Carotid-Cavernous Fistula and Outcomes of Endovascular Balloon Embolization

✉ Tayyaba Gul Malik*, ✉ Muhammad Moin**

*Postgraduate Medical Institute/Lahore General Hospital, Lahore, Pakistan

**College of Ophthalmology and Vision Sciences, Lahore, Pakistan

Abstract

Objectives: To describe the clinical presentation of carotico-cavernous fistula (CCF) and outcomes of endovascular balloon embolization in a tertiary care center in a developing country.

Materials and Methods: This retrospective interventional case series included 18 patients who underwent endovascular balloon embolization from 2019 to 2022 at Lahore General hospital in Lahore, Pakistan. The analyzed data consisted of age, gender, cause and type of CCF, clinical presentation, diagnostic technique used, intervention, and the results of two-month follow-up. Patients with incomplete records and coil embolization were excluded. Digital subtraction angiography was done in all cases followed by endo-arterial balloon embolization. Procedures were carried out under general anesthesia via femoral artery approach. A single balloon was sufficient to close the fistula in all cases.

Results: There were 18 patients who met the inclusion criteria. Sixteen patients had direct CCF, and the mean age of the patients was 27.2 ± 12.6 years. Mean time of presentation after trauma was 7.89 ± 7.19 months. The male-to-female ratio was 8:1. Preoperative visual acuity was worse than 6/60 in 8 patients, between 6/60 and 6/18 in 7 patients, and better than 6/18 in 3 patients. The mean intraocular pressure was 16.06 ± 3.37 mmHg preoperatively and 14.83 ± 3.49 mmHg postoperatively ($p=0.005$). Endovascular embolization was successful in 15 patients (83.3%). One patient developed epidural hematoma as a complication of the procedure, which was drained later. There was no mortality related with the procedure.

Conclusion: Balloon embolization via the femoral artery is an efficient technique in direct as well as indirect CCF. It is safe and simple with very good results if performed in a timely manner.

Keywords: Carotid-cavernous fistula, balloon embolization, arterial embolization, digital subtraction angiography

Introduction

A carotid-cavernous fistula (CCF) refers to an abnormal connection between the internal carotid artery and the cavernous sinus. This connection disrupts normal blood flow dynamics, causing a decrease in arterial pressure and an increase in venous pressure. Consequently, an abnormal arteriovenous gradient develops, leading to reduced perfusion pressure. Clinically, CCF manifests as hypoxia, inflammation, and edema in the orbital and ocular tissues. The classic triad associated with direct CCF consists of the sudden onset of proptosis, the presence of a bruit, and conjunctival congestion, collectively known as the "Dandy triad".¹ While the clinical presentation of CCF, particularly direct CCF, may exhibit characteristic features, confirming the diagnosis requires neuroimaging. Digital subtraction angiography (DSA) is regarded as the gold standard for diagnosis and should be conducted before considering any potential interventions.²

As CCF is generally not life-threatening in most cases and the eye is at maximum risk, patients typically present to the ophthalmology department. The approach to treating CCF varies depending on the individual patient and is based on the clinical presentation at the time of diagnosis. Management options encompass conservative measures, endovascular intervention, open surgery, and radiosurgery. For cases of indirect CCF with normal vision, conservative treatment with vigilant monitoring for any signs of visual disturbance is often recommended. In other instances, treatment is pursued to alleviate symptoms, preserve vision, and close the fistula. At present, endovascular treatment is considered the primary choice for many direct CCF cases. It boasts a high rate of occlusion and a lower incidence

Cite this article as: Malik TG, Moin M. Clinical Presentation of Carotid-Cavernous Fistula and Outcomes of Endovascular Balloon Embolization. *Turk J Ophthalmol* DOI: 10.4274/tjo.galenos.2024.32457 [Ahead of Print].

Address for Correspondence: Tayyaba Gul Malik, Postgraduate Medical Institute/Lahore General Hospital, Lahore, Pakistan

E-mail: tayyabam@yahoo.com ORCID-ID: orcid.org/0000-0003-1040-7114

Received: 10.09.2023 Accepted: 26.04.2024

DOI: 10.4274/tjo.galenos.2024.32457



of complications.³ This method involves the use of detachable balloons, coils, stents, or liquid embolic agents such as Onyx.⁴

Endovascular embolization can be performed through either the transarterial or transvenous route. Both approaches are effective, but in situations involving vascular fragility, such as Ehlers-Danlos syndrome, the transvenous route is recommended to minimize the risk of arterial injury.⁵

Endovascular embolization is not commonly performed in Pakistan, leading to limited available data regarding the outcomes of this treatment modality.⁶ In the United States, coil embolization has replaced balloon embolization. However, in developing countries like Pakistan, balloon embolization remains a safe and effective first-line treatment. Despite its lower prevalence, it is considered a simple and safe approach. This case series presents the results of balloon embolization in 18 patients, including demographic data and success rates.

Materials and Methods

This study was a retrospective interventional case series that included the records of 18 patients with either direct or indirect CCF. The patients underwent endovascular balloon embolization between 2018 and 2022 at Lahore General Hospital in Lahore, Pakistan. The research received approval from the U.S. Department of Health and Human Services (HHS) (certificate ref. no: OSP-IRB/022-2022, date: 31.01.2022), and adherence to the Declaration of Helsinki was observed for the publication of human data.

The collected data included various parameters such as age, gender, cause and type of CCF, clinical presentation, visual status, intraocular pressure (IOP), fundus findings, diagnostic techniques used, interventions, and the results of two-month follow-up. Patients with incomplete records and those who underwent coil embolization were excluded.

All patients underwent detailed ocular examinations. Diagnostic tools such as computed tomography (CT), magnetic resonance imaging (MRI), and orbital B-scan ultrasound were employed to confirm the presence of the fistula, which was further verified through DSA. An interventional radiologist performed the endo-arterial embolization.

Procedures were conducted under general anesthesia using a femoral artery approach. A microcatheter with detachable balloon was directed towards the cavernous sinus, inflated to a size greater than the fistula for closure, and then detached. Notably, only one balloon was needed to close the fistula in this case series. DSA was repeated after embolization. Postoperatively, patients were advised against straining to prevent balloon displacement.

Statistical Analysis

The data were analyzed in Microsoft Excel and presented as percentage, mean, and standard deviation values. A paired t-test was applied to compare pre- and postoperative IOP values.

Results

There were 18 patients who met the inclusion criteria. Sixteen patients had direct CCF, the mean age of the patients

was 27.2±12.6 years, and the male-to-female ratio was 8:1. The mean time of presentation after trauma was 7.89±7.19 months. The commonest cause of CCF was trauma (n=14, 77.8%). Fracture of the skull bones was seen in 5 patients (27.8%). Other clinical features are presented in [Table 1](#).

[Figures 1](#) and [2](#) show the preoperative findings of a patient with posttraumatic CCF, while [Figure 3](#) shows a dilated superior ophthalmic vein on the right side in a CT scan. [Figure 4](#) shows pre- and post-embolization DSA results.

The patients' visual acuity and IOP values are presented in [Table 2](#). There was no significant difference in terms of the distribution of pre- and postoperative visual acuities ([Figure 5](#)).

Table 1. Clinical findings at the time of presentation

Clinical feature	n (%)
Nose bleed	8 (44.4)
Unconsciousness	8 (44.4)
Diplopia	7 (38.9)
Proptosis (mean: 5.94±2.67 mm)	18 (100)
Dystopia	14 (77.8)
Chemosis	13 (72.2)
Engorged vessels	17 (94.4)
Central retinal vein occlusion	6 (33.3)
Choroidal folds	3 (16.7)
Optic atrophy	5 (27.7)
Total ophthalmoplegia	6 (33.3)
Partial oculomotor nerve palsy	2 (11.1)
Oculomotor and trochlear nerve palsy	1 (5.6)
Abducens nerve palsy	1 (5.6)
Trochlear and abducens nerve palsy	1 (5.6)
Bruit	5 (27.7)

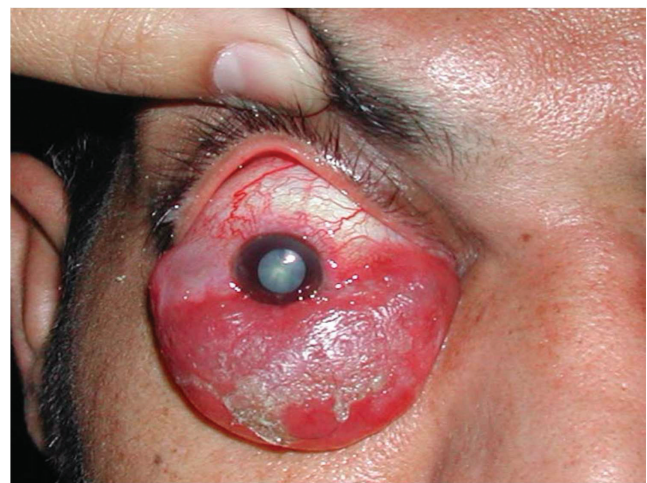

Figure 1. Posttraumatic right carotid-cavernous fistula with proptosis, chemosis, conjunctival prolapse, and cataract

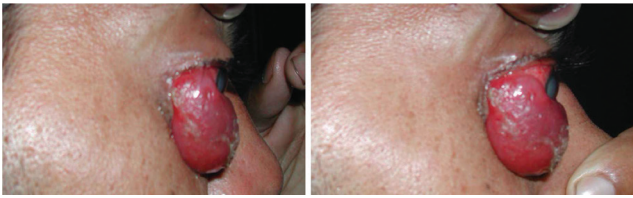

Figure 2. Positive Valsalva test

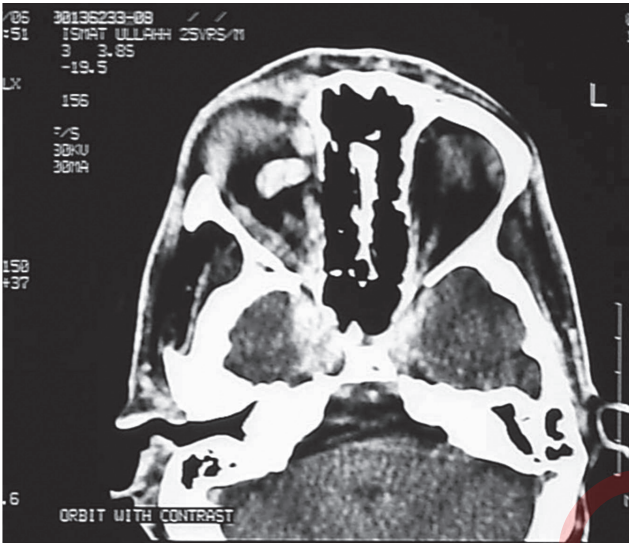

Figure 3. Dilated superior ophthalmic vein on computed tomography scan

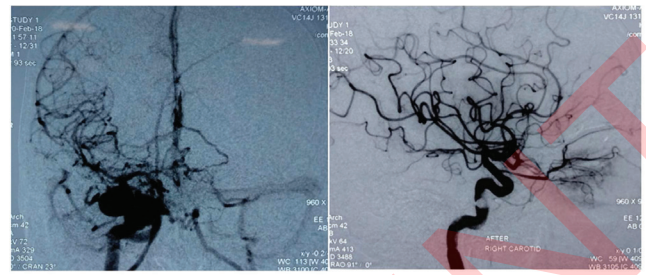


Figure 4. Digital subtraction angiography before balloon embolization (left panel) and after embolization (right panel)

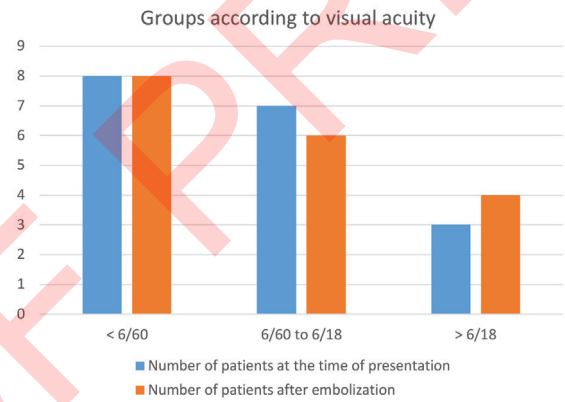


Figure 5. Comparison of visual acuity before and after balloon embolization

Table 2. Pre- and postoperative visual acuity and intraocular pressure

Patient	Preoperative IOP (mmHg)	Postoperative IOP (mmHg)	Visual acuity at presentation (Snellen)	Visual acuity after embolization (Snellen)
1	14	16	6/9	6/6
2	20	19	No light perception	No light perception
3	15	14	6/60	6/36
4	15	15	6/18	6/12
5	24	20	No light perception	No light perception
6	16	15	Counting fingers	Counting fingers
7	18	16	Light perception	No light perception
8	19	20	No light perception	No light perception
9	14	14	6/18	6/18
10	12	11	6/12	6/9
11	10	8	Hand movements	Hand movements
12	18	17	Counting fingers	Counting fingers
13	19	18	No light perception	No light perception
14	16	14	6/9	6/6
15	14	13	6/36	6/60
16	18	17	6/36	6/24
17	12	10	6/18	6/18
18	15	10	6/36	6/36

IOP: Intraocular pressure

Preoperatively, there were 8 patients with visual acuity worse than 6/60, 7 patients with visual acuity of 6/60 to 6/18, and 3 patients with visual acuity better than 6/18. There was no significant improvement in post-embolization visual acuity. The mean IOP was 16.06 ± 3.37 mmHg preoperatively and 14.83 ± 3.49 mmHg postoperatively ($p=0.0046$).

Endovascular embolization was successful in 15 patients (83.3%). Among the other three, one patient developed epidural hematoma as a complication of the procedure, which was drained later. The other two had very large fistulas which resulted in failure of the procedure. There was no mortality related to the procedure.

Discussion

CCF is a complex condition with diverse etiologies, pathogenesis, presentations, and radiographic features, necessitating various treatment strategies. The condition is relatively uncommon, especially outside of tertiary care centers with neurological facilities, making it challenging to determine its exact incidence. Notably, traumatic brain injuries are reported to contribute to 0.2% to 4% of CCF cases.^{7,8}

In our case series, 77% of the patients presented with traumatic CCF following closed or penetrating head injuries and fractures at the base of the skull. The majority of these cases occurred in males, with a male-to-female ratio of 8:1 in our series. This may be attributed to a higher prevalence of outdoor trauma in males. Interestingly, these findings differ from those reported in a study by Alexander et al.⁹ in which the majority of patients were females (78.3%) and the mean age was 61 years. However, in contrast to our study, Alexander et al.⁹ included only patients with indirect fistulas. The mean duration from the onset of symptoms to diagnosis in our study was 234 days, providing insight into the delayed recognition of CCF in our patient cohort.

In another series reported by Iampreechakul et al.¹⁰, a different demographic profile was observed, with a male-to-female ratio of 1:2 and a mean age of 47.3 years, contrasting with the younger patient population in our study (mean age 27.2 ± 12.6 years). Despite these differences, the percentage of traumatic CCF in their series (71.7%) closely resembled our findings (77.8%).

Permana et al.⁴ conducted a study involving 28 patients who underwent endovascular treatment. In this cohort, there was a female preponderance, with 15 females (54%) and 13 males (46%). Notably, they included patients with traumatic CCF. The presence of cephalic bruit was reported in 28% of their cases, a figure close to our percentage of 27.7%. These variations in demographic characteristics and clinical features highlight the diverse nature of CCF and underscore the importance of considering multiple factors when formulating treatment strategies.

The literature describes anterior and posterior patterns of CCF based on drainage. The anterior pattern typically presents with ocular signs, while the posterior pattern may manifest

as a “white eye” associated with isolated ocular nerve palsy. Diagnosing the posterior drainage pattern can be challenging without neuroimaging, as ocular signs may be less apparent.

Some patients with CCF may present with raised IOP due to increased episcleral venous pressure, ciliary body edema, or neovascularization secondary to ischemia. Interestingly, in this study, 33.3% of patients had central retinal vein occlusion associated with CCF. Although not observed in our series, rare complications of CCF include retinal detachment, vitreous hemorrhage, and choroidal effusions.¹¹ These findings emphasize the diverse clinical presentations and potential complications associated with CCF, reinforcing the need for comprehensive evaluation and neuroimaging when suspecting this condition.

Diagnostic techniques for CCF have significantly advanced in recent years. On MRI, CCF is characterized by proptosis, extraocular muscle enlargement, and a dilated superior ophthalmic vein. The dilated superior ophthalmic vein is typically observed in 86%-100% of cases using contrast-enhanced CT and 75%-100% using T1-weighted post-contrast MRI. CT scans also provide the added advantage of easily visualizing fractures. Other neuroimaging techniques such as CT angiography (CTA) and magnetic resonance angiography (MRA) are employed for diagnosis. The reported sensitivities for CTA, MRA, and DSA are 87%, 80%, and 94.4%, respectively.^{12,13} In this study, we used DSA, which is considered the gold standard for diagnosing and classifying CCF. These improved diagnostic modalities enhance the accuracy and efficiency of identifying and classifying CCF, allowing for more precise clinical management.

In our series, we specifically included patients who underwent balloon embolization, and our success rate reached 83.3%. This success rate aligns well with findings from another study, where the success rate for CCF treatments ranged from 75% to 88%.¹⁴ Notably, technical challenges during the procedure, such as insufficient embolization due to early balloon detachment, balloon deflation, or rupture, did not occur in any of the 15 successful cases out of the total 18 in our study. These favorable outcomes suggest the effectiveness of balloon embolization in the management of CCF in our patient series.

Another study conducted at Aga Khan Medical University in Pakistan included 26 patients, 20 males and 6 females, with a mean age of 31.4 ± 12.6 years.⁶ This study exhibited several similarities to our case series, particularly in terms of the male predominance. However, their reported success rate was higher than that in our series. The variance in success rates could be attributed to the fact that the Aga Khan study involved repeated sessions for four patients who were unsuccessful in the initial attempt.⁶ In contrast, our study only included cases treated successfully in the primary surgical intervention.

The complication rate in our study was 5.5%, whereas the Aga Khan study reported a higher complication rate of 15.3%.⁶ After a 2-month follow-up period, symptom resolution was observed but there was no improvement in vision. These findings underscore the importance of considering the approach and potential complications when evaluating the outcomes of endovascular treatments for CCF.

Given the anatomical proximity of the cavernous sinus to the cranial nerves, CCF often presents with associated nerve palsies. Abducens nerve palsy is reported in 50%-80% of cases, oculomotor nerve palsy in 67%, and trochlear nerve palsy in 49%.¹⁵ In our series, 33% of cases exhibited complete ophthalmoplegia. Among single nerve palsies, the third nerve was affected in 11%, and sixth nerve palsy occurred in 5.6%. Combined third and fourth nerve palsy or fourth and sixth nerve palsy each accounted for 5.6%. Notably, the abducens nerve, located within the cavernous sinus, is more susceptible to injury compared to other intracavernous nerves. However, in real-life scenarios, the third nerve is more commonly affected. It is crucial to acknowledge that nerve palsies can also result from the embolization process. Teng et al.¹⁶ reported a rare complication associated with migration of the balloon during embolization, leading to iatrogenic ophthalmoplegia. These findings highlight the intricacies and potential complications associated with CCF and its management, underscoring the need for careful consideration of cranial nerve involvement during diagnosis and treatment.

In our case series, proptosis was observed in 100% of cases, and additional clinical features included engorged ocular vessels, chemosis, dystopia, nosebleeds, central retinal vein occlusion, choroidal folds, and optic atrophy. Our failure rate was 3 out of 18 cases, amounting to 16.7%. It is noted that the failure rate tends to increase with an extended interval between trauma and treatment. In our study, the mean time of presentation was 7.89 ± 7.19 months. Another factor contributing to failure is the size of the fistula; if it exceeds the inflated balloon size, it can result in treatment failure. These considerations emphasize the importance of timely intervention and careful assessment of fistula characteristics for successful outcomes in the management of CCF.

Gao et al.¹⁷ presented a substantial series of 188 patients who underwent balloon embolization, with a high success rate of 96.8% (n=182). The angiographic occlusion rate reached 97.3%. Notably, the study reported three cases of balloon rupture attributed to basal fracture bone pieces. The research underscored the significance of the disease course and advanced age, noting that cavernous sinus enlargement due to bone resorption secondary to flow can contribute to procedural failure.

Recurrence is also documented in the literature, with multivariate logistic regression analysis revealing that incomplete embolization is a risk factor for recurrence (odds ratio [OR]: 16.63, 95% confidence interval [CI]: 1.74-159.33, $p=0.015$).¹⁸ However, in our study with limited follow-up, no recurrence was observed in the 15 cases that underwent successful embolization. These findings emphasize the need for a thorough understanding of the factors influencing the success of balloon embolization and recurrence in the management of CCF.

In a comprehensive review including 57 studies and 1575 patients, transarterial embolization of CCF resulted in complete closure in 93.93% of direct fistulas and 81.51% of indirect fistulas.¹⁹ Transvenous embolization, on the other hand, led

to closure in 91.67% of direct CCFs and 86.03% of indirect CCFs. Notably, there were no statistically significant differences between the two routes for direct CCFs (OR: 1.42, 95% CI: 0.23-8.90, $I^2: 0.0\%$) or indirect CCFs (OR: 0.62, 95% CI: 0.31-1.23, $I^2: 0.0\%$). These findings highlight the comparable efficacy of transarterial and transvenous embolization routes in achieving closure of both direct and indirect CCF.

In an additional series that encompassed both traumatic and spontaneous fistulas, a remarkable 100% closure of fistulas was achieved.²⁰ Out of the 25 cases, 20 were successfully closed in a single session, four required two sessions, and one case spontaneously closed. Unlike our case series, this study employed a combination of arterial and venous approaches for intervention. Their treatment modalities included coils, stents, detachable balloons, n-butyl cyanoacrylate, and combined embolization.

The intervention strategy varies, suggesting that different embolization techniques and materials are employed based on the size and nature of the fistula. Some authors recommend balloon embolization for medium and large fistulas, while coil embolization is suggested for smaller fistulas.²¹ In cases where CCF closure is not achieved, occlusion of the affected artery is also recommended.

Although angiographic closure of CCF is typically excellent after embolization, improvement in visual acuity is contingent upon the preintervention status. However, there is often an immediate postoperative improvement in bruit, and other ocular symptoms tend to regress over the course of weeks. These diverse approaches and outcomes underscore the individualized nature of CCF management and the importance of tailoring interventions based on the specific characteristics of each case.

The strength of this series lies in its contribution to the limited available data from developing countries like Pakistan regarding CCF management. This case series adds valuable insights to the literature from a third-world perspective, where medical and health facilities may be scarce. By providing information and experiences from a region with unique healthcare challenges, this series helps broaden the understanding of CCF and its management in diverse healthcare settings. It may contribute to the development of more context-specific approaches to diagnosis and treatment, potentially benefiting patients in similar regions with limited medical resources.

Study Limitations

This study has several limitations, primarily due to its retrospective nature. The follow-up duration of only two months is relatively short, potentially limiting the ability to assess long-term outcomes and recurrence rates. The sample size is also acknowledged as small, but given the rarity of CCF, it was considered acceptable. However, it is essential to recognize that larger sample sizes would provide a more robust basis for drawing conclusions.

To address these limitations and enhance the understanding of CCF management, further research involving controlled and randomized trials is recommended. These studies could provide more comprehensive insights into the efficacy and safety of

different treatment modalities and enable a more thorough exploration of long-term outcomes and potential complications.

Conclusion

In conclusion, balloon embolization is an efficient technique for the management of CCF, especially in low-resourced countries. This approach is characterized by its safety, simplicity, and demonstrated effectiveness, particularly when performed in a timely manner. The results from this study add to the limited data from a third-world country like Pakistan. While recognizing the retrospective nature and other limitations of the study, the findings underscore the potential benefits of balloon embolization in CCF cases. Further research, including controlled trials and larger sample sizes, would be valuable to deepen our understanding and refine the approach to CCF management.

Ethics

Ethics Committee Approval: U.S. Department of Health and Human Services (HHS) (certificate ref. no: OSP-IRB/022-2022, date: 31.01.2022).

Informed Consent: Obtained.

Authorship Contributions

Surgical and Medical Practices: T.G.M., M.M., Concept: T.G.M., M.M., Design: T.G.M., M.M., Data Collection or Processing: T.G.M., M.M., Analysis or Interpretation: T.G.M., M.M., Literature Search: T.G.M., Writing: T.G.M.

Conflict of Interest: No conflict of interest was declared by the authors.

Financial Disclosure: The authors declared that this study received no financial support.

References

- Joshi DK, Singh DD, Garg DD, Singh DH, Tandon DM. Assessment of clinical improvement in patients undergoing endovascular coiling in traumatic carotid cavernous fistulas. *Clin Neurol Neurosurg*. 2016;149:46-54.
- Williams ZR. Carotid-Cavernous Fistulae: A Review of Clinical Presentation, Therapeutic Options, and Visual Prognosis. *Int Ophthalmol Clin*. 2018;58:271-294.
- Gemmete JJ, Ansari SA, Gandhi DM. Endovascular techniques for treatment of carotid-cavernous fistula. *J Neuroophthalmol*. 2009;29:62-71.
- Permana GI, Suroto NS, Al Fauzi A. Clinical Improvement of Patients with Endovascular Treatment in the Traumatic Carotid-Cavernous Fistula. *Asian J Neurosurg*. 2021;16:376-380.
- Ide S, Kiyosue H, Tokuyama K, Hori Y, Sagara Y, Kubo T. Direct Carotid Cavernous Fistulas. *J Neuroendovasc Ther*. 2020;14:583-592.
- Hamid RS, Tanveer-ul-Haq, Shamim MS, Kazim SF, Salam B. Endovascular approach as primary treatment for traumatic carotid cavernous fistula: local experience from Pakistan. *J Pak Med Assoc*. 2011;61:989-993.
- Liang W, Xiaofeng Y, Weiguo L, Wusi Q, Gang S, Xuesheng Z. Traumatic carotid cavernous fistula accompanying basilar skull fracture: a study on the incidence of traumatic carotid cavernous fistula in the patients with basilar skull fracture and the prognostic analysis about traumatic carotid cavernous fistula. *J Trauma*. 2007;63:1014-1020.
- Ono K, Oishi H, Tanoue S, Hasegawa H, Yoshida K, Yamamoto M, Arai H. Direct carotid-cavernous fistulas occurring during neurointerventional procedures. *Interv Neuroradiol*. 2016;22:91-96.
- Alexander MD, Halbach VV, Hallam DK, Cooke DL, Ghodke B, Dowd CF, Amans MR, Herts SW, Higashida RT, Meyers PM. Relationship of clinical presentation and angiographic findings in patients with indirect cavernous carotid fistulae. *J Neurointerv Surg*. 2019;11:937-939.
- Iampreechakul P, Tirakotai W, Tanpun A, Wattanasen Y, Lertbusayanukul P, Siriwimonmas S. Spontaneous resolution of direct carotid-cavernous fistulas: case series and literature review. *Interv Neuroradiol*. 2019;25:71-89.
- Chaudhry IA, Elkhamry SM, Al-Rashed W, Bosley TM. Carotid cavernous fistula: ophthalmological implications. *Middle East Afr J Ophthalmol*. 2009;16:57-63.
- Adam CR, Shields CL, Gutman J, Kim HJ, Hayek B, Shore JW, Braunstein A, Levin E, Winn BJ, Vrcek I, Mancini R, Linden C, Choe C, Gonzalez M, Altschul D, Ortega-Gutierrez S, Paramasivam S, Fifi JT, Berenstein A, Durairaj V, Shinder R. Dilated Superior Ophthalmic Vein: Clinical and Radiographic Features of 113 Cases. *Ophthalmic Plast Reconstr Surg*. 2018;34:68-73.
- Henderson AD, Miller NR. Carotid-cavernous fistula: current concepts in aetiology, investigation, and management. *Eye (Lond)*. 2018;32:164-172.
- Lu X, Hussain M, Ni L, Huang Q, Zhou F, Gu Z, Chen J, Ding Y, Xu F. A comparison of different transarterial embolization techniques for direct carotid cavernous fistulas: a single center experience in 32 patients. *J Vasc Interv Neurol*. 2014;7:35-47.
- Holland IJ, Mitchell Ranzcr K, Harrison JD, Brauchli D, Wong Y, Sullivan TJ. Endovascular treatment of carotid-cavernous sinus fistulas: ophthalmic and visual outcomes. *Orbit*. 2019;38:290-299.
- Teng MM, Chang CY, Chiang JH, Lirng JE, Luo CB, Chen SS, Chang FC, Guo WY. Double-balloon technique for embolization of carotid cavernous fistulas. *AJNR Am J Neuroradiol*. 2000;21:1753-1756.
- Gao BL, Wang ZL, Li TX, Xu B. Recurrence risk factors in detachable balloon embolization of traumatic direct carotid cavernous fistulas in 188 patients. *J Neurointerv Surg*. 2018;10:704-707.
- Zhenxing Y, Yangyang S, Fangqin S, Dejun H, Zongzheng L. Endovascular treatment of traumatic direct carotid-cavernous fistulas: a retrospective case series study of 54 patients. *Int J Cerebrovasc Dis*. 2020;8:605-612.
- Texakalidis P, Tzoumas A, Xenos D, Rivet DJ, Reavey-Cantwell J. Carotid cavernous fistula (CCF) treatment approaches: A systematic literature review and meta-analysis of transarterial and transvenous embolization for direct and indirect CCFs. *Clin Neurol Neurosurg*. 2021;204:106601.
- Sanal B, Nas OF, Korkmaz M, Erdogan C, Hakyemez B. Endovascular Treatment in Traumatic and Spontaneous Carotid Cavernous Fistulas: with Different Embolization Agents and via Various Vascular Routes. *J Vasc Interv Neurol*. 2018;10:18-24.
- Thohar Arifin M, Ali Akbar M, Illyasa W, Tsaniadi Prihastomo K. Neuro-Endovascular Intervention in Traumatic Carotico-Cavernous Fistulae: A Single-Center Experience. *Int J Gen Med*. 2020;13:917-925.