



# Quilty Effect after Extracorporeal Photopheresis in a Patient with Severe Refractory Cardiac Allograft Rejection

## Şiddetli Kardiyak Allogreft Rejeksiyonu Olan Bir Hastada Ekstrakorporeal Fotoferesiz Sonrası Quilty Etkisi

Özgür Ulaş Özcan<sup>1</sup>, Tamer Sayın<sup>1</sup>, Gürbey Soğut<sup>1</sup>, Aylin Heper<sup>2</sup>, Hüseyin Göksülük<sup>1</sup>, Veysel Kutay Vurgun<sup>1</sup>, Cansın Tulunay Kaya<sup>1</sup>, Elif Ezgi Üstün<sup>1</sup>, Osman İlhan<sup>3</sup>, Çetin Erol<sup>1</sup>

<sup>1</sup>Ankara University Faculty of Medicine, Department of Cardiology, Ankara, Turkey

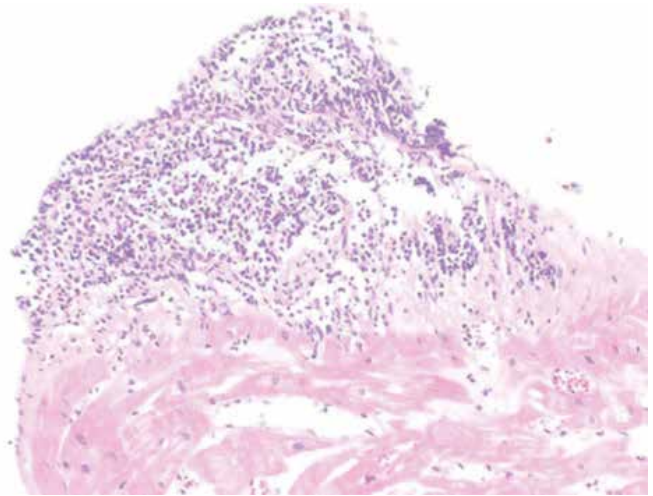
<sup>2</sup>Ankara University Faculty of Medicine, Department of Pathology, Ankara, Turkey

<sup>3</sup>Ankara University Faculty of Medicine, Department of Hematology, Ankara, Turkey

### To the Editor,

Solid organ transplant rejection is still a problem despite the use of immunosuppressive therapy. The currently available regimens for transplant rejection may predispose patients to malignancies such as nonmelanoma skin cancers and opportunistic infections [1]. Extracorporeal photopheresis (ECP) is a leukapheresis-based immunomodulatory therapy in which lymphocytes collected from the patient are incubated with 8-methoxypsoralen, a photosensitizing agent, in the presence of UV-A radiation and then reinfused into the patient [2]. Here we report a case of severe refractory cardiac allograft rejection that was successfully treated by ECP.

A 47-year-old man presented with severe decompensated heart failure and hemodynamic compromise 13 months after heart transplantation. Ejection fraction was 25% with transthoracic echocardiography. After immediate therapy with positive inotropes and diuretics, diagnostic coronary angiography, right heart catheterization, and endomyocardial biopsy were performed. Coronary angiography revealed no obstructive coronary artery disease. The endomyocardial biopsy showed perivascular and interstitial lymphocytic inflammatory infiltrate with sparse eosinophils in 2 separate locations that were identified as moderate acute cellular rejection (ISHLT 2R). Cyclosporin A level was 150 ng/mL. Methylprednisolone pulses (1 g/day) for 3 days and equine anti-thymocyte globulin (Atgam) at 15 mg/kg/day were administered for induction therapy. Due to the deterioration of clinical status and intervening pneumonia, immunosuppressive therapy was ceased and ECP was planned.



**Figure 1.** Endomyocardial biopsy specimen demonstrated endocardial lymphocytic aggregate.

ECP sessions were performed twice a week for 2 months. After therapy the patient became minimally symptomatic with an ejection fraction of 50%. Repeated endomyocardial biopsy demonstrated lymphocytic aggregation confined to the endocardium, which was interpreted as Quilty effect, and remission of acute cellular rejection (Figure 1). The patient was discharged asymptotically. Informed consent was obtained.

Transplant rejection of solid organs remains an issue despite modern immunosuppressive regimens. The rate of rejection is 25% during the first year after heart transplantation [1].

Address for Correspondence: Özgür Ulaş ÖZCAN, M.D.,  
Ankara University Faculty of Medicine, Department of Cardiology, Ankara, Turkey  
Phone: +90 312 508 24 10 E-mail: ozgurulasozcan@yahoo.com.tr

Received/Geliş tarihi : February 3, 2014  
Accepted/Kabul tarihi : June 9, 2014

Acute cell-mediated rejection is characterized by infiltration of T cells directed against the allograft [3]. Biopsy grades of >2 R warrant accentuation of immunosuppression [4]. 'Quilty effect' refers to lymphocytic infiltration in the endocardium of cardiac allografts. Although the clinical significance of the Quilty effect is not fully known, it is understood that the Quilty effect does not reflect transplant rejection.

Hemodynamic compromise, persistence or recurrence of rejection, and side effects or complications associated with intensive immunosuppressive therapy necessitate alternative approaches for handling rejection. ECP is indicated for prevention of acute and chronic rejection of cardiac transplants [5,6,7]. Favorable effects were also demonstrated for secondary prevention among patients with a history of acute rejection [8]. ECP is a relatively safe procedure. Serious side effects are rarely reported, most of which are related to hypotension and anemia secondary to volume changes and blood loss during the procedure. Risks of opportunistic infections or secondary malignancies have not been increased because of ECP [9]. Small studies demonstrated the benefits of ECP for primary and secondary prevention of cardiac allograft rejection, but treatment for acute refractory cardiac allograft rejection is questionable because of the scarcity of data. We suggest the use of ECP for this compelling condition.

#### Conflict of Interest Statement

The authors of this paper have no conflicts of interest, including specific financial interests, relationships, and/or affiliations relevant to the subject matter or materials included.

**Key Words:** Allograft, Extracorporeal photopheresis, Heart transplantation, Quilty effect, Rejection

**Anahtar Sözcükler:** Allogreft, Ekstrakorporeal fotoferez, Kalp transplantasyonu, Quilty etkisi, Rejeksiyon

#### References

1. Taylor DO, Stehlik J, Edwards LB, Aurora P, Christie JD, Dobbels F, Kirk R, Kucheryavaya AY, Rahmel AO, Hertz MI. Registry of the International Society for Heart and Lung Transplantation: Twenty-sixth Official Adult Heart Transplant Report-2009. *J Heart Lung Transplant* 2009;28:1007-1022.
2. Marques MB, Schwartz J. Update on extracorporeal photopheresis in heart and lung transplantation. *J Clin Apher* 2011;26:146-151.
3. Stewart S, Winters GL, Fishbein MC, Tazelaar HD, Kobashigawa J, Abrams J, Andersen CB, Angelini A, Berry GJ, Burke MM, Demetris AJ, Hammond E, Itescu S, Marboe CC, McManus B, Reed EF, Reinsmoen NL, Rodriguez ER, Rose AG, Rose M, Suci-Focia N, Zeevi A, Billingham ME. Revision of the 1990 working formulation for the standardization of nomenclature in the diagnosis of heart rejection. *J Heart Lung Transplant* 2005;24:1710-1720.
4. Costanzo MR, Dipchand A, Starling R, Anderson A, Chan M, Desai S, Fedson S, Fisher P, Gonzales-Stawinski G, Martinelli L, McGiffin D, Smith J, Taylor D, Meiser B, Webber S, Baran D, Carboni M, Dengler T, Feldman D, Frigerio M, Kfoury A, Kim D, Kobashigawa J, Shullo M, Stehlik J, Teuteberg J, Uber P, Zuckermann A, Hunt S, Burch M, Bhat G, Canter C, Chinnock R, Crespo-Leiro M, Delgado R, Dobbels F, Grady K, Kao W, Lamour J, Parry G, Patel J, Pini D, Towbin J, Wolfel G, Delgado D, Eisen H, Goldberg L, Hosenpud J, Johnson M, Keogh A, Lewis C, O'Connell J, Rogers J, Ross H, Russell S, Vanhaecke J. International Society of Heart and Lung Transplantation Guidelines. The International Society of Heart and Lung Transplantation Guidelines for the care of heart transplant recipients. *J Heart Lung Transplant* 2010;29:914-956.
5. Szczepiorkowski ZM, Winters JL, Bandarenko N, Kim HC, Linenberger ML, Marques MB, Sarode R, Schwartz J, Weinstein R, Shaz BH. Apheresis Applications Committee of the American Society for Apheresis. Guidelines on the use of therapeutic apheresis in clinical practice--evidence-based approach from the Apheresis Applications Committee of the American Society for Apheresis. *J Clin Apher* 2010;25:83-177.
6. Barr ML, Meiser BM, Eisen HJ, Roberts RF, Livi U, Dall'Amico R, Dorent R, Rogers JG, Radovancevic B, Taylor DO, Jeevanandam V, Marboe CC. Photopheresis for the prevention of rejection in cardiac transplantation. Photopheresis Transplantation Study Group. *N Engl J Med* 1998;339:1744-1751.
7. Barr ML, Baker CJ, Schenkel FA, McLaughlin SN, Stouch BC, Starnes VA, Rose EA. Prophylactic photopheresis and chronic rejection: effects on graft intimal hyperplasia in cardiac transplantation. *Clin Transplant* 2000;14:162-166.
8. Kirklin JK, Brown RN, Huang ST, Naftel DC, Hubbard SM, Rayburn BK, McGiffin DC, Bourge RB, Benza RL, Tallaj JA, Pinderski LJ, Pamboukian SV, George JF, Marques M. Rejection with hemodynamic compromise: objective evidence for efficacy of photopheresis. *J Heart Lung Transplant* 2006;25:283-288.
9. Hart JW, Shiue LH, Shpall EJ, Alousi AM. Extracorporeal photopheresis in the treatment of graft-versus-host disease: evidence and opinion. *Ther Adv Hematol* 2013;4:320-334.