

***HNRNPC-RARA* Fusion Gene in a Case with Acute Promyelocytic Leukemia Lacking *PML-RARA* Rearrangement Presenting with Abundant Hemophagocytosis**

Aşırı Hemofagositozla Ortaya Çıkan ve *PML-RARA* mutasyonu Taşımayan Bir Akut Promiyelositik Lösemi Olgusunda *HNRNPC-RARA* Füzyon Geni

✉ Jing Tan¹, ✉ Yonggang Zhang²

¹Chengdu Third People's Hospital, Department of Haematology, Chengdu, China

²Center for Stem Cell Research and Application, Institute of Blood Transfusion, Chinese Academy of Medical Sciences and Peking Union Medical College (CAMS and PUMC), Chengdu, Sichuan, China

To the Editor,

A 41-year-old Chinese man was admitted to our hospital with pancytopenia in May 2020. A bone marrow (BM) smear showed hypercellularity with 83% hypergranular promyelocytes with azurophilic granules and Auer rods (Figure 1A). Furthermore, an increased number of macrophages with marked hemophagocytosis was seen (Figure 1B). Flow cytometry revealed blast cells positive for CD33, CD13, CD117, CD123, CD9, MPO, and weak CD56, but the results were negative for CD34, CD38, HLA-DR, and T- or B-cell markers. Coagulation screening showed low fibrinogen and elevated D-dimer. Screening results for the Epstein-Barr virus, cytomegalovirus, and *Mycoplasma* were negative. Although abundant hemophagocytosis was present, the levels of triglycerides, serum ferritin, NK cell activity, and soluble CD25 did not support the diagnosis of hemophagocytic syndrome. Reverse-transcription polymerase chain reaction analysis of the BM was negative for *PML-RARA*, *NPM-RARA*, *NuMA-RARA*, *FIPIL-RARA*, *PLZF-RARA*, *PPK-RARA*, and *STAT5b-RARAWRE*. The patient was resistant to all-trans retinoic acid and arsenic trioxide induction and he died of cerebral hemorrhage on day 79.

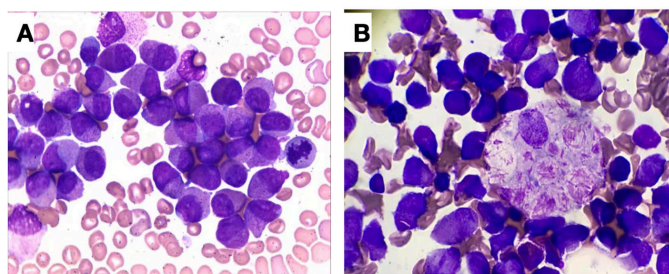


Figure 1. Morphological analysis of the bone marrow smear and identification of novel *RARA* fusions in a case of acute promyelocytic leukemia (APL) lacking *t(15;17) (q22; q12)/PML-RARA*. A) Bone marrow smear showing typical APL morphology with abundant cytoplasm and azurophilic microgranules. B) Bone marrow smear showing hemophagocytosis and macrophages engulfing clusters of Auer rods.

Whole-transcriptome RNA sequencing analysis with an Illumina HiSeq X device (Kindstar Global, Chengdu, China) detected only two novel types of *RARA*-related fusion transcripts categorized as *Homo sapiens heterogeneous nuclear ribonucleoprotein C (HNRNPC)*. Expected bands of approximately 300 bp (*HNRNPC-RARA*) and 270 bp (*RARA-HNRNPC*) were detected and the Sanger sequencing results also confirmed the existence of these two fusion transcripts (Figure 2A).

Genome-wide RNA profiling of the samples was performed for the patient with *HNRNPC-RARA* (i.e., the reported case), a patient with *PML/RARA*, and a healthy control. Endocytosis-related functional cluster genes were enriched in the patient with acute promyelocytic leukemia (APL) characterized by *HNRNPC-RARA* (Figure 2B). Interestingly, alternate mRNA splicing via spliceosome functional cluster genes showed more enrichment for the patient with *HNRNPC-RARA*. Similarly, RNA modification-related functional cluster genes were more enriched in the patient with *HNRNPC-RARA* (Figure 2C). These findings indicated that the *HNRNPC-RARA* translocation affects the functioning of the *HNRNPC* gene. Pathways in cancer, apoptosis, and endocytosis functional cluster genes were also more enriched in the patient with *HNRNPC-RARA* (Figure 2D).

Although the roles of the overexpression of *HNRNPC* in promoting the oncogenesis of solid tumors are well known [1], two cases were recently reported in which the *HNRNPC* gene was involved in APL via fusion with *RARA* [2,3]. These independent cases indicated that *HNRNPC-RARA* may constitute a novel recurrent fusion subtype of *RARA*-related APL and that *HNRNPC* may play an important role in the oncogenesis of leukemia.

In summary, we have reported *HNRNPC-RARA* as a novel recurrent *RARA* fusion gene in APL. *HNRNPC-RARA* has unique characteristics compared to *PML-RARA*, which indicates that *HNRNPC* may play an important role in the oncogenesis of APL. This novel case of *HNRNPC-RARA* APL may serve as a good model for further investigations of *HNRNPC*.

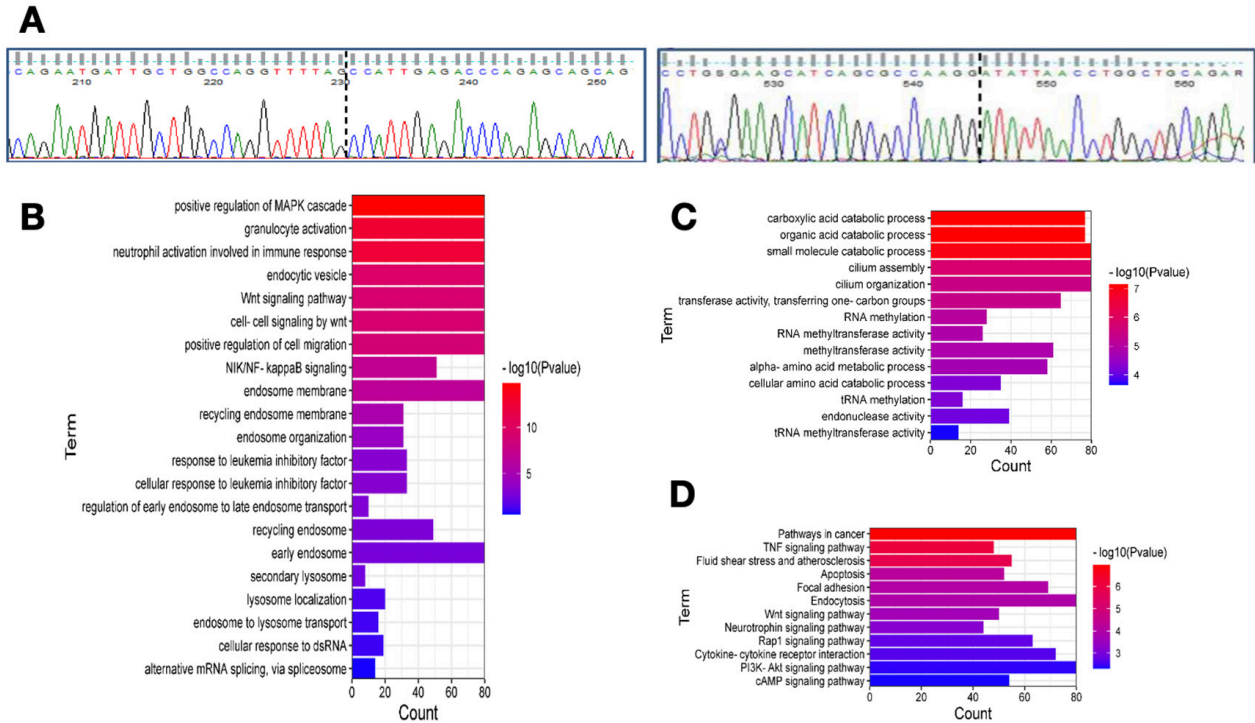


Figure 2. *HNRNPC-RARA* fusion changed the transcriptome of acute promyelocytic leukemia (APL) cells in the bone marrow. A) Partial nucleotide sequences surrounding the junctions of the 2 types of *HNRNPC-RARA* fusion. B-D) Functional cluster analysis showing that endocytosis-related functional cluster genes, mRNA splicing via spliceosome functional cluster genes, and RNA modification-related functional cluster genes were more highly enriched in the patient with *HNRNPC-RARA* compared to a patient with classic *PML-RARA* APL.

Keywords: Acute promyelocytic leukemia, Hemophagocytosis, *HNRNPC-RARA*, *PML-RARA*

Anahtar Sözcükler: Akut promyelositik lösemi, Hemofagositoz, *HNRNPC-RARA*, *PML-RARA*

Acknowledgment: We would like to thank the patient, Dr. Gui Ping Deng, for his high spirits in battling leukemia, which encouraged us to study this new variant of acute promyelocytic leukemia.

Ethics

Informed Consent: Written informed consent was obtained from the patient.

Authorship Contributions

Surgical and Medical Practices: J.T.; Concept: J.T.; Design: Y.Z.; Data Collection or Processing: Y.Z.; Analysis or Interpretation: Y.Z.; Literature Search: J.T., Y.Z.; Writing: J.T., Y.Z.

Conflict of Interest: The authors have no conflicts of interest to disclose.

Financial Disclosure: The authors received no specific funding for this work.

References

- Yang L, WenTao T, ZhiYuan Z, Qi L, YuXiang L, Peng Z, Ke L, XiaoNa J, YuZhi P, MeiLing J, QingYang F, GuoDong H, YueXiang W, JianMin X. Cullin-9/p53 mediates HNRNPC degradation to inhibit erastin-induced ferroptosis and is blocked by MDM2 inhibition in colorectal cancer. *Oncogene* 2022;41:3210-3221.
- Liu M, Zhao X, Pan W, Qian Z, Du M, Wang LM, Huang H, Xiao H. A novel *HNRNPC-RARA* fusion in acute promyelocytic leukaemia lacking *PML-RARA* rearrangement, sensitive to venetoclax-based therapy. *Br J Haematol* 2021;195:e123-e128.
- Ding W, Weng G, Wang Z, Guo Y, Wang M, Shen H, Chen S, Du X, Wen L. Case report: Identification of a novel *HNRNPC::RARG* fusion in acute promyelocytic leukemia lacking *RARA* rearrangement. *Front Oncol* 2022;12:1028651.



Address for Correspondence/Yazışma Adresi: Jing Tan, M.D., Chengdu Third People's Hospital, Department of Haematology, Chengdu, China
E-mail : 79468064@qq.com ORCID: orcid.org/0000-0002-4280-9858

Received/Geliş tarihi: May 18, 2023
Accepted/Kabul tarihi: June 14, 2023

DOI: 10.4274/tjh.galenos.2023.2023.0207



©Copyright 2023 by Turkish Society of Hematology Turkish Journal of Hematology, Published by Galenos Publishing House. Licensed under a Creative Commons Attribution-NonCommercial (CC BY-NC-ND) 4.0 International License.