

A Curious Tale of Missing Bone Segment

Nayak A.R. et al: A Curious Tale of Missing Bone Segment

Amiya Ranjan Nayak¹, Neelabh Nayan¹, Priyanka Naranje¹, Pradeep Kumar¹, Jasmita Dass², Mukul Aggarwal¹

¹India Institute of Medical Sciences, Department of hematology, New Delhi, India

²Sir Ganga Ram Hospital, Department of Hematology, New Delhi, India

Amiya Ranjan Nayak M.D., India Institute of Medical Sciences, Department of hematology, New Delhi, India

+919937196903

amiyanayak.bbsr@gmail.com, amiyanayak.08042@gmail.com

January 25, 2024

March 11, 2024

An elderly male sought consultation for mild pain in his right leg for around 4 months. He didn't have any prior medical ailments. Local examination was unremarkable. During investigations, bilateral lower limb X-ray (Figure 1A) showed absence of a segment of right fibula. His blood investigations revealed hypercalcemia (Sr. Calcium - 3.5 mmol/L), renal failure (Sr. Creatinine = 203.37 μ mol/L) and anemia (Hb of 56.5 g/L). Skeletal survey displayed multiple lytic lesions involving skull (Figure 1B), ribs, vertebra and other bones. Differential diagnosis included multiple myeloma and lytic bony metastasis. MRI of the legs (Figure 2) revealed an expansile heterogeneous solid mass involving medulla and cortex of the distal shaft of right fibula with cortical breach. Serum protein immunoelectrophoresis didn't show any M-band, but serum free light chain ratio was altered (82.62) with predominance of kappa light chain i.e 1408 mg/L. Lambda light chain level was 17.04 mg/L. Bone marrow examination demonstrated 69% plasma cells and upon immunohistochemistry 60% of the plasma cells were kappa restricted. A diagnosis of light chain multiple myeloma was established. The radiological illusion of missing bone segment was explained by the plasmacytoma. Around 80-90% of myeloma patients develop bone lesions during the course of their illness [1], with almost 60% of patients developing a pathological fracture during the disease course. [2] In our patient, the plasmacytoma had completely destroyed the bony cortex, however it didn't result in pathological fracture because fibula is a non-weight bearing bone.

References

1. Roodman GD. Mechanisms of bone metastasis. *N Engl J Med.* 2004;350(16):1655-1664. doi:10.1056/NEJMra030831
2. Melton LJ 3rd, Kyle RA, Achenbach SJ, Oberg AL, Rajkumar SV. Fracture risk with multiple myeloma: a population-based study. *J Bone Miner Res.* 2005;20(3):487-493. doi:10.1359/JBMR.041131

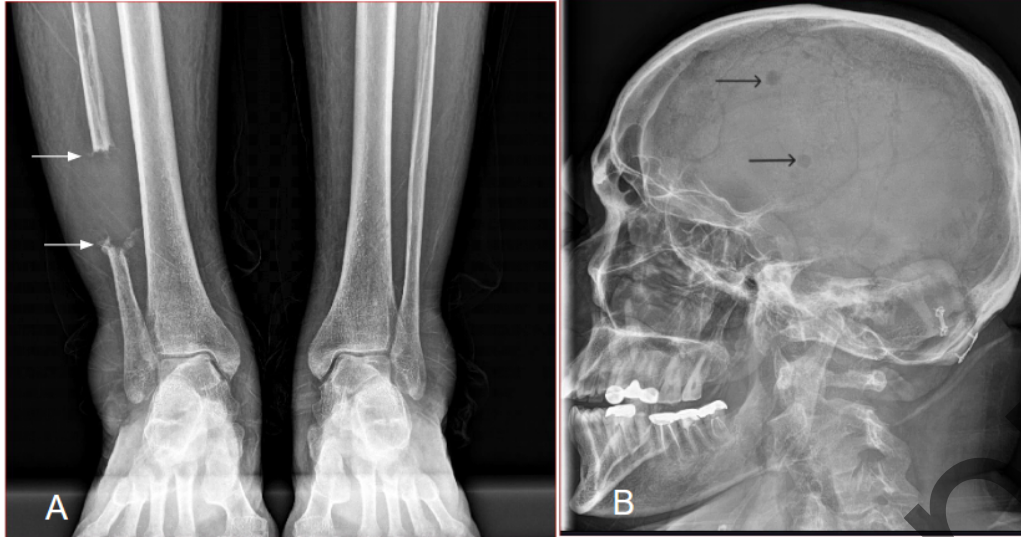


Figure 1. A. AP view of bilateral lower legs revealed a completely lytic lesion resulting in absence of a focal segment of distal fibula. The proximal and distal margins show irregularity and expansion (arrows). B. Radiograph of the skull (lateral view) shows punched out lytic lesions (arrows). Findings were suspicious for multiple myeloma or metastasis.

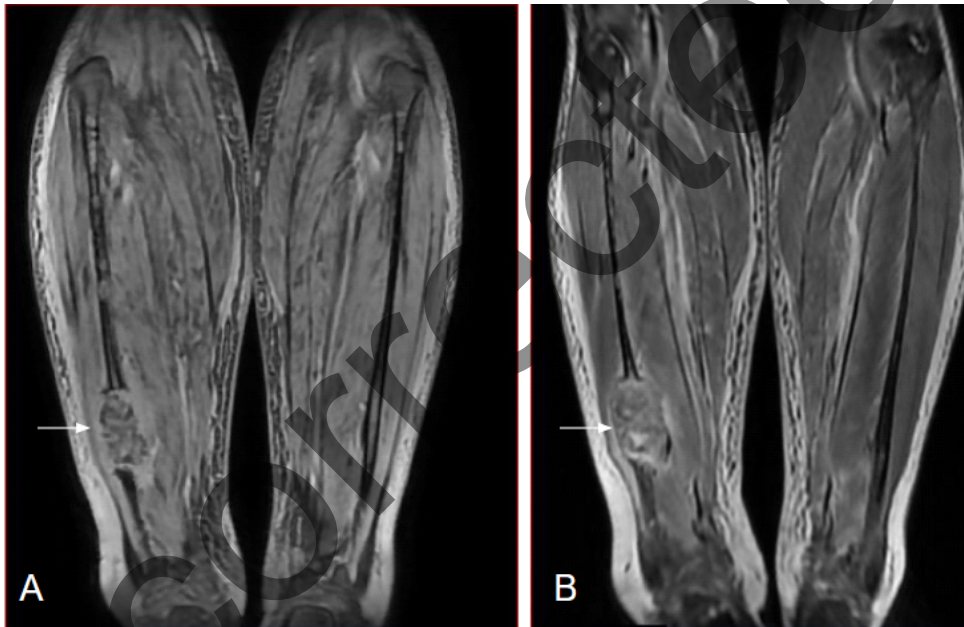


Figure 2. T1 weighted MRI (A) and T2 weighted MRI (B) images show expansile heterogeneous mass (arrows) in distal fibula with cortical breach and extension in surrounding soft tissue; features consistent with aggressive bone lesion which turned out to be myeloma.