
Primary Uterine Lymphoma: A Rare Cause of Postmenopausal Bleeding

Cem DANE, Banu DANE, Emine KALLI, Murat ERGİNBAŞ, Ahmet ÇETİN

Haseki Education and Research Hospital, Gynecology and Obstetrics, Istanbul, TURKEY

ABSTRACT

Although uterus and cervix infiltration is a frequent finding in the later stages of lymphomatous disease, non-Hodgkin's lymphoma (NHL) of the female genital tract is extremely rare. We present the case of a 63-year-old woman diagnosed with postmenopausal bleeding, Ann Arbor stage IE, primary, diffuse, large B-cell NHL of the uterus. Disease status was monitored with physical examination and imaging studies. We administered chemotherapy according to CHOP protocol (cyclophosphamide, adriamycin, vincristine, and prednisone). Primary pelvic NHL may present symptoms like other more common gynecologic cancers. It should be considered in the differential diagnosis of gynecologic malignancy. Our case emphasizes the importance of chemotherapy that can provide a control of the distant microscopic metastases.

Key Words: Lymphoma, Uterus, Bleeding.

ÖZET

Primer Uterus Lenfoması: Seyrek Görülen Bir Menopoz Sonrası Kanama Nedeni

Lenfomanın ileri evrelerinde uterus ve serviks infiltrasyonu sık bulgu ise de, kadın genital sistem non-Hodgkin-lenfoması çok nadirdir. Burada 63 yaşında postmenopozal kanama ile Ann Arbor Evre IE, primer, difüz, büyük B-hücreli uterus lenfoması tanısı konan bir hastayı sunmaktayız. Hasta CHOP protokolü verilerek tedavi edildi. Primer pelvik NHL, diğer jinekolojik kanserlere benzeyen belirtilerle gelir ve jinekolojik malignitelerin ayırıcı tanısında düşünülmelidir. Bu olgu kemoterapinin uzak mikroskobik metastazları kontrol etmesindeki önemi vurgulamaktadır.

Anahtar Kelimeler: Lenfoma, Uterus, Kanama.

Türk J Haematol 2004;21(1): 39-43

Received: 03.08.2003 **Accepted:** 04.12.2003

INTRODUCTION

Non-Hodgkin lymphoma (NHL) of the female genital tract as primary site is extremely rare. Secondary lymphomatous involvement of female reproductive organs has been reported as frequently as 40% in autopsy series; however, only 1% of primary NHL take place in the genital system^[1]. Although advanced NHL frequently involves the female genital tract, primary pelvic NHL is rare. The incidence of NHL has increased recently, however, with the rate of extranodal tumors increasing more than nodal tumors^[2]. The female genital tract is often secondarily involved by lymphoma in cases of disseminated disease, but is rarely the site of initial presentation. The first reported case of a primary NHL of the female genital tract was a vulvar case, described in 1937 by Taussig^[3]. In the case report, we describe the patient with a NHL of the female genital tract as the primary site of presentation.

A CASE REPORT

The patient was a 63-years-old gravid 4, para 4 woman who presented with increasing abdominal girth and postmenopausal bleeding. Her last period had been 14 years previously. The patient was taken no hormonal replacement therapy. Physical examination revealed marked enlargement of the uterus. Direct inspection did not reveal cervical mucosal abnormalities. Papanicolaou smears were negative. Biopsies of the cervix and currying of the endocervix and endometrium showed high-grade diffuse, large B-cell, non-Hodgkin's lymphoma (DLBCL). The DLBCL were composed of sheets of large neoplastic cells that infiltrated deeply through cervical stroma, frequently with interspersed residual collagen bundles. Endocervical glands were also surrounded and separated by sheets of lymphoma and frequently were dilated filled with mucin (Figure 1). Further immunohistochemical studies were conducted to specify the immune phenotype and genotype of the tumor. Tumor cells showed intensive CD20 (L26, a B-cell marker) positivity, but

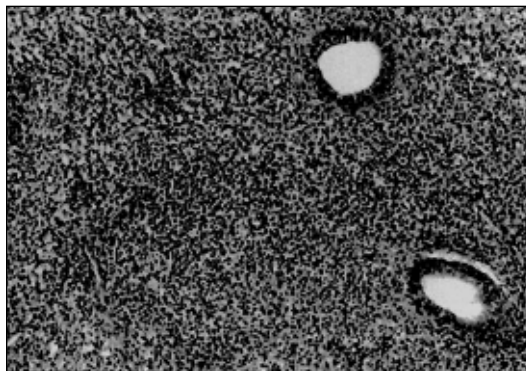


Figure 1. Photomicrograph was showing malignant lymphoma in the uterus (hematoxylin and eosin 100x).

CD45RO (UCHL-1, a T-cell marker) and CD7 immunostainings were negative. But there were many reactive T-cell with staining CD7 and CD45RO (+) in stroma. Eighty percent (80%) of the tumor cells showed intensive positivity to Ki-67 nuclear proliferative antigen. Pathologic examination revealed the final diagnosis of a primary, diffuse, large B-cell NHL of the uterus according to the WHO Classification. A complete clinical staging workup including CT scan of the abdomen and thorax, MRI of abdomen, abdominal ultrasonography, bone marrow biopsy and aspiration, and blood tests were carried out. Ultrasonography demonstrated lobulated uterine enlargement, with focal anechoic area (Figure 2). An MRI examination was showed full

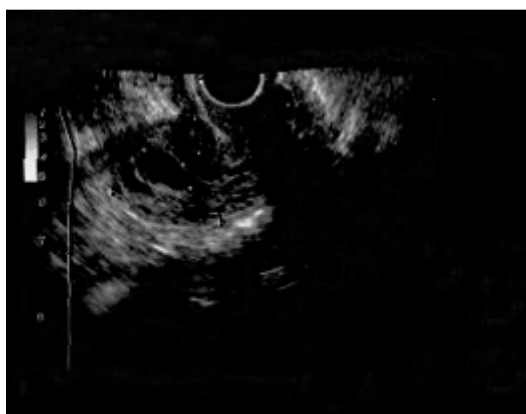

Figure 2. Ultrasonography demonstrated lobulated uterine enlargement, with focal anechoic area.

filling with endometrial cavity, approximately 6 x 5 x 3 cm in diameter. T1-weighted signal intensity was reported as hypointense, and T2-weighted signal intensity was high. There was lack of mucosal involvement. The tumor affected neither the cervical stroma nor the junctional zone of the uterus. The lesion showed a minimal heterogeneous enhancement, internal septa and linear contrast fixation was found after intravenous (i.v.) contrast material. With these imaging characteristics, particularly the absence of mucosal invasion and lack of cervical stromal and junctional zone infiltration, a cervicouterine lymphoma was suggested. Few nodes were seen at the iliac vessels and inguinal area, the largest being approximately 2 cm in diameter, consistent with adenopathy. On an abdominal and thoracic CT scan, few lymph nodes in inguinal and axillary regions were seen. Biopsy and aspiration of the bone marrow were negative for NHL. Tumor markers (AFP, CEA, CA-125, CA-15.3 and CA-19.9) were within normal limits. The measured levels of some hormones were as follows: FSH-40.77, LH-20.11, E2 < 18, TSH- 0.60, PRL-5.99. Additionally, sedimentation rate 62-105 mm/h, LDH: 463 (100-190), ALP: 164 (53-128), haptoglobin: 371 (34-200 mg/dL), β -2 microglobulin: 2.58 (< 3.0), albumin: 3.4 (3.6-4.9), γ -globulin: 1.8 (0.6-1.7), albumin/globulin rate 0.9% were detected in protein electrophoresis. HIV and HBsAg were negative. Tests excluded tumor progression to other organs and indicated a primary uterine lymphoma, stage IE according to Ann Arbor classification. She did not have any fever, night sweats or weight loss. Six courses of cytotoxic chemotherapy according to the CHOP protocol (day 1, cyclophosphamide 750 mg/m² i.v., adriamycin 50 mg/m² i.v., vincristine 1.4 mg/m² i.v. Days 1-5; prednisone 100 mg/m² po) were administered on a monthly basis. No major side effects developed during the treatment.

DISCUSSION

Malignant lymphomas make up 1.5-3.5% of all malignant neoplasm in females. A gre-

at majority (73%) of these tumors are NHL. NHL can involve extranodal locations, mostly the gastrointestinal tract and skin. Primary malignant lymphoma of the female genital tract is rare. Review of the literature would suggest that one in 175 female extranodal lymphomas is likely to originate in the vagina, uterus, or cervix^[4]. The ovaries are the most commonly affected (49%), followed by the uterus (29%), fallopian tubes (11%) and the vagina (7%); vulvar localisation is exceptional (4%)^[5-7]. The incidence of NHL especially extranodal lymphoma, has increased in recent decades. The etiology of the increase has been hypothesized to include infectious agents such as the human immunodeficiency virus (HIV) immunosuppressive therapies, environmental exposures to pesticides and pollutants and improved diagnostic techniques. Age of presentation of primary uterine lymphoma varies from 20 to 80 years (mean age 40 years). The most common symptom is abnormal vaginal bleeding. Other symptoms may include vaginal discharge, pain during sexual intercourse or pelvic pain. An abdominal or pelvic mass may be found on clinical examination. Fever, night sweats and weight loss are unusual. The neoplasm originates in the submucosal cervical stroma and the overlying squamous epithelium is unaffected, cervical smears are usually normal^[8,9]. The diagnosis of extranodal lymphoma may be inaccurate or delayed. This may be especially true for pelvic lymphoma, because it often presents with findings suggestive of more common gynecologic cancers. Although primary pelvic lymphoma is rare, the disease may be encountered more frequently as the incidence of extranodal non-Hodgkin's disease increases. Therefore, it is important for gynecologists to be aware of this disease, and to include pelvic lymphoma in the differential diagnosis of gynecologic cancer. Because of its rarity, an NHL is often not considered in the differential diagnose of a female genital tract tumor and therefore frequently misdiagnosed as a benign process or confused with other types

of tumors or other inflammatory reactive processes. The differential diagnosis for female genital tract NHL is basically the same for all gynecologic sites. It includes all types of inflammatory lesions and all solid benign and malignant tumours. DLBCL is the most common NHL in general, as well as the most common NHL within the female genital tract^[10]. The five-years survival rate is reported to range from 0 to 100%, but the majority of series report survival is in the range of 67 to 100%^[11]. In general, the prognosis for extranodal lymphoma is worse than for nodal lymphoma. The choice of the treatment depends upon the stage of malignancy. The extent of disease, the size of primary tumor, and the type of lymphoma are significant prognostic features, but because of its rarity, the standard treatment has not been established. In some cases local therapy alone would be sufficient to treat stage IE lymphomas. However, with bulky disease, neoadjuvant chemotherapy followed by radiotherapy has been generally used. The treatment of NHL usually involves various combinations of chemotherapy with or without radiation^[12]. According to Perren, there is no evidence that radical surgery in gynecological lymphoma is in any way advantageous^[13]. However, the question of hysterectomy remains unanswered. As a consequence of the low incidence, a standard treatment has not been clearly defined. Kuo et al administered neoadjuvant chemotherapy followed by extended hysterectomy, left salpingo-oophorectomy, bilateral pelvic lymph node dissection, and postoperative chemotherapy^[14]. A significant reduction in tumor size was achieved by neoadjuvant chemotherapy, with complete pathological response. The authors emphasized that using chemotherapy instead of irradiation can preserve ovarian function, as well as prevent and control the micrometastases. The importance of chemotherapy has also been emphasized by Awwad et al who instituted radiation-only therapy, and the patient succumbed to distant metastases despite adequate local control^[15]. In conclu-

sion, the case in this study serves to create awareness of the rare event in which NHL may involve the female genital tract. Histology is essential to reach a correct diagnosis of this rare and curable malignancy. Moreover, pelvic lymphoma may present with findings suggestive of more common gynecologic cancers. Therefore, it is important for gynecologists to be aware of this disease, and to include pelvic lymphoma in the differential diagnosis of gynecologic cancer.

REFERENCES

1. Ferry JA, Young RH. Malignant lymphoma of the genitourinary tract. *Curr Diag Pathol* 1997;4:145-69.
2. Glass AG, Karnell LH, Menck HR. The national cancer database report on non-Hodgkin's lymphoma. *Cancer* 1997;80:2311-20.
3. Taussig FJ. Sarcoma of the vulva. *Am J Obstet Gynecol* 1937;33:1017-37.
4. Grace A, O'Connell N, Byrne P, Prendiville W, O'Donnell R, Royston D. Malignant lymphoma of the cervix: an unusual presentation and a rare disease. *Eur J Gynecol Oncol* 1999;20:26-8.
5. Liang R, Chiu E, Loke SL. Non-Hodgkin lymphoma involving the female genital tract. *Haematol Oncol* 1990;8:295-9.
6. Chorlton I, Karnei RF Jr, King FM, Norris HJ. Primary malignant reticuloendothelial disease involving the vagina, cervix and corpus uteri. *Obstet Gynecol* 1974;44:735-48.
7. Lahtrop C. Malignant pelvic lymphomas. *Obstet Gynecol* 1967;30:137-45.
8. King J, Elkhalfi M, Michael C. Malignant lymphoma identified on cervical cytologic smear with immunophenotypic analysis. *Acta Cytologica* 1996;40:1228-30.
9. Harris NL, Scully RE. Malignant lymphomas and granulocytic sarcoma of the uterus and vagina. A clinicopathologic analysis of 27 cases. *Cancer* 1984; 53:2530-45.
10. Armitage JO, Weisenburger DD. New approach to classifying non-Hodgkin lymphomas: clinical features of the major histologic subtypes. Non-Hodgkin lymphoma classification project. *J Clin Oncol* 1998; 16:2780-95.
11. Freeman C, Berg JW, Cutler SJ. Occurrence and prognosis of extranodal lymphomas. *Cancer* 1972; 29:252-60.
12. Stroh EL, Besa PC, Cox JD, Fuller LM, Cabanillas FF. Treatment of patients with lymphomas of the uterus or cervix with combination chemotherapy and radiation therapy. *Cancer* 1995;75:2392-9.

13. Perren T, Farrant M, McCarthy K, Harper P, Wilshaw E. Lymphomas of the cervix and upper vagina: a report of five cases and a review of the literature. *Gynecol Oncol* 1992;44:87-95.
14. Kuo HC, Chou CY, Chang CH, Liu MT, Tzeng CC, Huang KE. Primary malignant lymphoma of the uterine cervix shows favourable response to neoadjuvant chemotherapy. *Gynecol Oncol* 1994;52:408-10.
15. Awwad JT, Khalil AM, Shamseddine AI, Mufarrij AA. Primary malignant lymphoma of the uterine cervix is radiotherapy the best therapeutic choice for stage IE ? *Gynecol Oncol* 1994;52:91-3.

Address for Correspondence:

Cem DANE, MD

Haseki Education and Research Hospital
Gynecology and Obstetrics
İstanbul, TURKEY