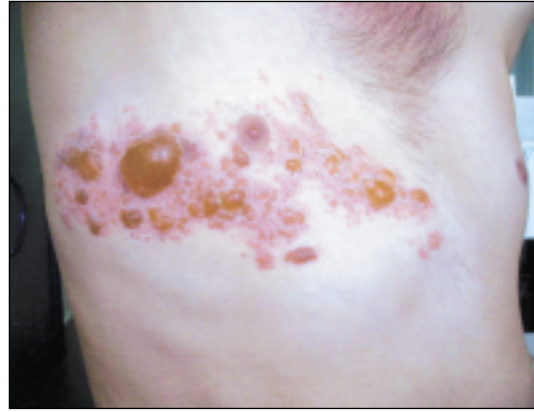
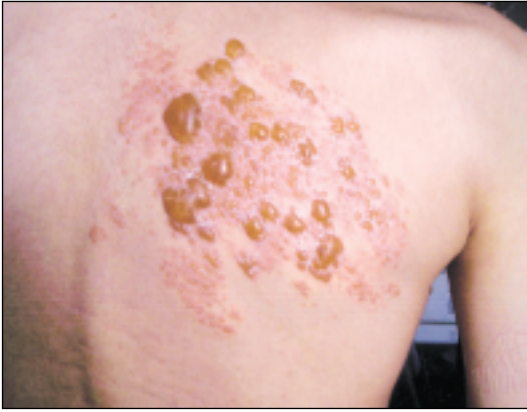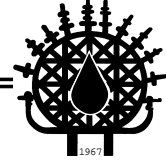


# Images in Haematology

Edited by: Hamdi Akan M.D.



A 20-years-old male patient was admitted to the hospital with anemia and thrombocytopenia. He was diagnosed as B-cell acute lymphoblastic leukemia and received PVD (prednisolone, vincristine, daunorubisin) induction chemotherapy. He entered complete remission followed by intrathecal methotrexate and consolidation chemotherapy. Vesicular, painful lesions appeared on the right side and back of the chest on day 40 of the consolidation therapy. Herpes Zoster was diagnosed and he received PO acyclovir 800 mg/day and topical acyclovir. Lesions regressed in a few days and he was found to be in remission after bone marrow aspiration biopsy.

**Turgay FEN**

Department of Hematology, Ankara Oncology  
Research and Education Hospital  
Ankara, TURKEY