
Detection of Epstein Barr Virus in Hodgkin's Disease in Trakya Region of Turkey; by in Situ Hybridization

Aslı ÖZDİL*, Latife DOĞANAY*, Muzaffer DEMİR**, Fulya ÖZ PUYAN*, Selçuk BİLGİ*

* Department of Pathology, Medical Faculty, University of Trakya,

** Department of Haematology, Medical Faculty, University of Trakya, Edirne, TURKEY

ABSTRACT

The relation of Epstein-Barr virus (EBV) and Hodgkin's disease (HD) has been suggested by serologic, epidemiological and molecular biologic studies. According to these studies the incidence of EBV in HD is high. In the present study, the EBV association with HD in Trakya Region of Turkey was investigated.

We investigated the presence of EBV in 44 cases of HD. Fluorescein-labelled antisense EBV (EBER-RNA) was performed by in situ hybridization.

There were 28 males and 16 females, with a mean age of 40 years (range 4-80 years). Histological subtypes included nodular sclerosis Hodgkin's disease (NSHD) in 18 (40.9%), mixed cellularity (MCHD) in 16 (36.4%), lymphocyte predominance (LPHD) in 7 (15.9%), and lymphocyte depletion (LDHD) in 3 (6.8%). EBV was expressed in 30 cases (68.2%). High EBV association was found with mixed cellularity 75% and nodular sclerosis 72.2%. In lymphocyte predominance and in lymphocyte depletion cases the EBV positivity was 57.1% and 33.3%, respectively. All of 7 cases, younger than 15 years old, were positive for EBV.

HD in Trakya Region showed a high association with EBV as in developing countries. Our findings suggest that EBV plays an important role in the pathogenesis of HD in Turkey.

Key Words: Epstein-Barr virus, Hodgkin's disease, In situ hybridization.

Turk J Haematol 2002;19(4): 461-464

Received: 19.02.2002

Accepted: 01.07.2002

INTRODUCTION

The relationship between Epstein-Barr virus (EBV) and Hodgkin's disease (HD) is of current inte-

rest. EBV has been implicated in the pathogenesis of HD. In Western populations the incidence of EBV is approximately 50% by using in situ hybridization met-

This research was supported by Research foundation of Trakya University, Edirne TURKEY

hod. Whereas the reported incidences are much higher in developing countries. Epidemiological studies, elevated serum antibodies to EBV, and clonal integration of the EBV genome in Reed-Sternberg (RS) cells suggest a significant role of EBV infection in the development of HD^[1,2].

Socioeconomical level of Trakya Region is higher than Anatolia and our hospital's interland is about 600.000 people. As the migration to other regions is very low in Trakya Region, our opinion is that the study cases reflect the regional incidence.

In this study, the association of EBV with HD was estimated according to age, sex and histological subtype in Trakya Region (Northwest of Turkey).

MATERIALS and METHODS

During the period 1984-1999, 44 HD cases were diagnosed in our laboratory. All the specimens were formalin-fixed and paraffin-embedded. Cases were classified according to the Rye Classification^[3].

Immunohistochemically CD15, CD20, CD30, epithelial membrane antigen (EMA) and CD45RO antibodies (DAKO, Carpenteria, CA) were applied.

For each case in situ hybridization was performed on 5 μ paraffin sections using fluorescein-labelled probes for EBER (Novocastra, NCL-EBV-K) according to the manufacturer's instruction. Control slides were obtained from the detection system kit.

RESULTS

The age of the patients ranged from 4 to 80 years. Twenty-eight of 44 patients (63.6%) were male, 16 of them (36.4%) were female. The mean age for males was 41.39 ± 20.9 , for females was 34.75 ± 18.09 . There were 18 patients with nodular sclerosis (40.9%), 16 patients with mixed cellularity (36.4%), 8 patients with lymphocytic predominance (15.9%), and 3 patients with lymphocytic depletion (6.8%). Mostly the presenting site was cervical lymph nodes (84.1%), and was followed in decreased numbers axilla, abdomen, mediasten and inguinal, respectively.

Thirty of 44 patients (68.2%) showed localization of EBV in RS cells and their variants. Additionally small reactive lymphocytes were stained in 25 of 44 (56.8%) cases (Figure 1). We determined that in 20 of these cases in which the small reactive lymphocytes

were EBV positive, the RS cells were also positive by in situ hybridization. The analysis of the EBV detection rate in different subtypes was mixed cellularity (MC), 75%; nodular sclerosis (NS), 72.2%; lymphocyte predominance (LP), 57.1%; and Lymphocyte depletion (LD), 33.3% (Table 1).

The age range for EBV-positive patients was 4-80 years. EBV was present in all patients younger than 15 years (7 of 44 patients).

DISCUSSION

The incidence of HD according to age has some differences between the industrialized and the developing countries. Bimodal peaks in young and older adults are found in Western countries. But, the high incidence of MCHD, in children was reported in developing countries^[4-8].

NSHD and MCHD were detected in 40.9%, 36.4% of the cases respectively. This distribution is similar to those of some Western countries such as Finland, Sweden and Aegean Region of Turkey^[7,9,10]. But it differs from those of Korea, China, Japan and Eastern Region of Turkey, and Central Anatolia whereas the most frequent subtype is MCHD^[4,5,11].

The subtypes showed no preferences to a particular age group or sex, but although it was not statistically significant ($p > 0.05$) slightly male predominance was observed.

The association of HD and EBV has been demonstrated by epidemiological, serologic and molecular biologic studies. It has been reported that the EBV

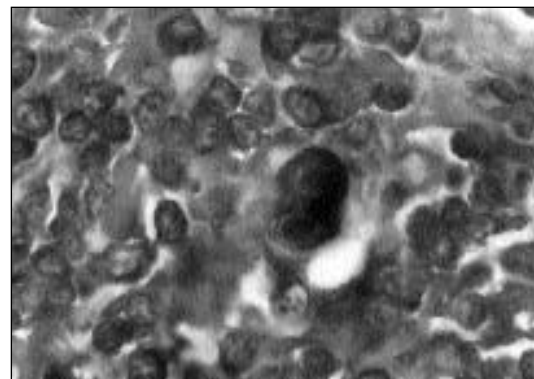


Figure 1. In situ hybridization for EBV showing strong positivity in the RS cells and small reactive lymphocytes. X 1000.

Table 1. Correlation of Epstein-Barr virus presence in histological subtypes of Hodgkin's disease

EBV	Positive cases	Negative cases	Total
MCHD	12 (75%)	4 (25%)	16
NSHD	13 (72.2%)	5 (27.8%)	18
LPHD	4 (57.1%)	3 (42.9%)	7
LDHD	1 (33.3%)	2 (66.7%)	3
Total	30 (68.2%)	14 (31.8%)	44

positivity in Western countries is 40-50%, whereas in Korea 69%, and in Taiwan 62.9%^[2,4,12]. In the present study we found 68.2% EBV positivity and it was reported that in Northeast Anatolia, the incidence was 75%^[13]. As well as previously reported studies from Turkey and from other countries, in our study the EBV association was high in MC subtype (75%)^[5-7,14-16].

Although there are few data on the association of EBV with HD in Turkish population these reported incidences are slightly higher than Western countries and similar to developing countries such as Korea, Philippines, Taiwan^[4,6,12]. There was no significant relation between HD histological subtypes and EBV positivity in our cases as in the previous reports in literature.

The presence of EBV positivity in small reactive lymphocytes in HD has been reported in many studies^[4,6,12]. In the present study EBV positive lymphocytes were seen in 25 of 44 cases (56.8%). EBV positive lymphocytes are found in EBV negative HD, hyperplastic lymph nodes and angioimmunoblastic lymphadenopathy, therefore many investigators thought that this positivity was not pathologically significant^[4,17].

In this study, there was no statistically significant relationship among histological subtypes, age, sex and the EBV positivity by in situ hybridization. The EBV incidence in HD is higher than the results of Western countries and as high as developing countries in the Northwest Turkey, Trakya Region.

REFERENCES

1. Flavel KJ, Murray PG. Hodgkin's disease and the Epstein-Barr virus. *J Clin Pathol* 2000;53:262-9.
2. MacLennan KA. Morphology and Classification of Hodgkin's disease. In: Whittaker JA, Holmes JA (eds). *Leukaemia and related disorders*. 3rd ed. UK: Blackwell Science Ltd. Editorial Offices, 1998:chapter 15:293-301.
3. Lukes RJ, Craver RF, Hall TC, Rappaport H, Ruben P. Report of nomenclature committee. *Cancer Res* 1966;16:1311.
4. Huh J, Park C, Juhng S, Kim CE, Poppema S, Kim C. A pathologic study of Hodgkin's disease in Korea and Its Association with the Epstein-Barr virus infection. *Cancer* 1996;77:949-55.
5. Tomita Y, Ohsawa M, Kanno H, Hashimoto M, Ohnishi A, Nakanishi H, Aozasa K. Epstein-Barr virus in Hodgkin's disease patients in Japan. *Cancer* 1996;77:186-92.
6. Paulino AFG, Cabrera EP, Weiss LM, Medeiros LJ. Hodgkin's disease in the Philippines. *Modern Pathology* 1996;9:115-9.
7. Enblad G, Sandvej K, Sundström C, Pallesen G, Glimehus B. Epstein-Barr virus distribution in Hodgkin's disease in an unselected Swedish population. *Acta Oncologica* 1999;38:425-9.
8. Çavdar AO, Gözdağoğlu S, Yavuz G, et al. Characteristic of early type-1 pattern (0-6 years) Hodgkin's disease in Turkish Children. *Turk J Haematol* 2002;19:55-62.
9. Ayhan S, Hekimgil M, İşisağ A, Soydan S. Hodgkin hastalığında bölgesel özellikler. *Turk J Cancer* 1997;5:19-21.
10. Fransilla KO, Heiskala MK, Heiskala HJ. Epidemiology and histopathology of Hodgkin's disease in Finland. *Cancer* 1977;39:1280-8.
11. Coşkun HŞ, Eser B, Çetin M, et al. Hodgkin's disease: Results of a single center in Central Anatolia. *Turk J Haematol* 2001;18:117-21.
12. Liu SM, Chow KC, Chiu CF, Tzeng CH. Expression of Epstein-Barr virus in patients with Hodgkin's disease in Taiwan. *Cancer* 1998;83:367-71.
13. Kaya H, Erman Z, Gündoğdu C, Tekin SB, Gündoğdu M. Epstein Barr virus in Hodgkin's disease patients in Northeast Anatolia. *Turk J Haematol* 2000; 17:61-5.
14. Beyan C. The detection of Epstein-Barr virus genome using polymerase chain reaction in Hodgkin's disease. *GATA Bülteni* 1996;38:53-7.
15. Pamir A, Ensari A, Aksoylar S, Erekuş S, Gözdağoğlu S. Epstein-Barr virus latent membrane protein expression in Turkish Hodgkin's disease patients. *Türk Hematoloji-Onkoloji Dergisi* 2000;10:20-5.

16. Ataoğlu Ö, Fen T, Süer Ö, Dağlı M, Akı Z, Yamaç K. Epstein-Barr virus latent membrane protein 1 (LMP1) in Hodgkin's lymphoma patients in Turkey. *Turk J Haematol* 2001;18:123-6.
17. Herbst H, Steinbrecher E, Neidobitek G, Young LS, Brooks L, Muller-Lantsch N, et al. Distribution and phenotype of Epstein-Barr virus-harboring cells in Hodgkin's disease. *Blood* 1992;80:484-91.

Address for Correspondence:

Aslı ÖZDİL, MD

Department of Pathology
Medical Faculty University of Trakya
22030, Edirne, TURKEY

e-mail: *asliozdil@yahoo.com*