

Creutzfeldt-Jakob Disease as a Reason for Neurological Deterioration in a Patient with Acute Lymphoblastic Leukemia after Allogeneic Hematopoietic Stem Cell Transplantation

Akut Lenfoblastik Lösemi Tanısı ile Allojeneik Kök Hücre Nakli Olan Hastada Nörolojik Klinik Bozulma Sebebi Olarak Creutzfeldt-Jakob Hastalığı

✉ Magdalena Karasek¹, ✉ Melissa Szmukala², ✉ Joanna Bladowska³, ✉ Jakub Ubysz⁴, ✉ Halina Bielecka⁴, ✉ Marta Sobas¹

¹Wroclaw Medical University, Department of Hematology, Blood Neoplasms, and Bone Marrow Transplantation, Wroclaw, Poland

²Wroclaw Medical University, Department of Hematology, Blood Neoplasms, and Bone Marrow Transplantation, Hematology Student Research Club, Wroclaw, Poland

³Wroclaw Medical University, Department of General and Interventional Radiology and Neuroradiology, Wroclaw, Poland

⁴Wroclaw Medical University, Department of Neurology, Wroclaw, Poland

To the Editor,

Neurological disorders are considered rare but serious complications after allogeneic hematopoietic stem cell transplantation (allo-HSCT). The presented case report involves a diagnostic challenge for physicians and a great threat for patients.

A 64-year-old patient was admitted to the hospital due to progressive alteration of consciousness for 3 weeks. Sixty days prior, the patient had undergone allo-HSCT due to high-risk acute lymphoblastic leukemia (ALL) with initial infiltration of the cerebrospinal fluid (CSF). At day 36 following allo-HSCT, complete remission with 100% chimerism was confirmed. At day 45, the patient presented with short-term memory loss. Reactivation of cytomegalovirus (CMV) was diagnosed and the patient started therapy with valganciclovir. Despite the decrease of the viral load of CMV, the neurological state of the patient continued to deteriorate. Clinical examination showed psychomotor retardation, moderate dementia, and exaggerated deep tendon reflexes without paresis of the limbs and without meningeal symptoms.

A brain computed tomography scan ruled out ischemic stroke and intracerebral hemorrhage. Bone marrow analysis excluded relapse of ALL. CSF examination showed normal levels of cells, glucose, and protein. CSF and serum analysis also ruled out viral (except for CMV), bacterial, fungal, and parasite infections. Hyponatremia, probably secondary to dehydration, was slowly corrected. All potentially neurotoxic medications were changed or stopped. However, the patient's clinical condition continued to deteriorate rapidly. Two weeks after admission, the patient was comatose with preserved pain response, and pyramidal and extrapyramidal signs were present. Brain magnetic resonance imaging (MRI) revealed hyperintensity in

the left parietal cortex (Figures 1A and 1C), which was initially misinterpreted as encephalitis. With the suspicion of limbic encephalitis, antibody tests of the blood and CSF had negative results. Treatment with plasmapheresis and corticosteroids and subsequently with immunoglobulins, mycophenolate mofetil, and anti-CD20 was administered with no improvement [1]. The patient became deeply comatose with flaccid tetraplegia and continuous myoclonic seizures. In the literature, reports of CNS involvement in chronic graft-versus-host disease are available, but this patient did not meet the relevant criteria [2]. Follow-up MRI presented very suggestive radiological signs of Creutzfeldt-Jacob disease (CJD) (Figures 1B and 1D). EEG results showed slow basal activity of both cerebral hemispheres with generalized synchronic periodic sharp-wave complexes, also suggesting CJD. The CSF analysis indicated the presence of 14-3-3 protein. Finally, the patient was diagnosed with probable sporadic CJD (Table 1) [3].

Following symptom onset, the patient's neurological state deteriorated quickly over the course of 6 weeks and death occurred within 4 months. The patient's family refused the neuropathological examination required for a definite diagnosis.

CJD is a fatal neurodegenerative disease caused by misfolded prion proteins (PrP^{Sc}). The morbidity is approximately one per million per year [5]. Definitive diagnosis of CJD is very difficult as it can occur spontaneously, may be genetically linked, or can be caused by inflammatory or contaminated transplant material, which is not commonly tested for prion diseases [4,5]. While allo-HSCT is a high-risk procedure associated with impaired immunity and serious complications, CJD should also be considered as a potential cause of rapidly progressing dementia.

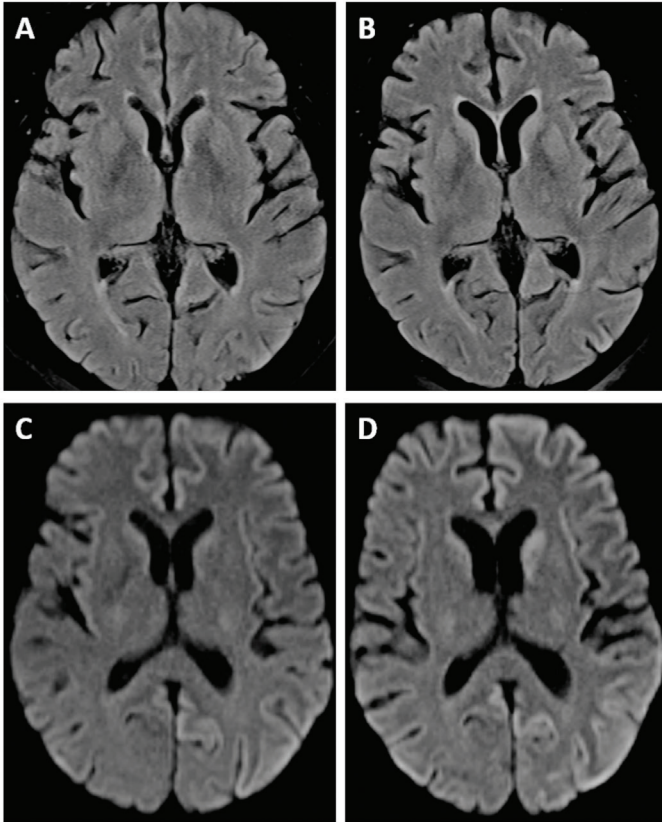


Figure 1. Brain magnetic resonance imaging (MRI) revealed hyperintensity in the left parietal cortex (A, C). Follow-up MRI presented very suggestive radiological signs of Creutzfeldt-Jakob disease (B, D).

Keywords: Creutzfeldt-Jakob disease, Neurological deterioration, Allogeneic hematopoietic stem cell transplantation, Differential diagnosis

Anahtar Sözcükler: Creutzfeldt-Jakob hastalığı, Nörolojik bozukluk, Allojenik kök hücre nakli, Ayırıcı tanı

Ethics

Informed Consent: Obtained.

Authorship Contributions

Surgical and Medical Practices: M.K., M.S., H.B.; Concept: M.K., M.S.; Design: M.K., M.S.; Data Collection or Processing: M.K., M.S., J.B., J.U.; Analysis or Interpretation: M.K., M.S., M.Sz., J.B., J.U.; Literature Search: M.K., M.S., M.Sz., J.B.; Writing: M.K., M.S., M.Sz., J.B., J.U.

Conflict of Interest: No conflict of interest was declared by the authors.

Financial Disclosure: The authors declared that this study received no financial support.

Table 1. Diagnostic criteria for sporadic Creutzfeldt-Jakob disease. Adapted from the National Creutzfeldt-Jakob Disease Research & Surveillance Unit [3].

Definite:
Progressive neurological syndrome and Neuropathologically or immunocytochemically or biochemically confirmed

Probable:

1.2.1 I + 2 of II and typical EEG*

or

1.2.2 I + 2 of II and typical MRI brain scan**

or

1.2.3 I + 2 of II and positive 14-3-3

or

1.2.4 Progressive neurological syndrome and positive RT-QuIC in CSF or other tissues

Possible

I + 2 of II + duration <2 years

*Generalized periodic complexes

**High signal in caudate/putamen on MRI brain scan or at least two cortical regions (temporal, parietal, occipital) either on DWI or FLAIR

- 1 Rapidly progressive cognitive impairment
- 2 A Myoclonus
B Visual or cerebellar problems
C Pyramidal or extrapyramidal features
D Akinetic mutism
- 3 Typical EEG
- 4 High signal in caudate/putamen on MRI brain scan

EEG: Electroencephalogram; MRI: magnetic resonance imaging; RT-QuIC: real-time quaking-induced conversion; CSF: cerebrospinal fluid; DWI: diffusion-weighted imaging; FLAIR: fluid-attenuated inversion recovery.

References

1. Hermetter C, Fazekas F, Hochmeister S. Systematic Review: Syndromes, early diagnosis, and treatment in autoimmune encephalitis. *Front Neurol* 2018;9:706.
2. Pruitt AA, Graus F, Rosenfeld MR. Neurological complications of transplantation: part I: Hematopoietic cell transplantation. *Neurohospitalist* 2013;3:24-38.
3. National Creutzfeldt-Jakob Disease Surveillance Diagnostic Criteria, 2010. Available online at <http://www.cjd.ed.ac.uk>.
4. Uttley L, Carroll C, Wong R, Hilton DA, Stevenson M. Creutzfeldt-Jakob disease: a systematic review of global incidence, prevalence, infectivity, and incubation. *Lancet Infect Dis* 2020;20:e2-e10.
5. De Sousa PA, Ritchie D, Green A, Chandran S, Knight R, Head MW. Renewed assessment of the risk of emergent advanced cell therapies to transmit neuroproteinopathies. *Acta Neuropathol* 2019;137:363-377.

©Copyright 2023 by Turkish Society of Hematology
Turkish Journal of Hematology, Published by Galenos Publishing House



Address for Correspondence/Yazışma Adresi: Magdalena Karasek, M.D., Wroclaw Medical University,
Department of Hematology, Blood Neoplasms, and Bone Marrow Transplantation, Wroclaw, Poland
E-mail : karasek.magdalena@gmail.com ORCID: orcid.org/0000-0002-1425-5421

Received/Geliş tarihi: November 18, 2022
Accepted/Kabul tarihi: March 10, 2023

DOI: 10.4274/tjh.galenos.2023.2022.0493