

Nilotinib-Associated Multiple Silent Arterial Stenoses in a Patient with Chronic Myeloid Leukemia

Kronik Miyeloid Lösemi Tanılı Hastada Nilotinib ile İlişkili Çoklu Sessiz Arteriyel Darlık

✉ Mert Tokatlı¹, ✉ Rashad Ismayilov¹, ✉ Olgu Erkin Çınar², ✉ İbrahim C. Haznedaroğlu²

¹Hacettepe University Faculty of Medicine, Department of Internal Medicine, Ankara, Türkiye

²Hacettepe University Faculty of Medicine, Department of Hematology, Ankara, Türkiye

To the Editor,

Nilotinib, a second-generation tyrosine kinase inhibitor (TKI), is employed in the treatment of chronic myeloid leukemia (CML) [1]. However, previous studies have indicated an association between nilotinib and vascular adverse events, including peripheral arterial occlusive disease, cerebrovascular disease, and coronary artery disease [2,3]. We report a case of significant bilateral carotid artery stenoses without any neurologic symptoms and, at the same time, left subclavian and celiac artery stenoses without any atherosclerotic or cardiovascular risk factors except age in a patient treated with nilotinib.

A 70-year-old non-smoking, non-diabetic Caucasian female with no history of vascular disease was diagnosed with CML in 2004. The patient was initially treated with imatinib at 400 mg/day, but due to loss of cytogenetic response, it was switched to dasatinib in the 6th year. The patient then experienced complications with recurrent pleural effusion despite appropriate management (dose reduction and diuretics along with steroid interventions) and therapy was changed to nilotinib at 2x400 mg/day in 2016. The nilotinib dose was reduced to 2x300 mg due to bicytopenia a few weeks after initiation. Although major molecular response was not achieved, a cytogenetic remission was obtained at that dose and the patient tolerated it well. Serum hemoglobin A1c (5.3%) and low-density lipoprotein cholesterol (92 mg/dL) were within the normal ranges during follow-up. In the 3rd year of nilotinib therapy, an inter-arm blood pressure difference (150/90 mmHg for the right arm and 110/70 mmHg for the left arm) was detected in a routine visit. A computed tomography angiogram (CTA) showed significant stenosis in the left subclavian artery, total occlusion in the celiac artery, and severe stenosis in the right internal carotid artery (ICA) (North American Symptomatic Carotid Endarterectomy Trial [NASCET] criterion: more than 50% stenosis), stenosis in the left vertebral artery orifice (NASCET criterion: more than 50% stenosis) with fibrofatty plaque in

February 2019. Endovascular stent placements were performed in the celiac and left subclavian arteries. Dual antiplatelet therapy (aspirin at 100 mg/day and clopidogrel at 75 mg/day) was initiated. Diffusion magnetic resonance imaging of the brain showed no ischemic pathology. The administration of nilotinib was continued to control the CML. One year later, a subsequent CTA showed progressive stenosis of the right ICA (NASCET criterion: 70%) and new stenosis of the left proximal ICA (NASCET criterion: less than 50%) within the fibrofatty plaque (Figure 1). Although she still had no neurologic symptoms, nilotinib was replaced with bosutinib to reduce the risk of vascular disease progression. Bosutinib was started at a dose of 200 mg and increased to 500 mg/day within weeks for better tolerability. After a few months, the patient left our follow-up and has not been admitted to our center again. Therefore, further information about the course of arterial stenosis after the drug change cannot be provided.

According to long-term evidence, arterial occlusive diseases are more strongly associated with nilotinib than other TKIs [2]. In most reported cases, the patients have baseline vascular risk factors such as hypertension, coronary artery disease, smoking, diabetes mellitus, or dyslipidemia. They also present with stroke, transient ischemic attack, or myocardial infarction at dramatically higher rates [4,5,6]. In our case, significant bilateral ICA stenoses developed asymptotically without major vascular risk factors other than age. To the best of our knowledge, only one previous report described bilateral severe ICA stenoses without neurological complications in a patient with 10 years of nilotinib usage [7]. Our case also indicates that multiple and radiologically severe but asymptomatic arterial stenoses may occur in nilotinib-using CML patients. A study of nilotinib-induced vasculopathy showed that nilotinib has pro-atherogenic and anti-angiogenic effects on endothelial cells by suppressing normal endothelial cell proliferation and migration [8].

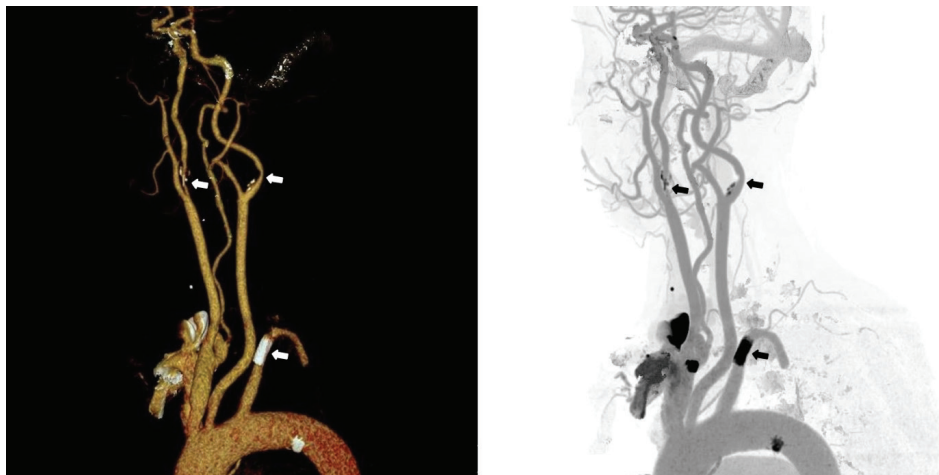


Figure 1. Computed tomography angiography results. Arrows show right and left internal carotid artery stenosis (>50%) and endovascular stent in the left subclavian artery.

These previous reports and our present case show that future studies are needed to investigate the causality between nilotinib and arterial stenotic disease beyond atherogenic pathways. We suggest that patients using nilotinib remain under active clinical surveillance to detect possible arterial stenoses, even if they are asymptomatic. Routine cardiovascular examination and awareness of these complications are of vital importance in detecting nilotinib-associated vascular stenoses.

Keywords: Nilotinib, Chronic myeloid leukemia, Arterial stenosis

Anahtar Sözcükler: Nilotinib, Kronik miyeloid lösemi, Arteriyel darlık

Ethics

Informed Consent: Written informed consent for publication of these details was obtained from the patient.

Authorship Contributions

Surgical and Medical Practices: M.T., R.I., O.E.Ç., İ.C.H.; Concept: M.T., R.I., O.E.Ç., İ.C.H.; Design: M.T., R.I., O.E.Ç., İ.C.H.; Data Collection or Processing: M.T., R.I.; Analysis or Interpretation: R.I., O.E.Ç.; Literature Search: M.T., R.I.; Writing: M.T., R.I.

Conflict of Interest: No conflict of interest was declared by the authors.

Financial Disclosure: The authors declared that this study received no financial support.

References

1. Weisberg E, Manley PW, Breitenstein W, Brügger J, Cowan-Jacob SW, Ray A, Huntly B, Fabbro D, Fendrich G, Hall-Meyers E, Kung AL, Mestan J, Daley GQ, Callahan L, Catley L, Cavazza C, Azam M, Neuberg D, Wright RD, Gilliland DG, Griffin JD. Characterization of AMN107, a selective inhibitor of native and mutant Bcr-Abl. *Cancer Cell* 2005;7:129-141.
2. Kantarjian HM, Hughes TP, Larson RA, Kim DW, Issaragrisil S, Coutre P, Etienne G, Boquimpani C, Pasquini R, Clark RE, Dubruille V, Flinn W, Kyrz-Krzemien S, Medras E, Zanichelli M, Bendit I, Cacciatore S, Titorenko K, Aimone P, Saglio G, Hochhaus A. Long-term outcomes with frontline nilotinib versus imatinib in newly diagnosed chronic myeloid leukemia in chronic phase: ENESTnd 10-year analysis. *Leukemia* 2021;35:440-453.
3. Minson AG, Cummins K, Fox L, Costello B, Yeung D, Cleary R, Forsyth C, Tatarczuch M, Burbury K, Motorna O, Shortt J, Fleming S, McQuillan A, Schwarer A, Harrup R, Holmes A, Ratnasingam S, Chan KL, Hsu WH, Ashraf A, Putt F, Grigg A. The natural history of vascular and other complications in patients treated with nilotinib for chronic myeloid leukemia. *Blood Adv* 2019;3:1084-1091.
4. Chen CJ, Sorace BJ, Shakeri A, Park MS, Southerland AM, Worrall BB, Kalani MYS. Tyrosine kinase inhibitor induced rapidly progressive vasculopathy after intracranial stent placement. *J Neurointerv Surg* 2018;10:e28.
5. Chen W, Du B, Liu K, Yu Z, Wang X, Yang P. Nilotinib related acute myocardial infarction with nonobstructive coronary arteries: a case report and literature review. *BMC Cardiovasc Disord* 2022;22:46.
6. Gómez-Galván J, Borrego S, Tovar N, Lull L. Nilotinib as a risk factor for ischaemic stroke: a series of three cases. *Neurologia* 2017;32:411.
7. Hirayama A, Sorimachi T, Yokota K, Shigematsu H, Srivatanakul K, Matsumae M. New-generation tyrosine kinase inhibitor-associated asymptomatic cerebrovascular stenosis: two illustrative cases. *Acta Neurochir (Wien)* 2022;164:1623-1626.
8. Hadzijušufovic E, Albrecht-Schgoer K, Huber K, Hoermann G, Grebien F, Eisenwort G, Schgoer W, Herndlhofer S, Kaun C, Theurl M, Sperr WR, Rix U, Sadvnik I, Jilma B, Scherthaner GH, Wojta J, Wolf D, Superti-Furga G, Kirchmair R, Valent P. Nilotinib-induced vasculopathy: identification of vascular endothelial cells as a primary target site. *Leukemia* 2017;31:2388-2397.



Address for Correspondence/Yazışma Adresi: Rashad Ismayilov, M.D., Hacettepe University Faculty of Medicine, Department of Internal Medicine, Ankara, Türkiye
Phone : +90 507 033 1995
E-mail : ismayilov_r@hotmail.com ORCID: orcid.org/0000-0002-7093-2722

Received/Geliş tarihi: July 20, 2023
Accepted/Kabul tarihi: December 28, 2023

DOI: 10.4274/tjh.galenos.2023.2023.0288