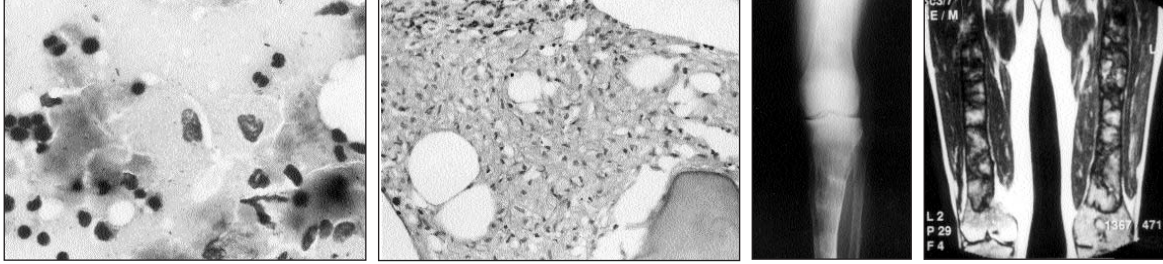


Images in Haematology

Edited by: Hamdi Akan M.D.



A 34-year-old man presented with a long time history of general malaise and generalized bone pain. Physical examination revealed no abnormality apart from mild splenomegaly. His left leg had been broken twelve years ago which was the only significant item in the medical history. Radiologic examination revealed skeletal complications. Plain films showed medullary expansion and cortical thinning in several bones, leading to Erlenmeyer-flask deformity in distal femora. Medullary destruction simulated honeycomb appearance in femoral shafts. Diffuse osteoporosis and callus formation due to healed fractures in right proximal humerus and left tibia were present in other sites. Diffuse medullary infiltration was confirmed in coronal magnetic resonance (MR) images of lower extremities. There was no soft tissue involvement on MR images. Abdominal computed tomography performed on admission revealed splenomegaly.

A whole blood count showed a hemoglobin concentration of 9.5 g/dL, white cell count 60.000/mm³, and platelets 42.000/mm³. No signs of bleeding diathesis have so far occurred. Examination of the blood film and bone marrow aspiration revealed mild red cell anisocytosis and numerous macrophages with greatly enlarged cytoplasm, some with the streaky, wrinkled paper appearance produced by the greatly elongated storage lysosomes of Gaucher's disease. Bone marrow aspirate indicated Gaucher's-like cells raising the suspicion of Gaucher's disease, however, definitive diagnosis was obtained by verifying deficient lysosomal glucocerebrosidase activity in peripheral blood leukocytes. Since there are no signs of neurologic involvement, the patient was diagnosed as adult form or type 1 Gaucher's disease.

Işın SOYUER*, **Özlem CANÖZ***, **Nuri ERDOĞAN****,
Bülent ESER***, **Mustafa ÇETİN*****

* Department of Pathology,

** Department of Radiodiagnostic,

*** Department of Hematology and Oncology,
Medical Faculty, University of Erciyes,
Kayseri, TURKEY