

A Rare Lymphoproliferative Disease: Castleman Disease

Nadir Bir Lenfoproliferatif Hastalık: Castleman Hastalığı

© Eren Gündüz¹, © Nihal Özdemir², © Şule Mine Bakanay³, © Sema Karakuş⁴

¹Eskişehir Osmangazi University Faculty of Medicine, Department of Hematology, Eskişehir, Turkey

²İstinye University Medical School, Department of Hematology, Istanbul, Turkey

³Ankara Yıldırım Beyazıt University Medical School, Department of Hematology, Ankara, Turkey

⁴Başkent University Faculty of Medicine, Department of Hematology, Ankara, Turkey

Abstract

Castleman disease is a rare lymphoproliferative disease also known as angiofollicular lymph node hyperplasia. It is classified as hyaline vascular and plasmacytic variants histologically but characteristics of both types can coexist. Most unicentric cases of the disease are hyaline vascular while most multicentric cases are of the plasmacytic type. Although the pathogenesis is not completely understood, the role of interleukin (IL)-6 in unicentric disease and the roles of IL-6 and human herpes virus-8 in multicentric disease are well defined. Unicentric disease is typically localized and symptoms are minimal and treated locally. Multicentric disease is systemic and clinically characterized by generalized lymphadenopathy, splenomegaly, anemia, and systemic inflammatory symptoms. Systemic therapies are primarily given. Several malignant diseases including lymphomas, POEMS syndrome, follicular dendritic cell sarcomas, paraneoplastic pemphigus, Kaposi sarcoma, and amyloidosis can be associated with Castleman disease. In this paper, recent information about Castleman disease, which is a rare disease, is summarized.

Keywords: Castleman disease, Diagnosis, Treatment

Öz

Castleman hastalığı, anjiyofoliküler lenf nodu hiperplazisi olarak da bilinen nadir bir lenfoproliferatif hastalıktır. Histolojik olarak hiyalin vasküler ve plazmasitik varyant olarak sınıflandırılır ancak nadiren iki tipe ait özellikler bir arada bulunabilir. Unisentrik hastalığı olan olguların çoğu hiyalin vasküler, multisentrik hastalığı olan olguların çoğu ise plazma hücreli histolojik tipindedir. Patogenezi tam olarak anlaşılmamıştır fakat unisentrik hastalıkta interlökin (IL)-6'nın, multisentrik hastalıkta IL-6 ve human herpes virüs-8'in rolü iyi tanımlanmıştır. Unisentrik hastalık tipik olarak lokalizedir, semptomlar minimaldir ve tek başına lokal tedavi uygulanır. Multisentrik hastalık sistemik bir hastalıktır ve klinik olarak yaygın lenfadenopati, splenomegali, anemi ve sistemik inflamatuvar semptomlarla karakterizedir. Başlıca sistemik tedaviler uygulanır. Lenfomalar, POEMS sendromu, folliküler dendritik hücreli sarkomlar, paraneoplastik pemphigus, Kaposi sarkomu, amiloidoz Castleman hastalığı ile ilişkili olabilir. Bu yazıda nadir bir hastalık olan Castleman hastalığı ile ilgili güncel bilgiler özetlenmiştir.

Anahtar Sözcükler: Castleman hastalığı, Tanı, Tedavi

Introduction

Castleman disease (CD), also known as angiofollicular lymph node hyperplasia and giant lymph node hyperplasia, was first reported by Benjamin Castleman in 1954. It is a rare disease diagnosed in 6600-7700 individuals each year in the United States [1,2].

CD is classified as unicentric CD (UCD), involving a single lymph node or a single region of nodes, and multicentric CD (MCD), involving multiple lymphatic regions [3]. UCD is more common [1] and has been reported to occur in younger individuals than MCD [4,5,6,7,8]. MCD can occur in any region of the body and has poorer prognosis.

MCD is further divided into three subgroups: human herpes virus-8 (HHV-8)-associated MCD; polyneuropathy, organomegaly, endocrinopathy, monoclonal gammopathy, and skin changes (POEMS)-associated MCD; and idiopathic MCD (iMCD) (Figure 1) [9].

Diagnosis

Standard investigations for CD usually begin with lymph node biopsy followed by radiological investigation, preferably with positron emission tomography/computed tomography (PET/CT), complete blood count, serum chemistry, markers of inflammation, serum cytokine levels, viral serology for HHV-8 and human immunodeficiency virus (HIV),



protein electrophoresis, immunofixation, and quantitative immunoglobulins [10,11].

The diagnostic criteria for iMCD and TAFRO syndrome, explained below, are summarized in Table 1 [12]. Diagnosis of HHV-8-associated MCD requires HHV-8 detection and plasmablastic histopathologic findings on lymph node biopsy [13]. POEMS-associated MCD is diagnosed if only one of the two mandatory major criteria of polyneuropathy and monoclonal plasma proliferative disorder is present with lymph node biopsy diagnostic of CD [14].

Table 1. Diagnostic criteria for idiopathic multicentric Castleman disease.
<p>Major criteria</p> <ol style="list-style-type: none"> 1. Lymph nodes with histopathologic features consistent with iMCD spectrum 2. Enlarged lymph nodes (≥1 cm in short-axis diameter) in ≥2 lymph node regions
<p>Minor criteria</p> <p>Laboratory</p> <ol style="list-style-type: none"> 1. Elevated CRP or ESR 2. Anemia 3. Thrombocytopenia or thrombocytosis 4. Hypoalbuminemia 5. Renal dysfunction or proteinuria 6. Polyclonal hypergammaglobulinemia <p>Clinical</p> <ol style="list-style-type: none"> 1. B symptoms 2. Hepatomegaly or splenomegaly 3. Fluid accumulation 4. Eruptive cherry hemangiomas 5. Violaceous papules 6. Lymphocytic interstitial pneumonitis
<p>Supporting features</p> <ol style="list-style-type: none"> 1. Elevated IL-6, VEGF, IgA, IgE, LDH, and/or B2M 2. Reticulin fibrosis of bone marrow 3. Disorders associated with iMCD: paraneoplastic pemphigus, bronchiolitis obliterans organizing pneumonia, autoimmune cytopenia, polyneuropathy, inflammatory myofibroblastic tumor
<p>Exclusion criteria</p> <ol style="list-style-type: none"> 1. Infection: HHV-8, EBV, CMV, toxoplasmosis, HIV, active tuberculosis 2. Autoimmune/autoinflammatory: systemic lupus erythematosus, rheumatoid arthritis, adult-onset Still disease, juvenile idiopathic arthritis, autoimmune lymphoproliferative syndrome 3. Malignancy: lymphoma, multiple myeloma, POEMS syndrome, primary lymph node plasmacytoma, follicular dendritic cell sarcoma
<p>Diagnosis requires both major criteria and at least 2 of 11 minor criteria with 1 laboratory criterion</p>
<p>iMCD: Idiopathic multicentric Castleman disease; CRP: C-reactive protein; ESR: erythrocyte sedimentation rate; IL-6: interleukin-6; VEGF: vascular endothelial growth factor; IgA: immunoglobulin A; IgE: immunoglobulin E; LDH: lactate dehydrogenase; B2M: beta-2 microglobulin; HHV-8: human herpesvirus-8; EBV: Epstein-Barr virus; CMV: cytomegalovirus; HIV: human immunodeficiency virus; POEMS: polyneuropathy, organomegaly, endocrinopathy, monoclonal protein, and skin changes.</p>

Differential Diagnosis

Autoimmune diseases (immunoglobulin G4-related disease, rheumatoid arthritis, systemic lupus erythematosus, adult-onset Still disease), neoplastic disorders (lymphoma, desmoid tumors, retroperitoneal sarcoma, paragangliomas, sarcomas, hemangiopericytoma, bronchial adenoma, neurofibroma, chest wall tumors, schwannoma), and infectious disorders (HIV, Epstein-Barr virus [EBV], cytomegalovirus, tuberculosis, toxoplasmosis) must be considered in the differential diagnosis [3,14,15,16,17,18,19].

Pathogenesis

Excessive cytokine production underlies the pathogenesis of CD. UCD and POEMS-associated MCD are caused by somatic mutations in monoclonal stromal and plasma cells [20]. In HHV-8-associated MCD, HHV-8 leads to a viral cytokine storm driven by interleukin-6 (IL-6) [11,12,21,22]. The exact mechanism of iMCD is unknown, but elevated IL-6 associated with autoimmune mechanisms, ectopic cytokine secretion by tumor cells, and/or viral signaling by a non-HHV-8 virus have been proposed [23].

Pathology

The types of CD (hyaline vascular or hypervascular, plasmacytic, and mixed) are characterized by distinctive lymphoid architectural changes in all nodal compartments. The hyaline vascular variant is the most common type of UCD. MCD is predominantly of the plasmacytic variant with a few cases showing plasmablastic characteristics (Table 2) [24].

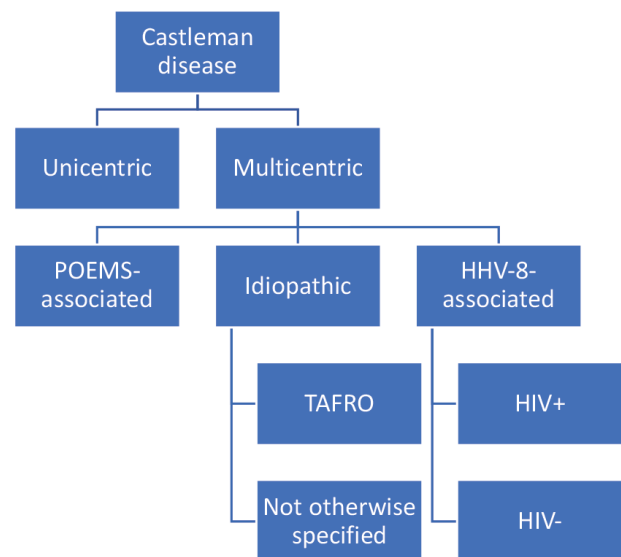


Figure 1. Classification of Castleman disease.

POEMS: Polyneuropathy, organomegaly, endocrinopathy, monoclonal protein, and skin changes; HHV-8: human herpesvirus-8; TAFRO: thrombocytopenia, anasarca, fever, reticulin fibrosis, and organomegaly; HIV: human immunodeficiency virus.

Clinical and Laboratory Features

UCD may be clinically silent and laboratory findings are typically unremarkable. On the other hand, MCD presents with diffuse lymphadenopathy, systemic inflammation, and organ dysfunction [25]. Comorbid malignancies, lymphoma in iMCD, and Kaposi sarcoma in HHV-8-associated MCD have been described [26,27,28]. Patients with MCD may demonstrate anemia, leukocytosis, thrombocytopenia, thrombocytosis, elevated C-reactive protein, elevated IL-6, elevated erythrocyte sedimentation rate, elevated IgG, hypoalbuminemia, renal dysfunction, and elevated liver enzymes [1,26]. Clinical and laboratory features of CD are summarized in Table 3.

Table 2. Histopathology of Castleman disease.

Histological subtypes	Frequency (%)	
	Unicentric	Multicentric
Hyaline vascular	75	<10
Mixed	<10	45
Plasmacytic	20	45

Specific Presentations of Castleman Disease

Paraneoplastic Pemphigus

The presence of mouth ulceration is highly suggestive of pemphigus and the severity of the disease correlates with lung involvement. It is more frequent in the context of UCD [11].

POEMS Syndrome

POEMS syndrome refers to the presence of peripheral neuropathy, organomegaly, endocrinopathy, monoclonal gammopathy, and skin changes. Other frequent clinical findings are papilledema, pleural effusions, ascites, sclerotic bone lesions, and thrombocytosis [21].

TAFRO Syndrome

TAFRO syndrome corresponds to a subtype of iMCD characterized by thrombocytopenia (T), anasarca (A), fever (F), reticulin fibrosis (R), and organomegaly (O) [11]. The outcome may be worse than in other cases of iMCD and no specific treatment has

Table 3. Clinical and laboratory features of Castleman disease.

	UCD	iMCD NOS	iMCD TAFRO	POEMS-associated MCD	HHV-8-associated MCD
Systemic symptoms (fever, sweating, weight loss, effusion, autoimmune, respiratory)	+/- None or compression	++ And rarely peripheral neuropathy	+++ And anasarca	++	+++ And Kaposi sarcoma
Lymphadenopathy	Mostly central, frequently bulky	Peripheral and central, usually small	Peripheral and central, usually small	Peripheral and central	Peripheral and central, usually small
Organomegaly	+/-	++	+++	+++	+++
Abnormal inflammation markers (ESR, CRP, cholinesterase, ferritin, albumin)	+/-	+++	+++ Procalcitonin is also elevated	++	+++
Anemia, thrombocytopenia, abnormal liver function tests	+/-	++ Sometimes thrombocytosis	+++	+/-	+++ HHV-8 DNA is detected in plasma
Hypergammaglobulinemia	+/-	+++	+/-	+, small M spike	+++
Renal dysfunction	-	+	+++ Intravascular coagulation and fibrinolysis	+	++
Autoimmune phenomena	Rare, but paraneoplastic pemphigus can be seen	++ Autoimmune hemolytic anemia, paraneoplastic pemphigus, immune thrombocytopenia, interstitial lung disease	+/-	+/-	DAT positivity 46%, monoclonal gammopathy 28%
Clinical course	Benign	Variable	Very aggressive	Aggressive	Aggressive
Lymphoma risk	+	+	+/-	+/-	++

UCD: Unicentric Castleman disease; iMCD NOS: idiopathic multicentric Castleman disease-not otherwise specified; iMCD TAFRO: idiopathic multicentric Castleman disease-thrombocytopenia, anasarca, fever, reticulin fibrosis, and organomegaly; POEMS MCD: multicentric Castleman disease-polyneuropathy, organomegaly, endocrinopathy, monoclonal gammopathy, and skin changes; HHV-8: human herpes virus-8; ESR: erythrocyte sedimentation rate; CRP: C-reactive protein; DAT: direct antiglobulin test.

been identified [22]. Diagnostic criteria for TAFRO syndrome are summarized in Table 4.

Hemophagocytic Lymphohistiocytosis

MCD and especially HHV-8-related MCD may be characterized by hemophagocytic lymphohistiocytosis at the initial presentation or upon relapse [25,26].

Autoimmune Cytopenia

Autoimmune hemolytic anemia is a relatively frequent complication of MCD. Immune thrombocytopenia has been reported in 5% to 20% of MCD cases [25,27,28].

Table 4. Diagnostic criteria for TAFRO syndrome.	
Criteria	
Histopathological criteria (all must be met) Typical lymph node pathology LANA-1 negative for HHV-8	
Major criteria (3 of 5 must be met) Thrombocytopenia (<100000/ μ L) Anasarca (pleural effusion and ascites in computed tomography) Fever (>38 °C) Reticulin fibrosis Organomegaly	
Minor criteria (at least 1) Hyper/normoplasia in megakaryocytes Elevated alkaline phosphatase without significant transaminase elevation	
TAFRO: Thrombocytopenia, anasarca, fever, reticulin fibrosis, and organomegaly; LANA-1: latency-associated nuclear antigen-1; HHV-8: human herpes virus-8.	

Peripheral Neuropathy

Demyelinating peripheral neuropathy is frequently observed with CD. There is no clear association between the severity of the peripheral neuropathy and the subtype of CD [29].

Renal Involvement

Renal involvement is frequently observed in MCD, mainly in the plasmacytic and mixed subtypes, being reported in up to 25% of MCD cases. Glomerular lesions, AA amyloidosis, and interstitial nephritis are the most common renal pathology findings [30].

Treatment

Surgical resection provides radical treatment for the majority of patients with UCD. Radiotherapy is an important alternative when surgical resection is contraindicated or technically difficult. Other treatment options are embolization, rituximab, or siltuximab/tocilizumab in the event of inflammation [23].

Treatment of MCD still remains complex because MCD is a rare clinical entity and there is a lack of randomized controlled trials. Multiple therapeutic approaches have been used, including conventional cytotoxic chemotherapy (single-agent or combined), antiviral treatment, glucocorticoids, thalidomide, interferon-alpha, and molecular targeted therapies. Determination of HHV-8 status is also important [10]. Therapeutic approaches for MCD are listed in Table 5.

The use of prednisone or other glucocorticosteroids will frequently ameliorate symptoms, partially improve lymphadenopathy, and correct laboratory abnormalities. However, the impact is generally temporary. Lasting remissions are rare and the disease

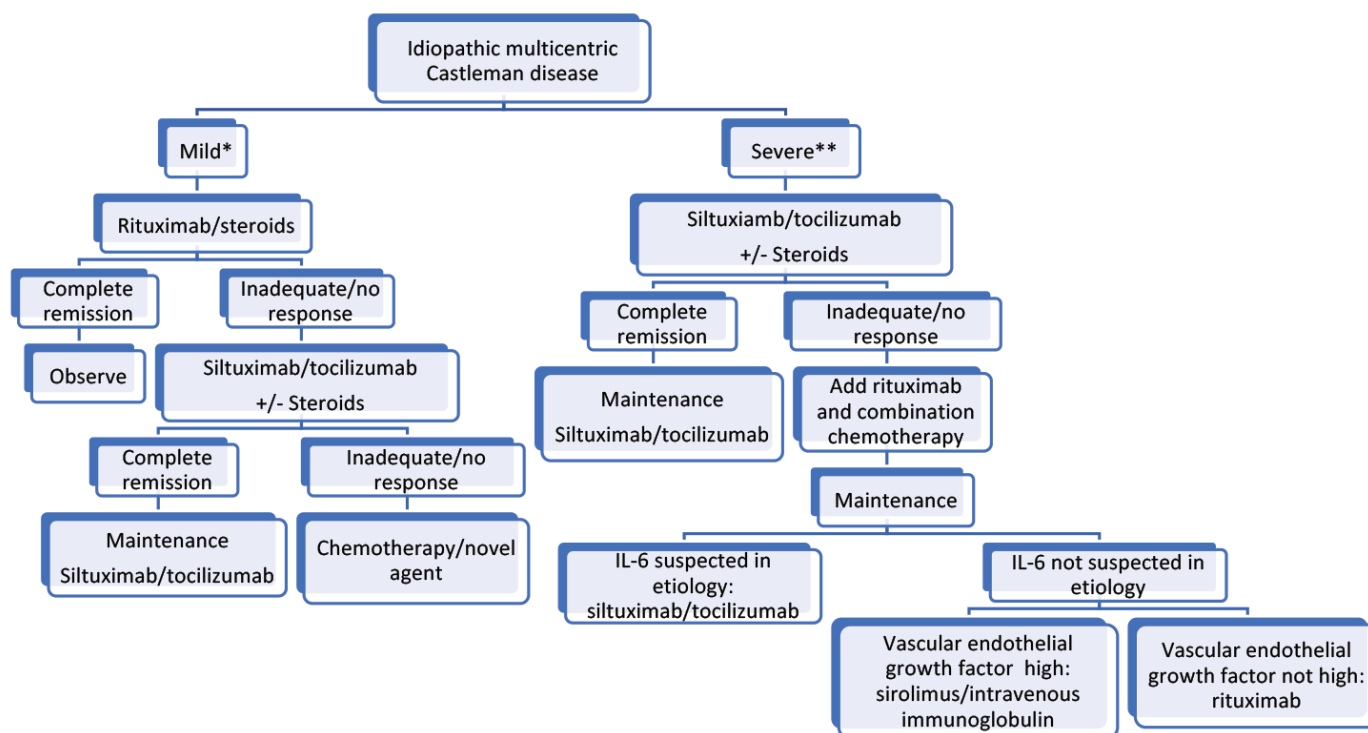
Table 5. Therapeutic approaches for multicentric Castleman disease.			
Disease	Idiopathic MCD	POEMS-associated MCD	HHV-8 associated MCD
First-line treatment	Siltuximab Tocilizumab Glucocorticoids	iMCD-like treatment if bone lesion absent Myeloma like treatment if bone lesion present	Combined antiretroviral treatment if HIV-positive Rituximab
Second-line treatment and beyond	Rituximab Cyclosporine Sirolimus IVIg Thalidomide Lenalidomide Bortezomib R-CVP, R-CHOP Autologous stem cell transplantation	As mentioned above	Etoposide Liposomal doxorubicin Interferon Antiviral treatment
MCD: Multicentric Castleman disease; IVIG: intravenous immunoglobulin; R: rituximab; CVP: cyclophosphamide, vincristine, prednisolone; CHOP: cyclophosphamide, doxorubicin, vincristine, prednisolone; iMCD: idiopathic multicentric Castleman disease; HHV-8: human herpesvirus-8; POEMS: polyneuropathy, organomegaly, endocrinopathy, monoclonal protein, and skin changes; HIV: human immunodeficiency virus.			

may require the long-term use of corticosteroids, increasing the risk of bacterial infections [31,32]. The use of corticosteroids alone may be better reserved as a temporary intervention in acute situations where more definitive therapy has not yet been decided or will be delayed [24].

Currently, chemotherapy is the first option for most symptomatic patients. However, data are insufficient to favor one treatment for all patients. Oral chlorambucil and cyclophosphamide have been effective and are generally well tolerated [23,31,33]. Vinblastine [10] and oral etoposide [13] may also have activity. Therapy with a single alkylating agent may be most appropriate

for fragile patients or cases in which a prompt response is not required.

Combination chemotherapy regimens such as cyclophosphamide, vincristine, and prednisone or cyclophosphamide, doxorubicin, vincristine, and prednisone have significant activity [10,14,31]. When combination chemotherapy is used, patients need to be closely monitored because of the increased risk of infection. Patients with HIV-associated CD may be at especially high risk for complications with standard combination chemotherapy [34]. A treatment algorithm is shown in Figure 2 [34,35].



Characteristic	*Mild (2 of 5)	**Severe (2 of 5)
1. ECOG performance status	0-1	≥2
2. Glomerular filtration rate	Normal	<30 mL/min
3. Fluid retention	Present	Anasarca, ascites, or effusion
4. Hemoglobin (g/dL)	≥10	<8
5. Pulmonary involvement	Absent	Present

Figure 2. Treatment algorithm for idiopathic multicentric Castleman disease. ECOG: Eastern Cooperative Oncology Group.

Conclusion

CD is a rare lymphoproliferative disease that can mimic many malignant and nonmalignant conditions. Lymph node biopsy is essential to establish a definitive diagnosis and greater awareness of the disease among clinicians would facilitate early diagnosis.

Authorship Contributions

Concept: E.G., N.Ö., Ş.M.B., S.K.; Design: E.G., N.Ö., Ş.M.B., S.K.; Literature Search: E.G.; Writing: E.G.

Conflict of Interest: No conflict of interest was declared by the authors.

Financial Disclosure: The authors declared that this study received no financial support.

References

- Munshi N, Mehra M, van de Velde H, Desai A, Potluri R, Vermeulen J. Use of a claims database to characterize and estimate the incidence rate for Castleman disease. *Leuk Lymphoma* 2015;56:1252-1260.
- Cervantes CE, Correa R. Castleman disease: a rare condition with endocrine manifestations. *Cureus* 2015;7:e380.
- Bonekamp D, Horton KM, Hruban RH, Fishman EK. Castleman disease: the great mimic. *Radiographics* 2011;31:1793-1807.
- Jiang JP, Shen XF, Du JF, Guan WX. A retrospective study of 34 patients with unicentric and multicentric Castleman's disease: experience from a single institution. *Oncol Lett* 2018;15:2407-2412.
- Yu JY, Oh IJ, Kim KS, Kim YI, Lim SC, Kim YC, Choi YD, Kwon YS. Castleman's disease presenting as a tracheal mass. *Ann Thorac Surg* 2014;97:1798-1800.
- Ye B, Gao SG, Li W, Yang LH, Zhao SH, Ma K, Zhu XL, Liu XY, Sun KL. A retrospective study of unicentric and multicentric Castleman's disease: a report of 52 patients. *Med Oncol* 2010;27:1171-1178.
- Luo JM, Li S, Huang H, Cao J, Xu K, Bi YL, Feng RE, Huang C, Qin YZ, Xu ZJ, Xiao Y. Clinical spectrum of intrathoracic Castleman disease: a retrospective analysis of 48 cases in a single Chinese hospital. *BMC Pulm Med* 2015;15:34.
- Kligerman SJ, Auerbach A, Franks TJ, Galvin JR. Castleman disease of the thorax: clinical, radiologic, and pathologic correlation: from the radiologic pathology archives. *Radiographics* 2016;36:1309-1332.
- Cronin DMP, Warnke RA. Castleman disease: an update on classification and the spectrum of associated lesions. *Adv Anat Pathol* 2009;16:236-246.
- Soulier J, Grollet L, Oksenhendler E, Cacoub P, Cazals-Hatem D, Babinet P, d'Agay MF, Clauvel JP, Raphael M, Degos L, Sigaux F. Kaposi's sarcoma-associated herpesvirus-like DNA sequences in multicentric Castleman's disease. *Blood* 1995;86:1276-1280.
- Slazat R, Munchi NC. Diagnosis of Castleman disease. *Hematol Oncol Clin N Am* 2018;32:53-64.
- Koa B, Borja AJ, Aly M, Padmanabhan S, Tran J, Zhang V, Rojulpotel C, Pierson SK, Tamakloe MA, Khor JS, Werner TJ, Fajgenbaum DC, Alavi A, Revheim ME. Emerging role of 18F-FDG PET/CT in Castleman disease: a review. *Insights Imaging* 2021;12:35-45.
- Scott D, Cabral L, Harrington WJ Jr. Treatment of HIV-associated multicentric Castleman's disease with oral etoposide. *Am J Hematol* 2001;66:148-150.
- Herrada J, Cabanillas F, Rice L, Manning J, Pugh W. The clinical behavior of localized and multicentric Castleman disease. *Ann Intern Med* 1998;128:657-662.
- Fajgenbaum DC, Uldrick TS, Bagg A, Frank D, Wu D, Srkalovic G, Simpson D, Liu AY, Menke D, Chandrakasan S, Lechowicz MJ, Wong RSM, Pierson S, Paessler M, Rossi JF, Ide M, Ruth J, Croglino M, Suarez A, Krymskaya V, Chadburn A, Colleoni G, Nasta S, Jayanthan R, Nabel CS, Casper C, Dispenzieri A, Fossa A, Kelleher D, Kurzrock R, Voorhees P, Dogan A, Yoshizaki K, van Rhee F, Oksenhendler E, Jaffe ES, Elenitoba-Johnson KSJ, Lim MS. International, evidence-based consensus diagnostic criteria for HHV-8-negative/idiopathic multicentric Castleman disease. *Blood* 2017;129:1646-1657.
- Madan R, Chen JH, Trotman-Dickenson B, Jacobson F, Hunsaker A. The spectrum of Castleman's disease: mimics, radiologic pathologic correlation and role of imaging in patient management. *Eur J Radiol* 2012;81:123-131.
- Delaney SW, Zhou S, Maceri D. Castleman's disease presenting as a parotid mass in the pediatric population: a report of 2 cases. *Case Rep Otolaryngol* 2015;2015:691701.
- Oksenhendler E, Boutboul D, Fajgenbaum D, Mirouse A, Fieschi C, Malphettes M, Vercellino L, Meignin V, Gerard L, Galicier L. The full spectrum of Castleman disease: 273 patients studied over 20 years. *Br J Haematol* 2018;180:206-216.
- Chen LYC, Mattman A, Seidman MA, Carruthers MN. IgG4-related disease: what a hematologist needs to know. *Haematologica* 2019;104:444-455.
- Kotb R, Vincent I, Dulioust A, Peretti D, Taburet AM, Delfraissy JF, Goujard C. Life-threatening interaction between antiretroviral therapy and vinblastine in HIV-associated multicentric Castleman's disease. *Eur J Haematol* 2006;76:269-271.
- Royer B, Merlusca L, Abraham J, Musset L, Haroche J, Choquet S, Leleu X, Sebban C, Decaux O, Galicier L, Roussel M, Recher C, Banos A, Guichard I, Brisseau JM, Godmer P, Hermine O, Deplanque G, Facon T, Asli B, Leblond V, Ferman J, Marolleau JP. Efficacy of lenalidomide in POEMS syndrome: a retrospective study of 20 patients. *Am J Hematol* 2013;88:207-212.
- Iwaki N, Fajgenbaum DC, Nabel CS, Gion Y, Kondo E, Kawano M, Masunari T, Yoshida I, Moro H, Nikkuni K, Takai K, Matsue K, Kurosawa M, Hagihara M, Saito A, Okamoto M, Yokota K, Hiraiwa S, Nakamura N, Nakao S, Yoshino T, Sato Y. Clinicopathologic analysis of TAFRO syndrome demonstrates a distinct subtype of HHV-8-negative multicentric Castleman disease. *Am J Hematol* 2016;91:220-226.
- Chronowski GM, Ha CS, Wilder RB, Cabanillas F, Manning J, Cox JD. Treatment of unicentric and multicentric Castleman disease and the role of radio-therapy. *Cancer* 2001;92:670-676.
- Saeed-Abdul-Rahman I, Al-Amri AM. Castleman disease. *Korean J Hematol* 2012;47:163-177.
- Stebbing J, Ngan S, Ibrahim H, Charles P, Nelson M, Kelleher P, Naresh KN, Boer M. The successful treatment of haemophagocytic syndrome in patients with human immunodeficiency virus-associated multicentric Castleman's disease. *Clin Exp Immunol* 2008;154:399-405.
- Dossier A, Meignin V, Fieschi C, Boutboul D, Oksenhendler E, Galicier L. Human herpesvirus 8-related Castleman disease in the absence of HIV infection. *Clin Infect Dis* 2013;56:833-842.
- Bower M, Newsom-Davis T, Naresh K, Merchant S, Lee B, Gazzard B, Stebbing J, Nelson M. Clinical features and outcome in HIV associated multicentric Castleman's disease. *J Clin Oncol* 2011;29:2481-2486.
- Dong Y, Wang M, Nong L, Wang L, Cen K, Liu W, Zhu S, Sun Y, Liang Z, Li Y, Ou J, Qiu Z, Ren H. Clinical and laboratory characterization of 114 cases of Castleman disease patients from a single centre: paraneoplastic pemphigus is an unfavourable prognostic factor. *Br J Haematol* 2015;169:834-842.
- Naddaf E, Dispenzieri A, Mandrekar J, Mauermann ML. Clinical spectrum of Castleman disease-associated neuropathy. *Neurology* 2016;87:2457-2462.
- London J, Boutboul D, Agbalika F, Coppo P, Veyradier A, Gerard L, Oksenhendler E, Azoulay E, Galicier L. Autoimmune thrombotic thrombocytopenic purpura associated with HHV8-related multicentric Castleman disease. *Br J Haematol* 2017;178:486-488.

31. Frizzera G, Peterson BA, Bayrd ED, Goldman A. A systemic lymphoproliferative disorder with morphologic features of Castleman's disease: clinical findings and clinicopathologic correlations in 15 patients. *J Clin Oncol* 1985;3:1202-1216.
32. Dispenzieri A, Gertz MA. Treatment of Castleman's disease. *Curr Treat Options Oncol* 2005;6:255-266.
33. Peterson BA, Frizzera G. Multicentric Castleman's disease. *Semin Oncol* 1993;20:636-647.
34. Dispenzieri A, Fajgenbaum DJ. Overview of Castleman disease. *Blood* 2020;135:1353-1364.
35. van Rhee F, Greenway A, Stone K. Treatment of idiopathic Castleman disease. *Hematol Oncol Clin North Am* 2018;32:89-106.