

cases of CLL with DM were reported, and one patient received methotrexate with cyclophosphamide. The skin rash in DM does not mean malignant skin involvement; therefore, DM treatment should be initiated separately, as in our case. However, DM with associated malignancy responds poorly compared to idiopathic cases [5]. Long-term outcomes of CLL with DM are unknown, and so are data regarding the use of chemoimmunotherapy in such patients, although rituximab has shown efficacy in DM [6]. It is prudent for the overworked clinician to not overlook neurological or musculoskeletal symptoms in CLL patients, and a keen search for hematological malignancy is justified in known cases of inflammatory myopathies.

Keywords: CLL, Cutaneous involvement, Rash

Anahtar Sözcükler: KLL, Deri tutulumu, Döküntü

Informed Consent: Informed consent has been obtained before writing this manuscript.

Authorship Contributions

Concept: S.K., A.G.; Design: S.K., A.G.; Data Collection or Processing: R.G., S.M., A.G.; Writing: S.K., A.G., R.G., S.M.

©Copyright 2020 by Turkish Society of Hematology
Turkish Journal of Hematology, Published by Galenos Publishing House



Address for Correspondence/Yazışma Adresi: Ajay Gogia, MD, AIIMS, Department of Medical Oncology,
New Delhi, India
Phone : 9013000642
E-mail : ajaygogia@gmail.com ORCID: orcid.org/0000-0001-6500-1061

Received/Geliş tarihi: June 15, 2020
Accepted/Kabul tarihi: August 19, 2020

DOI: 10.4274/tjh.galenos.2020.2020.0331

IRF4-Rearranged Large B-Cell Lymphoma on Waldeyer's Ring: A Case Report

Waldeyer Halkasında IRF4 Yeniden Düzenlenmesi Büyük B-hücreli Lenfoma Olgusu

© Deram Büyüktaş¹, © Serdar Örnek², © Fatma Tokat³, © Tülay Tecimer⁴, © Burhan Ferhanoğlu¹

¹Koç University Faculty of Medicine, Department of Hematology, İstanbul, Turkey

²American Hospital, Clinic of Hematology, İstanbul, Turkey

³Acıbadem University Faculty of Medicine, Department of Pathology, İstanbul, Turkey

⁴Acıbadem Health Group, Pathology Laboratory, İstanbul, Turkey

To the Editor,

Large B-cell lymphoma (LBCL) with *IRF4* rearrangement is a newly recognized and rare entity. LBCL is characterized by co-expression of *MUM1* and *BCL6*. It has been associated with young age and a favorable outcome. Most patients present with predominantly Waldeyer's ring or neck or head lymph node involvement [1,2,3]. Here, we present a case of LBCL with *IRF4* rearrangement in an older male.

Ethics Committee Approval: This study has followed ethical standards.

Financial Disclosure: No funding was received for this study.

References

1. Hamblin TJ. Non-hemic autoimmunity in CLL. *Leuk Res* 2009;33:366-367.
2. Stübgen JP. Inflammatory myopathies and lymphoma. *J Neurol Sci* 2016;369:377-389.
3. Kay NE. Abnormal T-cell subpopulation function in CLL: excessive suppressor (T gamma) and deficient helper (T mu) activity with respect to B-cell proliferation. *Blood* 1981;57:418-420.
4. Gunawardena H, Betteridge ZE, McHugh NJ. Myositis-specific autoantibodies: their clinical and pathogenic significance in disease expression. *Rheumatology (Oxford)* 2009;48:607-612.
5. Marie I, Guillevin L, Menard JF, Hatron PY, Cherin P, Amoura Z, Cacoub P, Bachelez H, Buzyn A, Le Roux G, Ziza JM, Brice P, Munck JN, Sarrot-Reynaud F, Piette JC, Larroche C. Hematological malignancy associated with polymyositis and dermatomyositis. *Autoimmun Rev* 2012;11:615-620.
6. Levine TD. Rituximab in the treatment of dermatomyositis: an open-label pilot study. *Arthritis Rheum* 2005;52:601-607.

A 67-year-old man was admitted to the hospital with sore throat, dysphagia, and a lump in the right cervical region. Physical examination showed that the right palatine tonsil was enlarged and there was 2 cm of cervical lymphadenopathy unilaterally. After one week of antibiotic therapy, the lymphadenopathy still persisted. The patient underwent an excisional lymph node biopsy, which was consistent with LBCL of germinal center type, with a mainly follicular and focally diffuse pattern. The immunohistochemistry panel was positive for CD20 (clone L26;

Scytek), CD10 (clone 56C6; Biocare), bcl-6 (clone LN22; Biocare Medical), and MUM1 (clone BC5; Biocare Medical), while bcl-2 (clone 124; Scytek) and myc (clone MYC; Biocare) were negative (Figure 1A). Different from follicular lymphoma and diffuse large B-cell lymphoma, the neoplasm was mainly composed of centroblast-like large cells with germinal center phenotype and strong co-expression of *MUM1*. Morphologic and immunohistochemical findings reminded us of the possibility of *IRF4*-rearranged LBCL. FISH analysis for *IRF4* rearrangement (*IRF4*, *DUSP22* dual-color break-apart probe) was performed and rearrangement was found to be positive (Figure 1B). Based on these findings, LBCL with *IRF4* rearrangement was diagnosed. PET-CT showed increased FDG uptake on the right tonsil with level IIA-III cervical stations (Figure 1C). Clinical staging studies led us to stage I disease and the International Prognostic Index score was calculated as 1. After four cycles of R-CHOP₂₁, PET-CT showed complete remission (Figure 1C). No further therapy was indicated, and 3 months after the chemotherapy, no evidence was observed of any recurrence.

Salaverria et al. [1] studied 720 lymphomas and screened a group of 427 cases for *IRF4*. They identified 20 lymphomas with

proven *IG/IRF4* fusion with a median age of 12 years. The *IRF4*-positive lymphomas mostly presented as limited disease in the head and neck region, especially in Waldeyer's ring, and were associated with better prognosis [1].

Ramis-Zaldivar et al. [4] studied 20 LBCL-*IRF4* pediatric and young adult cases with a median age of 14 years. Eight patients had nodal involvement of the head and neck region, and 8 had tonsillar involvement. Fifteen patients had complete remission after therapy without evidence of relapse for up to 99 months in follow-up; thus, a very favorable outcome was shown among LBCL-*IRF4* cases [4].

Older age is considered to be an adverse prognostic factor in patients with Waldeyer's ring non-Hodgkin lymphoma and as an independent risk factor for inferior survival among patients with diffuse large B-cell lymphoma [3,5]. FLYER study results showed that four cycles of CHOP chemotherapy had the same effect among young patients with aggressive B-cell lymphoma who had favorable risk profile and stage I-II disease [6]. Our patient had no other risk factors except his age, and he had *IRF4* gene arrangement; thus, we ended the chemotherapy after the fourth cycle with negative PET-CT results.

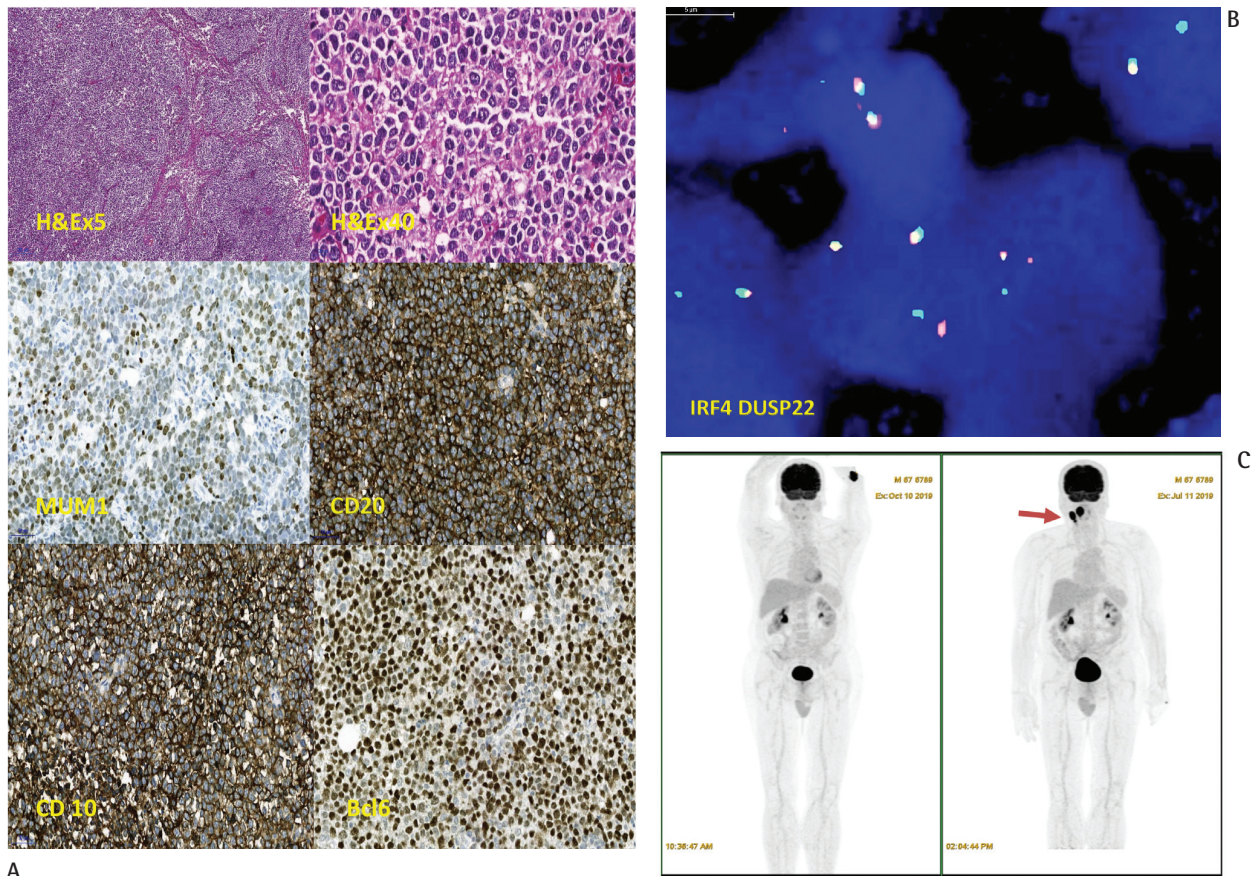


Figure 1. Large B-cell lymphoma with *IRF4* rearrangement. **A)** Follicular and diffuse pattern, H&E, original magnification 5 \times . Medium to large-sized neoplastic cells with vesicular chromatin and 2-3 nucleoli, H&E, original magnification 40 \times . Large cells with positive expression of *MUM1*, *CD20*, *CD10*, and *bcl6*, original magnification 20 \times . **B)** FISH analysis demonstrated a positive *IRF4* translocation. **C)** Comparative PET-CT images (before and after treatment).

In conclusion, *IRF4* gene analysis should be considered in patients of any age with Waldenstrom's ring LBCL with germinal center origin, follicular and/or diffuse pattern, and strong *MUM1* expression on pathological examination. The presence of *IRF4* rearrangement may affect the prognosis of the disease and the duration of chemotherapy.

Keywords: Large B- cell lymphoma, Waldenstrom's ring, IRF4, MUM1

Anahtar Sözcükler: Büyük B-hücreli lenfoma, Waldenstrom halkası, IRF4, MUM1

Authorship Contributions

Surgical and Medical Practices: D.B., S.Ö., B.F.; Concept: B.F.; Design: D.B., B.F.; Data Collection or Processing: D.B., S.Ö., T.T., F.T.; Analysis or Interpretation: D.B., B.F.; T.T., F.T.; Literature Search: D.B.; Writing: D.B., S.Ö., T.T., B.F.

Conflict of Interest: No conflict of interest was declared by the authors.

Financial Disclosure: This research did not receive any specific grant from any funding agency in the public, commercial, or not-for-profit sectors.

References

1. Salaverria I, Philipp C, Oschlies I, Kohler CW, Kreuz M, Szczepanowski M, Burkhardt B, Trautmann H, Gesk S, Andrusiewicz M, Berger H, Fey M, Harder L, Hasenclever D, Hummel M, Loeffler M, Mahn F, Martin-Guerrero I, Pellissery S, Pott C, Pfreundschuh M, Reiter A, Richter J, Rosolowski M, Schwaenen C, Stein H, Trümper L, Wessendorf S, Spang R, Küppers R, Klapper W, Siebert R; Molecular Mechanisms in Malignant Lymphomas Network Project of

the Deutsche Krebshilfe; German High-Grade Lymphoma Study Group; Berlin-Frankfurt-Münster-NHL trial group. Translocations activating IRF4 identify a subtype of germinal center-derived B-cell lymphoma affecting predominantly children and young adults. *Blood* 2011;118:139-147.

2. de Leval L, Bonnet C, Copie-Bergman C, Seidel L, Baia M, Brière J, Molina TJ, Fabiani B, Petrella T, Bosq J, Gisselbrecht C, Siebert R, Tilly H, Haioun C, Fillet G, Gaulard P. Diffuse large B-cell lymphoma of Waldenstrom's ring has distinct clinicopathologic features: a GELA study. *Ann Oncol* 2012;23:3143-3151.
3. Swerdlow SH, Campo E, Harris NL, Jaffe ES, Pileri SA, Stein H, Thiele J, Arber DA, Hasserjian RP, Lea Beau M, Orazi A, Siebert R. WHO Classification of Tumours of Haematopoietic and Lymphoid Tissues. Lyon, IARC Press, 2017.
4. Ramis-Zaldivar JE, Gonzalez-Farré B, Balagué O, Celis V, Nadeu F, Salmerón-Villalobos J, Andrés M, Martín-Guerrero I, Garrido-Pontnou M, Gaafar A, Suñol M, Bárcena C, García-Bragado F, Andión M, Azorín D, Astigarraga I, Sagaseta de Ilurdoz M, Sábado C, Gallego S, Verdú-Amorós J, Fernandez-Delgado R, Perez V, Tapia G, Mozos A, Torrent M, Solano-Páez P, Rivas-Delgado A, Dlouhy I, Clot G, Enjuanes A, López-Guillermo A, Galera P, Oberley MJ, Maguire A, Ramsower C, Rimsza LM, Quintanilla-Martinez L, Jaffe ES, Campo E, Salaverria I. Distinct molecular profile of IRF4-rearranged large B-cell lymphoma. *Blood* 2020 23;135:274-286.
5. Ezzat AA, Ibrahim EM, El Weshi AN, Khafaga YM, AlJurf M, Martin JM, Ajarim DS, Bazarbashi SN, Stuart RK, Zucca E. Localized non-Hodgkin's lymphoma of Waldenstrom's ring: clinical features, management, and prognosis of 130 adult patients. *Head Neck* 2001;23:547-558.
6. Poeschel V, Held G, Ziepert M, Witzens-Harig M, Holte H, Thurner L, Borchmann P, Viardot A, Soekler M, Keller U, Schmidt C, Truemper L, Mahlberg R, Marks R, Hoeffkes HG, Metzner B, Dierlamm J, Frickhofen N, Haenel M, Neubauer A, Kneba M, Merli F, Tucci A, de Nully Brown P, Federico M, Lengfelder E, di Rocco A, Trappe R, Rosenwald A, Berdel C, Maisenhoelder M, Shpilberg O, Amam J, Christofyllakis K, Hartmann F, Murawski N, Stilgenbauer S, Nickelsen M, Wulf G, Glass B, Schmitz N, Altmann B, Loeffler M, Pfreundschuh M; FLYER Trial Investigators; German Lymphoma Alliance. Four versus six cycles of CHOP chemotherapy in combination with six applications of rituximab in patients with aggressive B-cell lymphoma with favourable prognosis (FLYER): a randomised, phase 3, non-inferiority trial. *Lancet* 2020;394:2271-2281.

©Copyright 2020 by Turkish Society of Hematology
Turkish Journal of Hematology, Published by Galenos Publishing House



Address for Correspondence/Yazışma Adresi: Burhan Ferhanoğlu, MD, Koç University Faculty of Medicine, Department of Hematology, İstanbul, Turkey
E-mail : onurlu2007@gmail.com ORCID: orcid.org/0000-0002-4257-549X

Received/Geliş tarihi: February 25, 2020
Accepted/Kabul tarihi: April 28, 2020

DOI: 10.4274/tjh.galenos.2020.2020.0086

An Unconventional Presentation of Multiple Myeloma: Bazex Syndrome

Multipl Myelomun Olağan Dışı Bir Prezantasyonu: Bazex Sendromu

Özlem Kandemir Alibakan¹, Naciye Demirel², Nihan Nizam³, Rafet Eren²

¹University of Health Sciences Turkey, Prof. Dr. Cemil Taşçıoğlu Training and Research Hospital, Clinic of Internal Medicine, İstanbul, Turkey

²University of Health Sciences Turkey, Prof. Dr. Cemil Taşçıoğlu Training and Research Hospital, Clinic of Hematology, İstanbul, Turkey

³İstanbul University İstanbul Faculty of Medicine, Department of Internal Medicine, İstanbul, Turkey

To the Editor,

Multiple myeloma patients may exhibit signs and symptoms of skin involvement secondary to either malignant cell infiltration or disease-specific treatment. There are also anecdotal reports

of paraneoplastic skin diseases including Sweet syndrome, leukocytoclastic vasculitis, and neutrophilic dermatosis associated with multiple myeloma [1]. In this report, we share a patient with a remarkably rare skin presentation of multiple myeloma.