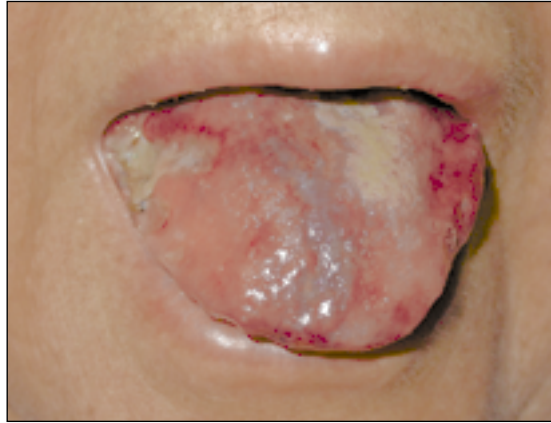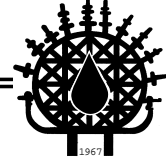


# Images in Haematology

Edited by: Hamdi Akan M.D.



A 60-years-old woman with IgG kappa multiple myeloma, who was refractory to VAD and thalidomide therapy, developed macroglossia. The images of dental indentations can be clearly seen on the edges of the tongue and there are multiple nodular lesions in the lips. The biopsy from the tongue revealed amyloidosis.

**Mehmet Ali ÖZCAN, Özden PİŞKİN, İnci ALACACIOĞLU,  
Yusuf SAVRAN, Hayri Güner ÖZSAN**  
Department of Hematology-Oncology  
Dokuz Eylül University, Medical School,  
Izmir, TURKEY