

The bone marrow in hereditary cystinosis

Hereditær sistinosisde kemik iliği

Neşre Yaralı, Ali Bay, Pamir Işık, Şükrü Güngör, Gülay Demircin¹

Dr. Sami Ulus Children's Hospital, Department of Pediatric Hematology, ¹Pediatric Nephrology, Ankara, Turkey

The bone marrow in hereditary cystinosis

A two-year-old boy was referred to our pediatric clinic for evaluation of chronic renal failure. His height and weight were below the 3rd percentile for age. Physical examination was significant for an afebrile infant with pallor. In the laboratory findings, white blood cell count was $11.8 \times 10^9/L$, hemoglobin was 8.5 g/dl, mean corpuscular volume (MCV) was 88 fl, and platelet count was $635 \times 10^9/L$. Peripheral blood smear revealed 44% lymphocyte, 10% monocyte and 46% neutrophil with adequate platelets. The venous blood gas analysis showed pH 7.36, pCO₂ 25.5 mmHg and bicarbonate 15 mmol/L. Urinalysis revealed a specific gravity of 1.004 and pH 7, but no blood, leukocyte or glucose. Calcium to creatinine ratio was 0.5 in urine. Serum electrolytes were as follows: sodium 128 mEq/L, potassium 3.1 mEq/L, chloride 88 mmol/L, blood urea nitrogen 93 mg/dl, serum creatinine 1.73 mg/dl, calcium 8.1 mg/dl, and phosphorus 6.7 mg/dl. Liver function tests were normal. Under light microscopic examination, colorless crystals of varying shapes

and sizes were seen in fresh bone marrow aspiration (Figure 1). Wright stain of bone marrow aspiration smear revealed normal erythroid and myeloid cell line with same crystals in the histiocytes (Figure 2). A diagnosis of cystinosis was made and he was treated with cysteamine.

Cystinosis is an autosomal recessive disorder characterized by abnormal cystine crystal accumulation in the reticuloendothelial system (RES), leukocytes, and fibroblasts [1]. For diagnosis, cystine crystals may be detected in the bone marrow, lymph nodes, conjunctivae and rectal mucosa [2]. The infantile form is the severest type, and progressive renal failure causes death within the first decade of life.

References

1. Gebraill F, Knapp M, Perotta G, Cualing H. Crystalline histiocytosis in hereditary cystinosis Arch Pathol Lab Med. 2002;126:1135.
2. Quinn JP, Royston D, Murphy PT. Bone marrow findings in hereditary cystinosis with renal failure Am J Hematol. 2004;76:9.

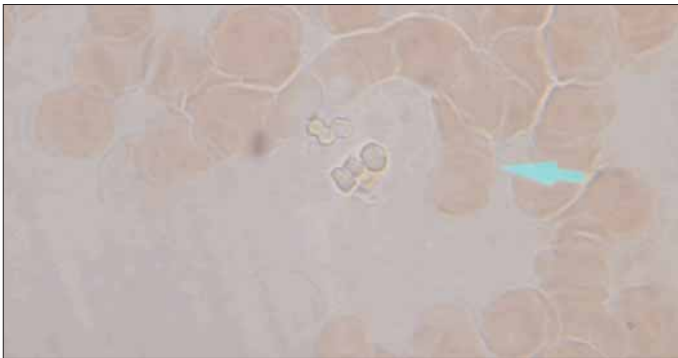


Figure 1. Wright stain of bone marrow aspiration smear revealed normal erythroid and myeloid cell line with same crystals in the histiocytes

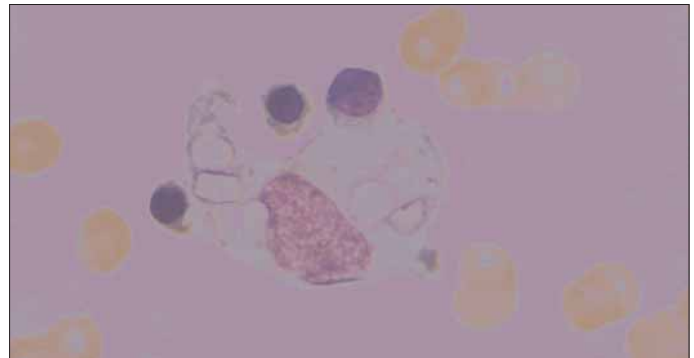


Figure 2. Wright stain of bone marrow aspiration smear revealed normal erythroid and myeloid cell line with same crystals in the histiocytes