

# Hemophagocytic syndrome with erythrocyte phagocytosis by the myeloid precursors in a patient with AML -M2

Mümtaz Yılmaz<sup>1</sup>, Filiz Vural<sup>2</sup>, Mahmut Töbü<sup>2</sup>, Yeşim Ertan<sup>3</sup>, Filiz Büyük<sup>2</sup>

<sup>1</sup>Departments of Internal Medicine, Ege University, Faculty of Medicine, İzmir, Turkey

<sup>2</sup>Departments of Adult Hematology, Ege University, Faculty of Medicine, İzmir, Turkey

✉ filiz.vural@ege.edu.tr

<sup>3</sup>Departments of Pathology, Ege University, Faculty of Medicine, İzmir, Turkey

Received: 10.10.2007 • Accepted: 13.09.2007

## ABSTRACT

Hemophagocytic syndrome is characterized by fever, fatigue, weight loss, lymphadenopathy, and laboratory abnormalities including pancytopenia, liver dysfunction, hypertriglyceridemia and hyperfibrinemia. Histopathologically, lesions are characterized by mononuclear cell infiltration with marked histiocyte proliferation and phagocytosis of erythrocytes, leukocytes, platelets and their precursors by activated macrophages in the reticuloendothelial tissues. Hemophagocytic syndrome may develop from strong immunological stimuli such as severe infection, malignancy and autoimmune diseases.

We present a 73-year-old man with acute myeloblastic leukemia FAB M2 type (AML M2) whose bone marrow histology showed unusual hemophagocytosis by myeloid cells and myeloblasts.

**Key words:** Hemophagocytic syndrome, acute myeloblastic leukemia, AML

## ÖZET

**Myeloid öncül hücreleri ve myeloblastlar tarafından eritroid fagositozu ile seyreden hemofagositik sendromlu AML-M2 olgusu**

Hemofagositik sendrom, ateş, halsizlik, kilo kaybı, lenfadenopati ve pansitopeni, bozulmuş karaciğer fonksiyon testi, hipertrigliseridemi, hiperferritinemi ile karakterli klinik tablodur. Histopatolojik olarak, retiküloendotel dokularında histiositten zengin mononükleer hücre infiltrasyonu ve active makrofajlar tarafından eritrosit, lökosit, platelet ve bunların öncül hücrelerinin fagositozları ile karakterlidir. Hemofagositik sendromun, şiddetli enfeksiyon, malign ve otoimmün hastalıklar gibi güçlü immünolojik uyarılar sonucu geliştiği düşünülmektedir.

**Anahtar kelimeler:** Hemofagositik sendrom, akut myeloblastik lösemi, AML

## INTRODUCTION

Hemophagocytic syndrome (HPS) is an unusual acute syndrome that presents with fever, fatigue, weight loss, profound pancytopenia, hepatosplenomegaly, lymphadenopathy, hypertriglyceridemia, hyper-fibrinemia and abnormal liver function due to widespread tissue infiltration by phagocytosing histiocytes [1]. HPS can be a primary disorder, i.e. familial autosomal recessive trait as seen in children, or a secondary disorder related to infections, malignancies or autoimmune diseases [2-5]. Several malignancies are associated with HPS, the most common being hematological malignancies such as lymphoma, acute leukemia and multiple myeloma [1,6-8]. Histological findings usually include accumulation by the reticuloendothelial system of activated macrophages showing phagocytosis of hematopoietic cells [5,9]. Phagocytosis of hematopoietic cells by the blastic cells has rarely been reported in the literature [10-12].

We present an unusual case of HPS with bone marrow histology showing the phagocytosis of erythrocytes by myeloid precursors, even by myeloblasts, rather than activated macrophages.

## CASE REPORT

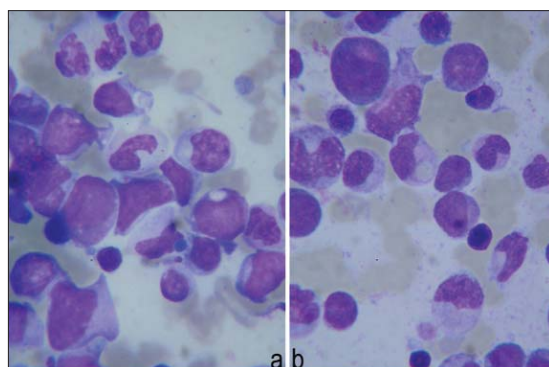
A 73-year-old man was admitted to our Hematology Department with left hypochondriac pain and epistaxis. Physical examination revealed fever higher than 39°C, pallor and hepatosplenomegaly. Laboratory data at presentation were as follows: leukocyte count:  $14 \times 10^9/L$ , platelet count:  $97 \times 10^9/L$ , hemoglobin: 9 g/dl, GGT: 110 U/L, total bilirubin: 1.9 mg/dl, albumin: 2.9 g/dl, lactate

dehydrogenase (LDH): 1147 U/L, triglyceride: 198 mg/dl and ferritin: 19116 mg/L. Peripheral blood smear examination showed presence of 20% myeloblasts. Bone marrow aspiration and biopsy revealed infiltration with 60% myeloblastic cells, and the patient was diagnosed with acute myeloid leukemia (AML) M2. He received a first course of cytosine arabinoside plus idarubicin (7+3) as induction chemotherapy. The fever persisted after the initiation of chemotherapy and broad spectrum antibiotics and antifungal agents were given to the patient for empirical treatment of febrile neutropenia. Infectious pathogens were not identified in the microbiological cultures of the blood, urine and sputum. The viral serology for cytomegalovirus (CMV), Epstein-Barr virus (EBV), hepatitis A, B and C, parvovirus and human immunodeficiency virus (HIV) were all negative. CMV DNA test was also negative. The chest X-ray and high resolution thoracic computerized tomography were normal. Considering the persistent fever, hepatosplenomegaly and pancytopenia, bone marrow aspiration was repeated and we observed phagocytosis of erythrocytes not only by macrophages but also all myeloid precursors, even myeloblasts (Figures 1 a,b and 2 a,b). Bone marrow infiltration with 30% of myeloblasts was present simultaneously.

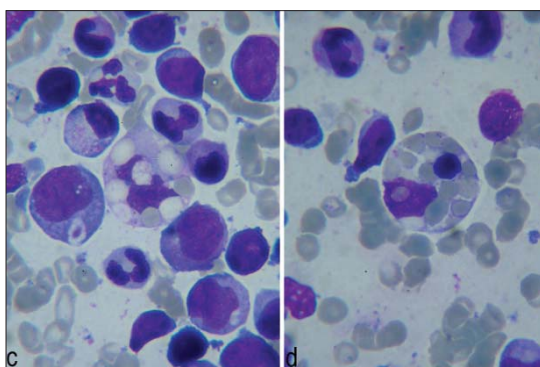
Due to the patient's poor condition, his family requested his discharge from the hospital, and he died at home two days later.

## DISCUSSION

We present herein an unusual case of hemophagocytosis by myeloid cells and myeloblasts. HPS



**Figure 1 (a, b).** Leukemic blasts and granulocytic cells that show hemophagocytosis in the bone marrow aspirate (Hematoxylin and eosin [H&E] x100).



**Figure 2 (c, d).** Macrophages showing hemophagocytosis in the bone marrow aspirate (H&E x 100).

is characterized by systemic activation of benign histiocytes by strong immunological stimuli including severe infections, malignancy, autoimmune disorders and some drugs, showing extensive phagocytosis of hematopoietic cells in reticuloendothelial tissues [1]. Our patient had persistent fever, severe pancytopenia, hepatosplenomegaly, signs of hepatic dysfunction, hyper-fibrinemia and hypertriglyceridemia. He did not respond to either the antimicrobial therapy or chemotherapy. No viral, bacterial or fungal infectious agents were isolated. At the time of diagnosis of AML, hemophagocytosis was not observed. Persistent fever and pancytopenia started after the completion of chemotherapy. The triggering factor for HPS in this patient may have been the drugs used during the combination chemotherapy. However, another interesting point in this case was bone marrow histology showing hemophagocytosis, not only by the activated macrophages but also the myeloid precursors including myeloblasts. There are very few publications in the literature reporting hemophagocytosis by myeloid or blastic cells [10-12]. Two of these papers reported that hemophagocytosis was related to t(16;21) (p11;q22). Imashuku *et al.* [10] reported hemophagocytosis by leukemic blasts in 7 AML patients with t(16;21) (p11;q22). They argued that phagocytic activity in the leukemic blasts might be closely related to specific gene abnormalities. They also claimed that AML patients with t(16;21) (p11;q22) were characterized by their relatively young age (median: 22 years), presence of various subtypes of FAB, and poor prognosis. We could not carry out bone marrow cytogenetic analysis and the age of the patient was advanced, in contrast to the literature, but his disease showed poor prognosis as reported before.

We aimed to share the clinical characteristics and photomicrographs of bone marrow histology of this rarely seen case in light of the related literature. Hemophagocytosis should be kept in mind in patients with uncontrolled persistent fever and unexpected pancytopenia.

## REFERENCES

1. Fallini B, Pileri S, Solas I, Martelli MF, Mason DY, Delsol C, Gatter KC, Fagioli M. Peripheral T-cell lymphoma associated with hemophagocytic syndrome. *Blood* 1990;75:434-44.
2. Okano M, Gross TG. Epstein-Barr virus associated hemophagocytic syndrome and fatal infectious mononucleosis. *Am J Hematol* 1996;53:111-5.
3. Castellona I, Gomez-Martino JR, Hernandez T, Mateos L, Argüello C. *Am J Nephrol* 2000;20:214-6.
4. Garcia-Suarez J, Banas H, Krsnik I, De Miguel D, Reyes E, Burgaleta C. Hemophagocytic syndrome associated with retinoic acid syndrome in acute promyelocytic leukemia. *Am J Hematol* 2004;76:172-5.
5. Henter JI, Arico M, Elinder G, Imashuku S, Janka G. Familial hemophagocytic lymphohistiocytosis. *Hematol Oncol Clin North Am* 1998;12:417-33.
6. Goldschmidt N, Gural A, Kornberg A, Spectre G, Shopen A, Paltiel O. Prolonged fever of unknown origin and hemophagocytosis evolving into acute lymphoblastic leukemia. *Am J Hematol* 2004;76:364-7.
7. Kumar M, Boggino H, Hudnall D, Velagaleti GV. Acute myeloid leukemia associated with hemophagocytic syndrome and t(4;7)(q21;q36). *Cancer Genet Cytogenet* 2000;122:26-9.
8. Demirkan F, Vural F, Ozsan H, Ozcan MA, Ozkal S, Undar B. Hemophagocytic syndrome associated with inappropriate secretion of antidiuretic hormone in lymphoma and acute myeloblastic leukemia: report of two cases. *Leuk Lymphoma* 2001;42:1401-4.
9. Fisman DN. Hemophagocytic syndrome and infection. *Emerging Infect Dis* 2000;6:601-8.
10. Imashuku S, Hibi S, Sako M, Lin Y-W, Ikuta K, Nakata Y, Mori T, Lizuka S, Horibe K, Tsunematsu Y. Hemophagocytosis by leukemic blasts in 7 acute myeloid leukemia cases with t(16;21)(p11;q22). *Cancer* 2000;88:1970-5.
11. Imashuku S, Hibi S, Kuriyama K, Todo S. Hemophagocytosis by leukemic blasts in a case of acute megakaryoblastic leukemia with t(16;21)(p11;q22). *Int J Hematol* 1999;70:36-9.
12. Coulthard S, Chase A, Orchard K, Watmore A, Vora A, Goldman JM, Swirsky DM. Two cases of inv(8)(p11q13) in AML with erythrophagocytosis: a new cytogenetic variant. *Br J Haematol* 1998;100:561-3.