

Reduction of the pseudotumor and chronic joint disease is achieved by prophylactic treatment in severe hemophilia.

Calvarial localization of a pseudotumor is unusual [2]. Inflammation due to hematoma causes immune reaction and affects nearby tissues. The skull tables provide natural protection from soft tissues being eroded [3]. All intradiploic lesions should be suspected to be hematomas unless proven otherwise in patients with coagulopathies [2].

Total surgical removal of the hematoma is the treatment of choice. Some authors recommend cosmetic cranioplasty within the same surgical procedure [4]. However, most of them prefer to preserve the intact inner table [5]. According to us, the elastic inner table must be preserved to avoid postoperative complications. Acceptable bone remodeling was seen in the seventh year of follow-up in control CT images. However, a noncompressible inner table must be excised.

In summary, intradiploic hematoma must be expected when an intradiploic lesion is seen with hemophilia. The main part of the surgery is the preservation of the inner table of the cranium in hemophilic patients. Bone remodeling gives good results with time.

Keywords: Hemophilia A, Intradiploic hematoma, Coagulopathy, Intraosseous

Anahtar Sözcükler: Hemofili A, İntradiploik hematoma, Koagülopati, İntraosseöz

Conflict of Interest: The authors of this paper have no conflicts of interest, including specific financial interests, relationships, and/or affiliations relevant to the subject matter or materials included.

References

1. Rodriguez-Merchan EC. Musculo-skeletal manifestations of haemophilia. *Blood Rev* 2016;30:401-409.
2. Mobbs RJ, Gollapudi PR, Fuller JW, Dahlstrom JE, Chandran NK. Intradiploic hematoma after skull fracture: case report and literature review. *Surg Neurol* 2000;54:87-91.
3. Reeves A, Brown M. Intraosseous hematoma in a newborn with factor VIII deficiency. *AJNR Am Neuroradiol* 2000;21:308-309.
4. Tokmak M, Ozek E, Iplikçioğlu C. Chronic intradiploic hematomas of the skull without coagulopathy: report of two cases. *Neurocirugia (Astur)* 2015;26:302-306.
5. Dange N, Mahore A, Avinash KM, Joshi V, Kawale J, Goel A. Chronic intradiploic hematoma in patients with coagulopathy. *J Clin Neurosci* 2010;17:1047-1049.



Address for Correspondence/Yazışma Adresi: Hakan HANIMOĞLU, M.D.,
İstanbul Bilim University Faculty of Medicine, Department of Neurosurgery, İstanbul, Turkey
Phone: +90 533 544 69 00
E-mail : drhakanhanimoglu@hotmail.com

Received/Geliş tarihi: June 29, 2016
Accepted/Kabul tarihi: September 09, 2016

DOI: 10.4274/tjh.2016.0254

The Second and Third Hemoglobin Kansas Cases in the Turkish Population

Türk Popülasyonundaki İkinci ve Üçüncü Hemoglobin Kansas Olguları

Zeynep Kayra Tanrıverdi¹, Arzu Akyay², Aşkın Şen³, Çağatay Taşkapan⁴, Ünsal Özgen²

¹İnönü University Faculty of Medicine, Department of Pediatrics, Malatya, Turkey

²İnönü University Faculty of Medicine, Department of Pediatric Hematology and Oncology, Malatya, Turkey

³Fırat University Faculty of Medicine, Department of Medical Genetics, Elazığ, Turkey

⁴İnönü University Faculty of Medicine, Department of Biochemistry, Malatya, Turkey

To the Editor,

We read with great interest the article by Keser et al. [1] regarding the first observation of hemoglobin Kansas in Turkey. The authors described a patient from Malatya as the first case of hemoglobin Kansas in the Turkish population. After the publication of this paper, we had two other hemoglobin Kansas cases from the Malatya region.

Case 1: A 16-year-old female patient was admitted with the

complaint of cyanosis of her lips and nails since birth, but she had no problems in her daily life. In her family history, there were other relatives who had the same complaints (Figure 1a). Physical examination of our patient indicated slight cyanosis of her lips, nail beds, and skin (Figure 2). Other system examinations were normal. Transcutaneous oxygen saturation was detected as 50%. Her complete blood count, electrocardiogram, echocardiogram, methemoglobin level, and peripheral blood smear were normal. In blood gas values, pH was 7.39, PCO₂ was 41.1 mmHg, PO₂ was 66.3 mmHg, and the P50 value was 66.94 (normal value: 24-

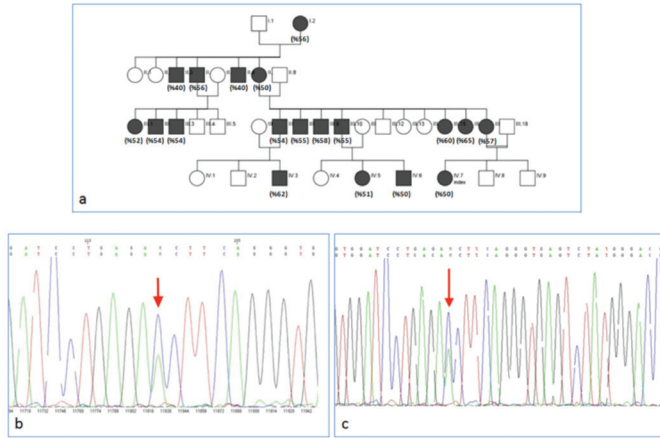


Figure 1. a) Family tree of the patients (transcutaneous oxygen saturations of the affected individuals are shown in parentheses); b) hemoglobin Kansas in DNA sequencing of case 1; c) hemoglobin Kansas in DNA sequencing of case 2.

29). Hemoglobin electrophoresis revealed HbA1 of 56.3%, HbA2 of 43.5%, and HbF of 2%. In beta-globulin gene DNA sequence analysis, c.308 A>C (β 102(G4) Asn>Thr) (Hb Kansas) mutation was detected (Figure 1b).

Case 2: A 43-year-old patient, the mother of Case 1, was admitted with the same complaints as her daughter. Transcutaneous oxygen saturation showed low oxygen levels (PO_2 57%). Complete blood count, blood chemistry, and cardiac echocardiography were within normal limits. High-performance liquid chromatography results were as follows: HbA1 57.2%, HbA2 42.5%, HbF 0.2%. DNA sequencing revealed the same A to C substitution at nucleotide position 308 as in the first case (Figure 1c).

Hemoglobin Kansas is a rare, unstable, abnormal hemoglobin variant with low oxygen affinity in which asparagine is replaced with threonine in the 102nd position of the β -globin chain [2,3]. In these patients, hemoglobin leaves more than the normal amount of oxygen to extrapulmonary tissues. Therefore, tissues get oxygenated even at low hematocrit levels and patients appear to be healthy. However, cyanosis is seen because the unsaturated hemoglobin amount in the capillaries and veins is higher than 5 g/dL [4]. The P50 values of these patients are also high [5,6].

In total, six hemoglobin Kansas cases were reported from 1968 to date in the world literature [2,3,4,5]. The first hemoglobin Kansas case in Turkey was reported in 2015 [1]. Our patients and 17 other family members who had the same phenotype are more than all of the reported cases in the world literature. We could not perform hemoglobin electrophoresis and genetic evaluations of the other 17 family members because they were living in other



Figure 2. A photograph of case 1 showing cyanosis of her lips. cities. However, these patients had low transcutaneous oxygen saturations, as shown in parentheses in Figure 1a. Hemoglobin Kansas and other unstable hemoglobinopathies with low oxygen affinity should be considered in the differential diagnosis of patients with unexplained peripheral cyanosis.

Keywords: Abnormal hemoglobins, Hb Kansas

Anahtar Sözcükler: Anormal hemoglobinler, Hb Kansas

Conflict of Interest: The authors of this paper have no conflicts of interest, including specific financial interests, relationships, and/or affiliations relevant to the subject matter or materials included.

References

1. Keser İ, Öztaş A, Bilgen T, Canatan D. First observation of hemoglobin Kansas [β 102(G4)Asn→Thr, AAC>ACC] in the Turkish population. *Turk J Hematol* 2015;32:371-375.
2. Bonaventura J, Riggs A. Hemoglobin Kansas, a human hemoglobin with a neutral amino acid substitution and an abnormal oxygen equilibrium. *J Biol Chem* 1968;243: 980-991.
3. Morita K, Fukuzawa J, Onodera S, Kawamura Y, Sasaki N, Fujisawa K, Ohba Y, Miyaji T, Hayashi Y, Yamazaki N. Hemoglobin Kansas found in a patient with polycythemia. *Ann Hematol* 1992;65:229-231.
4. Bonini-Domingos CR, Calderan PH, Siqueira FA, Naoum PC. Hemoglobin Kansas found by electrophoretic diagnosis in Brazil. *Rev Bras Hematol Hemoter* 2002;24:37-39.
5. Zimmermann-Baer U, Capalo R, Dutly F, Saller E, Troxler H, Kohler M, Frischknecht H. Neonatal cyanosis due to a new G γ -globin variant causing low oxygen affinity: Hb F-Sarajevo [G γ 102 (G4) Asn→ Thr, AAC> ACC]. *Hemoglobin* 2012;36:109-113.
6. Riggs A, Gibson QH. Oxygen equilibrium and kinetics of isolated subunits from hemoglobin Kansas. *Proc Natl Acad Sci U S A* 1973;70:1718-1720.



Address for Correspondence/Yazışma Adresi: Arzu AKYAY, M.D.,
İnönü University Faculty of Medicine, Department of Pediatric Hematology and Oncology, Malatya, Turkey
Phone: +90 422 341 06 60/5319
E-mail : arzuakyay@yahoo.com

Received/Geliş tarihi: July 29, 2016
Accepted/Kabul tarihi: January 03, 2017

DOI: 10.4274/tjh.2016.0297