
The Differential Diagnosis of Lymphocyte-rich Classical Hodgkin's Lymphoma and Lymphocyte Predominant Hodgkin's Lymphoma Using the R.E.A.L. Criteria. An Immunohistochemical Study on 45 Cases

Mine HEKÝMGÝL, Saliha SOYDAN, Bařak DOĐANAVbARGÝL YAKUT, Yeřim ERTAN

Department of Pathology, Faculty of Medicine, Ege University, Ýzmir, TURKEY

ABSTRACT

In the present study, the two types, lymphocyte-rich classical HL (LRCHL) and nodular lymphocyte-predominant type (NLPHL), which were grouped together before the R.E.A.L. classification, were questioned on the basis of differential criteria and 45 cases were retrieved from last ten years' archival material. On histopathological examination, nodular pattern, the cytological features and intensity of Reed-Sternberg (RS) cells, the pattern and intensity of histiocytes, the presence of germinal centers with progressive transformation were analysed. An immunohistochemical study was performed using antibodies against CD20, CD45RO, CD3, CD30, CD15 antigens and streptavidin-biotin procedure. The cases were classified into three groups according to the histologic pattern and immunophenotypical features of the RS cells: I) diffuse, LRCHL (CD20⁻, CD30^{+/-}, CD15^{+/-}): n= 28; II) NLPHL (CD20⁺, CD30⁻, CD15⁻): n= 11; III) cases which could not be evaluated in former groups: n= 6. Four cases in the latter group showed a nodular pattern with RS cells negative for all markers, except for one case, which expressed both CD20 and CD15. The remaining two cases exhibited a diffuse pattern and the RS cells were CD20⁺, co-expressing CD30 in one. These findings suggest that, differential diagnosis according to the R.E.A.L. criteria is not distinctive between the two categories of HL in about 13% of cases, and further criteria need to be established to define the grey zone between the two entities which might lead to further therapeutic trials.

Key Words: Hodgkin's disease, Classification, Immunophenotype.

Turk J Haematol 2000;17(4):163-170.

INTRODUCTION

On the basis of a combination of immunophenotype and morphologic features, The Revised European-American lymphoma (R.E. A.L.) classification has included Hodgkin's disease in a lymphoma classification and recognised two main types of HL: Classical types (nodular sclerosis, lymphocyte-rich classical, mixed cellularity, and lymphocyte depletion) and nodular lymphocyte-predominant type^[1]. It is now clear that Hodgkin's disease is indeed a lymphoma, so the new World Health Organization (WHO) classification of hematologic neoplasms, which is currently in preparation, proposes to recognise this by changing the name to Hodgkin's lymphoma (HL) and groups HL under two categories as proposed by the R.E.A.L. classification^[2]. Recent studies incorporating immunophenotypic and histopathologic data, have provided evidence on the fact that these two types probably are distinct biologic entities^[3-11]. Furthermore, large-scale clinical trials have started defining clinical and prognostic differences between the two groups^[5,12,13].

The aim of the present study is to evaluate the differential criteria between the lymphocyte-rich classical (LRCHL) and nodular lymphocyte predominant (NLPHL) types, which had been grouped as a single entity before the R.E.A.L. classification. The archival material of last ten years have been reviewed and 45 cases of HL with mainly lymphocytic and histiocytic background and available tissue sections were included for further analysis and immunohistochemical study.

MATERIALS and METHODS

The 45 cases with initial diagnosis of lymphocyte-rich or lymphocyte predominant HL on lymph node biopsies were retrieved from the ten-year archival material of a total of 363 cases of HL. The age range was between 6 and 72 years (mean 34 years) and male to female ratio was^[3,5].

The criteria examined by histopathologic evaluation were nodular or diffuse pattern, the cytological features and concentration of Reed-Sternberg (RS) cells and variants, the distribution pattern and concentration of histiocytes, the presen-

ce of germinal centers with progressive or regressive transformation, interfollicular involvement, and the type of cells forming the background. The concentration of RS cells and variants and histiocytes were graded as follows: 3+, easily identified on x10 power; 1+, few cells hardly identified by scanning on x40 power; 2+, cases in between grade 1 and 2.

Antibodies against CD20, CD45RO, CD3, CD30, and CD15 antigens were studied immunohistochemically on 4 µm thick sections prepared on Poly-L-Lysine coated slides from formalin or B5-formalin fixed, paraffin embedded tissue sections. The immunohistochemical procedure defined below was performed by using streptavidin-biotin-peroxidase (LSAB2 kit, Dako, Denmark) reaction with a series of negative controls and evaluated without knowledge of histopathologic diagnosis and the results were correlated later.

Immunohistochemical Procedure

Briefly, after overnight incubation of sections at 54°C, the routine deparaffinization and rehydration steps were followed. Endogenous peroxidase activity was blocked by incubating the sections with 3% hydrogen peroxide for five minutes and washed in distilled water. For antigen retrieval, sections were incubated in sodium citrate buffer (0.01 mol/L, 6.0 pH) for two 5 minute cycles in a household microwave oven (600 W). After cooling to room temperature, sections were washed twice with distilled water and once with TRIS buffer (TBS) and incubated for 30 minutes at room temperature with primary antibodies, L26, UCHL-1, anti-CD3, BerH2, and LeuM1 (prediluted, Dako, Denmark), followed by sequential 30 minute incubations with biotinylated link antibody and peroxidase labelled streptavidin. A specific rabbit-anti-mouse IgM antibody was used as secondary antibody for sections stained for LeuM1. Between each step, sections were washed twice in Tris-buffered saline (TBS) solution for five minutes at room temperature. The final step for localisation of the peroxidase deposition was achieved by diaminobenzidine (Dako, Denmark) chromogenic reaction, followed by counterstaining with hematoxylin, dehydration, and mounting. Primary antibodies were omitted in negative controls and rep-

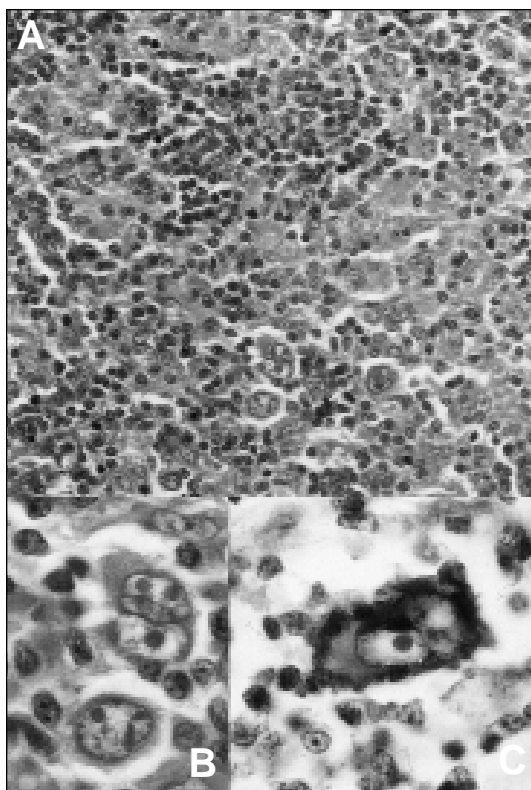


Figure 1. The Reed-Sternberg cells and mononuclear variants in lymphocyte-rich classical Hodgkin's lymphoma with a diffuse pattern (HE x 400) (A), (HE x 1000) (B), CD30 positivity in Reed-Sternberg cells (DAB x 1000) (C).

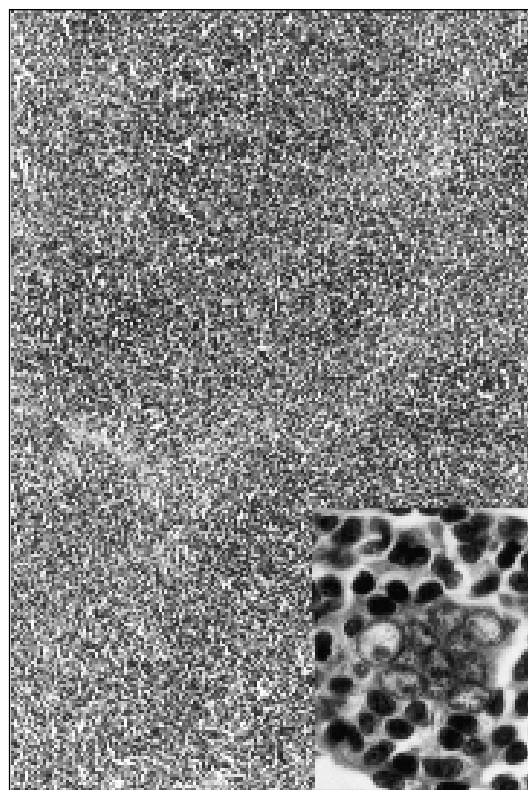


Figure 2. The nodular pattern in lymphocyte predominant Hodgkin's lymphoma (HE x 100) and a popcorn cell with multilobulated nucleus (HE x 1000) (inset).

laced by nonimmune serum.

Evaluation of Immunohistochemical Reactions

The results were considered as positive when at least 20% of RS cells and variants were stained with the specific antibody.

RESULTS

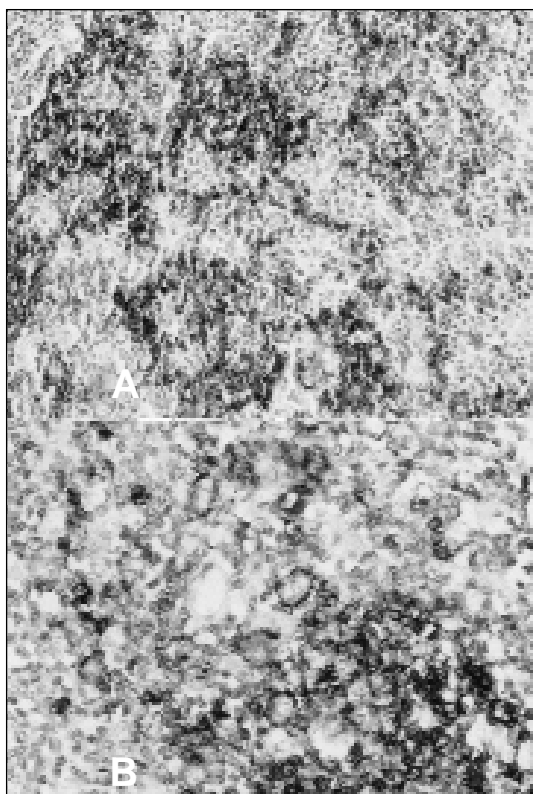
The cases were divided into three categories after immunohistochemical and histopathologic evaluation:

1. LRCHL with CD20⁻, CD30^{+/-}, CD15^{+/-} RS cells and diffuse pattern (n= 28, age 6-72 years [mean 32 years], male: female ratio 3.7).

On histopathological evaluation, RS cells were of classical type and scarce in 20%, abundant

in 40% and histiocytes were scarce in 25%, numerous in 50% (Figure 1 A, B). The remaining background cells were predominantly lymphocytes with a few plasma cells or eosinophils scattered throughout the node. Other histopathological features of interest were regression of germinal centers in 25% and interfollicular involvement in 18%.

On immunohistochemical examination, CD20 was positive in residual lymphoid aggregates and follicles, and negative in RS cells. The background small lymphocytes diffusely infiltrating the nodes were positive with both T cell markers, CD3 and CD45RO. In three cases small T cells forming prominent rosettes around RS cells were identified. Plus, one case demonstrated cytoplasmic CD3 and CD45RO positivity in RS cells. Cases in



Group I exhibited four different patterns of CD30 Figure 3. The "moth-eaten" nodular appearance of CD20 positivity in nodular lymphocyte predominant Hodgkin's lymphoma (DAB x 200) (A) and CD20 positivity in popcorn cells (DAB x 400) (B).

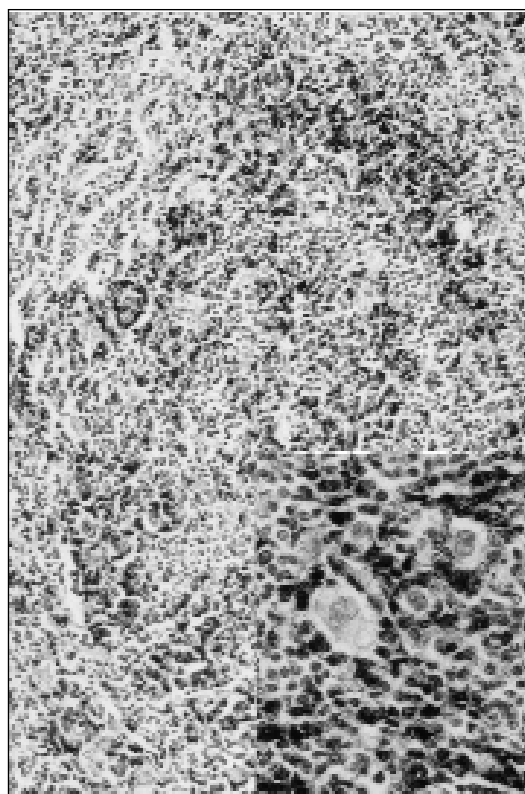


Figure 4. The nodular pattern of CD45RO positivity in nodular lymphocyte predominant Hodgkin's lymphoma (DAB x 200) and T cells forming prominent rings around the popcorn cells (DAB x 400) (inset).

and CD15 immunopositivity in RS cells (Figure 1C):

1. CD30⁺, CD15⁺: n= 4, 2) CD30⁺, CD15⁻: n= 10, 3) CD30⁻, CD15⁺: n= 5, 4) CD30⁻, CD15⁻:

Table 1. Histopathologic and immunohistochemical features of cases in Group III (n=6)

Case no.	Age	Sex	Histologic pattern	RS cells	Histiocytes	CD20		CD3		CD30	CD15
						RS cells	Irregular nodules	Pattern	Rings around RS cells		
1	37	M	N	3+	1+	-	-	N	-	-	-
2	15	M	N	2+	3+	-	+	BN	-	-	-
3	32	M	N	1+	1+	-	+	N	+	-	-
4	68	M	D	3+	3+	+	-	N	-	-	-
5	44	F	N	3+	3+	+	+	N	+	-	+
6	33	F	D	3+	3+	+	-	D	-	+	-

N: Nodular, D: Diffuse, BN: Between nodules

n= 9.

2. NLPHL with CD20⁺, CD30⁻, CD15⁻ RS cells (n= 11, age 21-60 years [mean 36 years], male: female ratio 4).

The histopathological examination of this group revealed RS cells of lymphocytic-histiocytic type (so-called popcorn cells or L&H cells), which were abundant in 27% and scarce in 27% (Figure 2). In 27% classical RS cells were accompanying the L&H cells. Histiocytes were only few in 45% and numerous in 10%. The remaining cells forming the background were small lymphocytes. In 27% of cases progressive transformation of germinal centers (PTGC) were identified.

The nodular pattern, which became more apparent on CD20 staining, showed three prominent patterns: 1) the irregular staining giving a "moth-eaten" appearance to nodules (Figure 3A): n= 8, 2) solid positivity of nodules: n= 2, 3) heavier staining around the nodules: n= 1. In all cases, intracytoplasmic CD20 positivity was prominent in L&H cells (Figure 3B). The background lymphocytes of Group II showed diverse staining patterns with both T cell markers, CD3 and CD45RO:

1. Prominent nodular pattern (Figure 4): n= 4,
2. Diffuse pattern: n= 5,3) staining confined to lymphocytes localised in internodular areas: n= 2. A small T cell population forming aggregates and prominent rings around the CD20⁺ L&H cells were encountered in three cases (Figure 4, inset). No staining of either CD30 or CD15 was noted in L&H cells.
3. Cases not classified into above-mentioned groups with available immunophenotypical and histopathologic criteria (n= 6).

The age and gender distribution, histologic pattern and immunohistochemical features of unclassified cases (%13) are given in Table 1. Case 1 had regression of germinal centers, case 2 showed PTGC, and case 4 exhibited both regression of germinal centers and interfollicular pattern.

DISCUSSION

Today, it's well known that NLPHL is a distinct

entity arising from B cells and should be differentiated from classical subtypes of HL^[1,2]. The classical subtypes are characterised by CD20⁻, CD30⁺ and/or CD15⁺ classical RS cells and diffuse pattern, meanwhile NLPHL differs in its unique cellular and immunophenotypical composition, CD20⁺, CD30⁻, CD15⁻ L&H cells and nodular pattern^[1-9]. The study group consists of only nodal HL with a predominance of lymphocytic background, and 87% have been classified by the histopathologic and immunophenotypical criteria established by the R.E.A.L. project as LRCHL (group I; n=28) or NLPHL (group II; n= 11).

LRCHL confines about 5-6% of all HL in large series (5,9) and 7.5% in our series. The average age is 32 years, similar to the series of European Task Force on Lymphoma (ETFL) and male ratio is 79%, higher than the ETFL series, which was reported as 69%^[12]. On the other hand, NLPHL occupies 5% or less of HL in large series, mean age of patients is reported between 18 and 35 years and 70% to 74% of patients are male^[5,9,12]. In our study, NLPHL consists of 3% of all HL with a mean age of 36 years, and 80% are male.

Several studies have addressed the impact of immunophenotyping in adjunct to routine histopathologic examination on the differential diagnosis of NLPHL and LRCHL, unfortunately a grey zone still exists which causes further problems for both the pathologists and the clinicians^[7,10]. In the present study, 13% of cases with a heavy lymphocytic and histiocytic background (group III; n= 6) could not be classified as either LRCHL or NLPHL, with the defined R.E.A.L. criteria. The histologic pattern of these cases was diffuse in two and nodular in four. In a study from the German Hodgkin Study Group (GHSG), expert pathologists have diagnosed 104 cases of NLPHL by morphologic analysis alone, and reclassified the cases after immunohistochemical examination and their diagnosis were confirmed in only three quarters of all cases, the rest receiving the diagnosis of classical HL^[5]. The authors have concluded that an aberrant phenotype was identified in 20% of NLPHL. In an immunophenotyping study performed by the ETFL group on 426 cases with initial diagnosis of NLPHL, the diagnosis was confirmed in about

half, meanwhile one fourth were re-classified as LRCHL with RS cells and variants occupying the interfollicular regions and mantle zones mimicking a nodular pattern^[12]. These cases have been defined as follicular HL^[14]. Meanwhile, most cases of LPHL have been defined as having at least a partially nodular growth pattern, and diffuse areas are present in a minority. Although some authors report that about 4% present in diffuse form throughout the node^[1,5], it is still controversial whether purely diffuse cases of LPHL exist. Thus, some cases of LRCHL and NLPHL may closely resemble each other when lymphocyte and histiocyte rich background and histologic pattern are considered as the only criteria and further detailed morphologic analysis of RS cells is required for correct diagnosis.

The L&H cells of NLPHL are characterised by vesicular, polylobated large nuclei and distinct but small, usually peripheral nucleoli, without perinuclear halos^[1]. But Harris, who is also a member of the R.E.A.L. group, have noted that in some cases neoplastic cells of LRCHL might closely resemble L&H cells^[9]. So it seems like immunophenotyping of neoplastic cells should be the main differential criteria in adjunct to morphologic analysis. Similar to the finding of ETFL and GHSG series concluding that the clinical and histopathologic features of LRCHL seem to be intermediate between those of NLPHL and classical HL, the immunophenotypic profile of RS cells in LRCHL have been shown to express CD20 positivity in a minority of cases, causing further problems of differential diagnosis from NLPHL^[1,5-7,9,10,12,14]. Furthermore, immunohistochemical studies on NLPHL have concluded that CD30 is coexpressed in less than 8% and these cases should not be diagnosed as classical HL^[5]. When we tried to distinguish the cases of the unclassified group by immunophenotypic criteria, two cases presenting with purely diffuse pattern expressed CD20 in neoplastic cells, plus one coexpressed CD30. Of the four cases with a prominent nodular pattern, three did not express any of the markers used in the panel, but one presented CD20⁺, CD30⁻ and CD15⁺ RS cells.

The immunophenotype of background

lymphocytes is another valuable criteria in the differential diagnosis LRCHL and NLPHL, since a diffuse T cell population predominates the LRCHL, meanwhile CD20⁺ small B lymphocytes form the nodules of NLPHL, and often, it is easier to identify the nodules by CD20 staining^[1,9]. Another distinctive feature of CD20 staining is the broken-up, moth-eaten appearance of follicles with irregular contours, which might also be used in the differential diagnosis from PTGC^[9,11]. However in four cases of NLPHL, nodules contained numerous reactive small T lymphocytes demonstrating a paradoxical staining of CD3, which concentrated rather within the nodules similar to the staining pattern of B cells in germinal centers. This phenomenon was striking in NLPHL, as also mentioned by Nguyen et al. confirming that some nodules of NLPHL may contain more numerous T cells compared to B cells^[11]. Meanwhile Harris has concluded that some cases of LRCHL may have a diffuse background B cell population^[9]. Two of the unclassified cases exhibiting a totally diffuse pattern in Group III, CD20⁺ background lymphocytes were actually residual cells without any discernible nodular pattern. But another interesting finding was the nodular arrangement of CD3⁺ small lymphocytes in one, similar to what we have noted in NLPHL. Also, a case with prominent nodular pattern, showed a distinctive nodular staining with both CD20 and CD3, with T cell aggregates forming rings around CD20⁺ and CD15⁺ RS cells. Thus, it is not only the immunophenotypic characteristics of RS cells, but also the phenotypic features and staining patterns of background lymphocytes, making group III unclassifiable.

When patients presenting at the same stage are compared, LRCHL and NLPHL do not show statistically different response rates to therapy, but late and multiple relapses are more common in NLPHL, however they respond better to therapy, but transformations to secondary low grade non-Hodgkin's lymphoma are encountered more frequently^[8,9,12]. The cause of death is often secondary malignancies or complications of treatment, rather than HL, so limited chemotherapy and radiotherapy and experimental therapies such as immunotherapy are new strategies for the treatment of NLPHL, and some recommend to follow-up the

cases with no residual disease during the post-op period^[12,13]. Various studies have confirmed the centroblastic origin of L&H cells by newly developed molecular biologic techniques^[15,16]. Furthermore, it has also been shown that the RS cells of classical HL also develop from germinal center B cells, but because of the mutations they have gone through they lose their ability to present functional antigen receptors^[17]. Although the origin of neoplastic cells in NLPHL is similar to classical HL and most cases can be diagnosed by routine histopathological work-up with the aid of immunohistochemistry, in about 13%, as presented in the study, there still are problems of differential diagnosis. Thus we need more strict criteria for the differential diagnosis and development of specific therapy protocols for the two entities.

REFERENCES

1. Harris LH, Jaffe ES, Stein H, Banks PM, Chan JKC, Cleary ML, Delsol G, De Wolf-Peeters C, Falini B, Gatter KC, Grogan TM, Isaacson PG, Knowles DM, Mason DY, Müller-Hermelink HK, Pileri SA, Piris MA, Ralfkiaer E, Warnke RA. A Revised European-American Classification of lymphoid neoplasms: A proposal from the International Lymphoma Study Group. *Blood* 1994;84:1361-92.
2. Jaffe ES, Harris NL, Diebold J, Müller-Hermelink HK. World Health Organization Classification of lymphomas: A work in progress. *Ann Oncol* 1998;9 (Suppl 5):25-30.
3. Pinkus GS, Said JW. Hodgkin's disease, Lymphocyte predominance type, nodular: A distinct entity? *Am J Pathol* 1985;118:1-6.
4. Mason YD, Banks PM, Chan J, Cleary ML, Delsol G, de Wolf Peeters C, Falini B, Gatter K, Grogan TM, Harris NL, Isaacson PG, Jaffe ES, Knowles DM, Müller-Hermelink HK, Pileri S, Ralfkiaer E, Stein H, Warnke R. Nodular lymphocyte predominance Hodgkin's disease. *Am J Surg Pathol* 1994;18:526-30.
5. Von Wasielewski R, Werner M, Fischer R, Hansmann M-L, Hübner K, Hasenclever D, Franklin J, Sextro M, Diehl V, Georgi A. Lymphocyte-predominant Hodgkin's disease. An immunohistochemical analysis of 208 reviewed Hodgkin's disease cases from the German Hodgkin Study Group. *Am J Pathol* 1997;150:793-803.
6. Von Wasielewski R, Mengel M, Fischer R, Hansmann M-L, Hübner K, Franklin J, Tesch H, Paulus U, Werner M, Diehl V, Georgi A. Classical Hodgkin's disease: Clinical impact of the immunophenotype. *Am J Pathol* 1997;151:1123-30.
7. Rüdiger T, Jaffe ES, Delsol G, deWolf-Peeters C, Gascoyne RD, Georgii A, Harris NL, Kadin ME, MacLennan KA, Poppema S, Stein H, Weiss LE, Müller-Hermelink HK. Workshop report on Hodgkin's disease and related diseases ("grey zone" lymphoma). *Ann Oncol* 1998;9 (Suppl 5):31-8.
8. Franklin J, Tesch H, Hansmann M-L, Diehl V. Lymphocyte predominant Hodgkin's disease: Pathology and clinical implication. *Ann Oncol* 1998;9 (Suppl 5):39-44.
9. Harris NL. The many faces of Hodgkin's disease around the world: What have we learned from its pathology? *Ann Oncol* 1998;9 (Suppl 5):45-56.
10. Rüdiger T, Ott G, Ott MM, Müller-Deubert SM, Müller-Hermelink HK. Differential diagnosis between classic Hodgkin's lymphoma, T-cell-rich B-cell lymphoma, and paragranuloma by paraffin immunohistochemistry. *Am J Surg Pathol* 1998;22:1184-91.
11. Nguyen PL, Ferry JA, Harris NL. Progressive transformation of germinal centers and nodular lymphocyte predominance Hodgkin's disease. A comparative immunohistochemical study. *Am J Surg Pathol* 1999;23:27-33.
12. Diehl V, Sextro M, Franklin J, Hansmann M-L, Harris NL, Jaffe E, Poppema S, Harris M, Franssila K, van Krieken J, Marafioti T, Anagnostopoulos I, Stein H. Clinical presentation, course, and prognostic factors in lymphocyte-predominant Hodgkin's disease and lymphocyte-rich classical Hodgkin's disease: Report from the European Task Force on Lymphoma Project on lymphocyte-predominant Hodgkin's disease. *Clin Oncol* 1999;17(3):776-83.
13. Karayalçın G, Behm FG, Gieser PW, Kung F, Weiner M, Tebbi CK, Ferree C, Marcus R, Constine L, Mendenhall NP, Chauvenet A, Murphy SB. Lymphocyte predominant Hodgkin disease: Clinicopathologic features and results of treatment-The Pediatric Oncology Group experience. *Med Pediatr Oncol* 1997; 29:519-25.
14. Ashton-Key M, Thorpe PA, Allen JP, Isaacson PG. Follicular Hodgkin's disease. *Am J Surg Pathol* 1995; 19:1294-9.
15. Ohno T, Stribley JA, Wu G, Hinrichs SH, Weisenburger DD, Chan WC. Clonality in nodular lymphocyte-predominant Hodgkin's disease. *N Engl J Med* 1997;337:459-65.
16. Marafioti T, Hummel M, Anagnostopoulos I, Foss H-D, Falini B, Delsol G, Isaacson PG, Pileri S, Stein H. Origin of nodular lymphocyte-predominant Hodgkin's disease from a clonal expansion of highly mutated germinal-center B cells. *N Engl J Med* 1997; 337:453-8.
17. Küppers R, Hansmann ML, Rajewsky K. Clonality and germinal centre B-cell derivation of Hodgkin/Reed-Sternberg cells in Hodgkin's disease. *Ann*

Oncol 1998;9 (Suppl 5):17-20.

Address for Correspondence:

Mine HEKÝMGÝL, MD

Department of Pathology
Faculty of Medicine Aegean University
Bornova, Ýzmir, TURKEY