



# Microsurgical apicoectomy with retro filling in a patient with extensive periapical lesion in maxilla - A case report

 Justyna Klepacz- Szewczyk,  Katarzyna Fabjanska

*Department of Endodontics, Medical University, Łódź, Poland*

The goal of modern dentistry should be to maintain patients' dentition for as long as possible. Microsurgical apicoectomy is a predictable and safe solution worth considering in the treatment of periapical diseases. The aim of our work was to present a method of dealing with a large lesion in the maxilla. The article describes surgical management in a case of a large periapical cyst with probable traumatic origin. A 45-year-old male patient reported a large radiolucent area in the region of the teeth 11–13, suggesting bone resorption with an irregular contour. The procedure consists of curettage of periapical bone, root resection, and retrograde filling. Surgery was carried out with local infiltration anesthesia. A sulcular, full-thickness flap was designed. The resection of the root apices of teeth 11 and 12 was performed, and retrograde filling was implemented. The patient was recalled after 5 days for the removal of sutures and evaluation of treatment. The patient underwent the procedure without any complications and did not report pain or swelling after surgery. During the control visit, there was a bone reconstruction visible on periapical X-rays. Minimal scarring was noticeable, and the patient was content with the esthetic result without any pain or discomfort. Endodontic microsurgery is a widely studied procedure. It is recommended to use suitable equipment, instruments, and materials that match biological concepts.

**Keywords:** Endodontic microsurgery; microsurgical apicoectomy; periapical lesion; retrograde filling; root resection.

## Introduction

The aim of conventional root canal therapy is to eradicate bacteria from the root canal system. We are dealing with the continuous development of instrument systems for the preparation of root canal space, reviews of the composition and sequence of use of irrigating solutions, and evolving research on the materials for filling the tooth's root canal system. Unfortunately, classical endodontic treatment is not 100% successful. Endodontic therapy may have unfavorable outcomes for reasons not necessarily dependent

on the operator. The presence of anatomical anomalies, an isthmus, additional canals, or obliteration of the canal system may obstruct proper root canal treatment (1). Previous injuries in the area of the teeth may also influence the success rate of endodontic therapy.

The most common periapical inflammatory lesions occurring in the oral cavity are: granulomas (periodontitis periapicalis chronica), periapical abscesses and pocket or true cysts (cystis radicularis). Pocket cysts have a direct connection to the infected root canal system, whereas

Cite this article as: Klepacz- Szewczyk J, Fabjanska K. Microsurgical apicoectomy with retro filling in a patient with extensive periapical lesion in maxilla - A case report. Turk Endod J 2023;8:172-179.

Correspondence: Justyna Klepacz- Szewczyk. Department of Endodontics, Medical University, Łódź, Poland  
Tel: +48 – 50 832 51 51 e-mail: justynaklepacz@gmail.com

Submitted: August 09, 2023 Revised: September 25, 2023 Accepted: September 25, 2023

©2023 Turkish Endodontic Society



true cysts are independent of the root (2, 3): Periapical, chronic inflammatory lesions usually go on without any clinical symptoms for long periods of time. Often, they are discovered, somewhat by accident, as a radiolucency of bone, usually in the region of the apex of the tooth, on a standard ortopantomogramic X-ray.

There is an agreement among dentists that granulomas should heal after properly performed root canal treatment, while cysts require surgical removal. For years, it was believed that the size of the bone cavity visible on an X-ray was an indication for determining which of the inflammatory processes was taking place. The final diagnosis, however, is set by histopathological examination, and nowadays, the size of the lesion on an X-ray is not taken into account. The first-line approach to treating periapical lesions should always be root canal treatment. When conventional root canal therapy fails, endodontic surgery is worth considering in periapical disease treatment.

Periapical tissue regeneration is accomplished by the surgical removal of periapical pathologic tissue and any present irritants, such as extruded material or a broken instrument protruding outside the apex. The apical 3 mm of the root should be cut off so that all portals of exit, like lateral canals and deltas, will be removed. Then a minimum of 3 mm of retrograde preparation should be performed, and the preparation site should be sealed with biocompatible, durable, and preferably hydrophilic material.

Indications for periapical surgery, according to Velip et al. (2), include cases of obstructed chambers and canals, material pushed beyond the apex with accompanying symptoms, persistent periapical inflammation despite endodontic treatment, and some cases of perforation.

The presence of extensive periapical odontogenic granulomas is a significant problem for both the patient and the attending physician. Lesions of this type are not part of everyday general dental practice. In Poland, general dental practitioners, when presented with a case outside their abilities, refer patients to specialist clinics, which are able to provide proper care. The Department of Endodontics is one of the reference units when it comes to dealing with complex endodontic cases.

The purpose of this report is to describe a microsurgical apicoectomy procedure and discuss the possible therapeutic outcomes. The procedure mostly follows the concept described by Kim, (4), Kim and Kratchman (5).

## Case Report

This case report has been written according to Preferred Reporting Items for Case Reports in Endodontics (PRICE) 2020 guidelines (Checklist 1 and Flowchart 1). The pa-

tient signed an informed consent and was able to ask questions about the procedure beforehand.

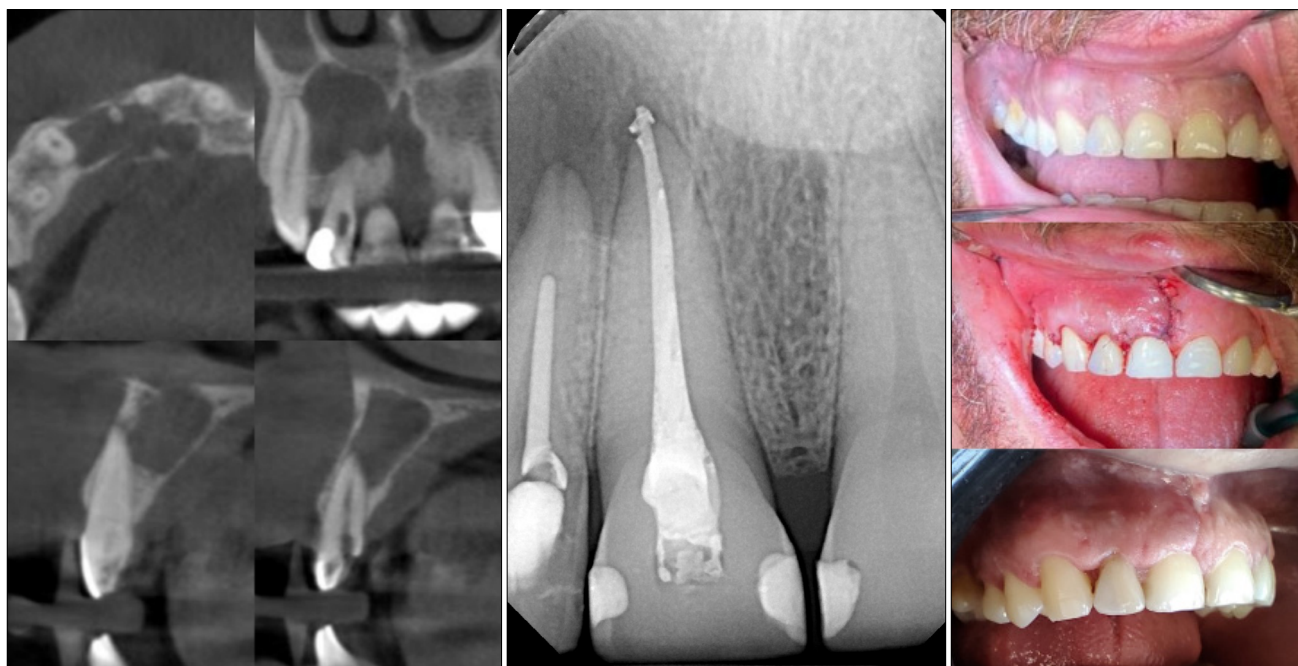
A 45-year-old Caucasian male patient with no significant medical history reported to the clinic in the Department of Endodontics, Chair of Conservative Dentistry and Endodontics at Medical University in Lodz. The patient was not complaining of any pain. During a standard dental investigation, a history of dental trauma was revealed. The patient reported a car accident more than 10 years ago, during which a facial injury occurred.

A large radiolucent area, suggesting bone resorption, with an irregular contour was found during a regular check-up on an ortopantomographic X-ray. Cone beam tomography was ordered (Fig. 1) to precisely measure the size of the bone cavity and evaluate which of the teeth's apices were encompassed by the lesion. The lesion was located in the region of teeth 11–13 (upper right central incisor to upper right canine). The exact location evaluated by cone beam computed tomography showed that apices 11 and 12 were encompassed by the lesion, together with the mid-root section of tooth 13. The apex of the canine was not surrounded by the lesion.

The clinical examination revealed a hard bulge at the palatal side of the incisors. The thickening was not tender on palpation, and there was no swelling of the area. Maxillary right central and lateral incisors were tender on percussion and non-responsive to sensibility testing (neither cold or electric pulp test). The canine was reacting properly to the tests performed and did not show tenderness on percussion.

Single-visit root canal treatment of tooth 11 was carried out before surgery, with single-tooth rubber dam isolation. Mechanical preparation was carried out with DC TaperH (SS White Dental, Lakewood, New Jersey, USA) until size 40.06. The irrigation protocol included rinsing with 2 mL of 5.25% sodium hypochlorite between each file, as well as final irrigation with 20 mL of 5.25% sodium hypochlorite and 5 mL of 40% citric acid. Ultrasonic and manual activation were used during the whole treatment. Filling was performed with the lateral condensation technique of cold gutta-percha with AH Plus sealer (Dentsply, North Carolina, USA) (Fig. 2).

Treatment of tooth 12 was performed without a permanent seal due to exudation. Abundant yellowish-gold discharge was present, impossible to dry out despite copious irrigation with hypochlorite and vigorous suction. A non-hardening calcium hydroxide dressing (Calcipast [Cerkamed, Stalowa Wola, Poland]) was placed inside the canal system. A gutta-percha cone was positioned, with a tug-back effect, in the canal for a length 6 mm shorter than the working length to provide support for the retrofilling material.



**Fig. 1.** Lesion visible in cone beam tomography.

**Fig. 2.** The root canal treatment of tooth 11.

**Fig. 3.** The state of oral mucosa before, after suturing and healing after 2 weeks.

After surgery, an endodontic treatment was completed, with irrigation with sodium hypochlorite 5.25%, citric acid 40%, ultrasonic and sonic activation, and filling with warm gutta-percha with AH Plus sealer.

Both teeth were rebuilt using a light-cured composite material (Omnichroma [Marrodent, Bielsko-Biała, Poland]), with a standard adhesive procedure.

Surgery was carried out with local infiltration anesthesia. Three 1.7 mL doses of Articaini hydrochloridum and Adrenaline (40 mg + 0.01 mg)/mL were used. Proper conditions for the procedure were obtained after waiting for 15 min after providing anesthesia before performing the first incision. The hemostasis was sufficient, and it was not necessary to obtain additional clotting with products containing ferric sulfate.

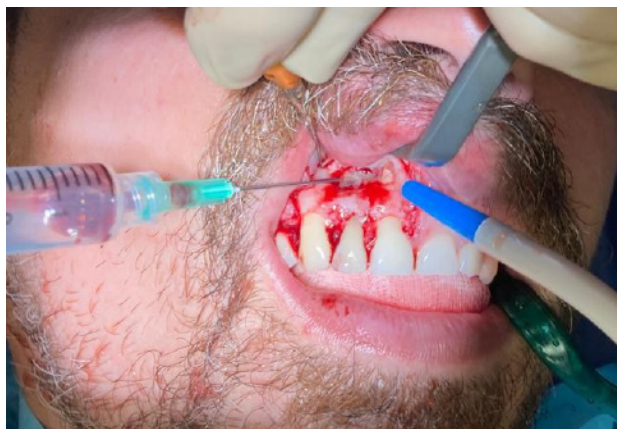A sulcular full-thickness flap was designed from tooth 14, with a vertical releasing incision in the frenulum. According to the current guidelines, the base of the flap should be as wide as the top crest, and the vertical incisions should shadow the vertical blood vessel alignment. This facilitates nearly scar-free healing while still providing more than adequate access to the surgical site (Fig. 3). Subsequently, bone was removed in the areas of teeth 11 and 12 using a surgical bur.

To facilitate full removal, the sac was gently separated from the walls of the cavity with the blunt side of a bone spoon, and the fluid was drained from the cyst with a syringe and

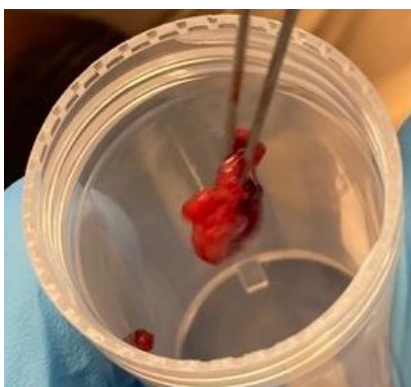a needle (Fig. 4). After the evacuation of fluid, the lesion was removed in one piece (Figs. 5 and 6). Any presence of debris was microscopically inspected, and the bone crypt was vigorously curettaged. The surgical field was irrigated with saline.

A 3 mm of the root apices of teeth 11 and 12 were cut using a Lindeman surgical bur and a 0° bevel angle of the root surface was accomplished (Fig. 7). The cut surface was checked with methylene blue for fractures, additional canals, and an isthmus. The canals were prepared with ultrasonic diamond-coated retro-tip KiS-1D (Obtura Spartan/Young Specialties, Algonquinn, IL, USA).

The retrograde filling was performed with Total Fill BC



**Fig. 4.** Drainage of the fluid from the cyst with syringe and needle.



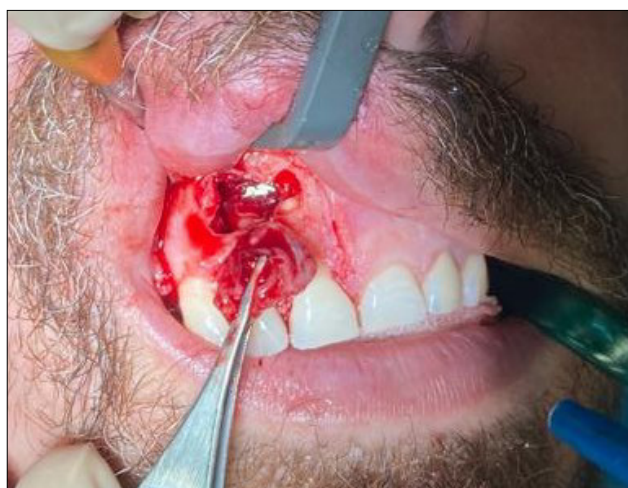**Fig. 5.** The lesion was prepared for histopathological examination.

Putty (FKG Dentaire Sarl, Le Cret-du-Loche, Switzerland). The material is premixed cement in the form of a pleasant, susceptible to molding mass, ready to use straight from a syringe or jar (Figs. 8 and 9). According to the authors, this product is operator-friendly, its consistency is easier to handle than MTA material (powder + liquid), and the lack of necessity for mixing reduces the time required for retrofilling.

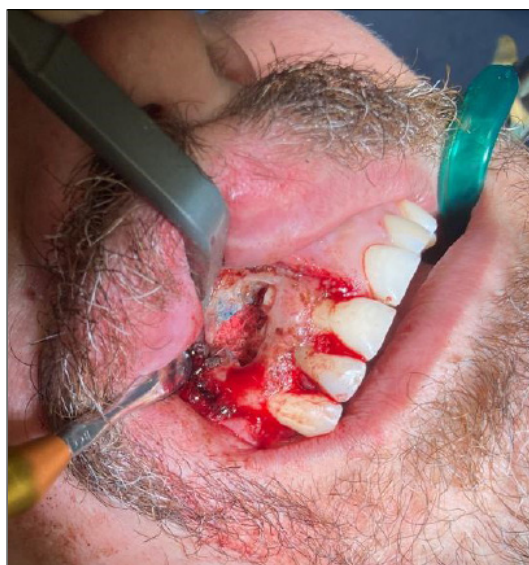The flap was repositioned and sutured in place with 5-0 nylon monofilament, with the control of a microscope. After suturing, a moist gauze compress was applied with a light pressure to the soft tissues to provide better adaptation of incision margins, eliminate blood clots, and assure proper alignment of the flap.

The procedure was performed within the so-called “golden hour.” A short operating time minimizes soft tissue trauma and has a positive effect on the success rate of the procedure (4,5). We achieved a distinctly favorable outcome with soft tissues.

Postoperative medications and instructions were prescribed



**Fig. 6.** The lesion was evacuated in one piece.

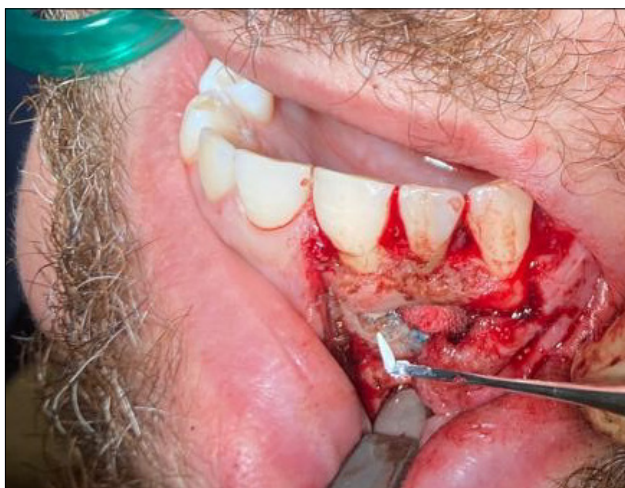

**Fig. 7.** A 3 mm of the root apices of teeth 11 and 12 was cut using Lindeman surgical bur.

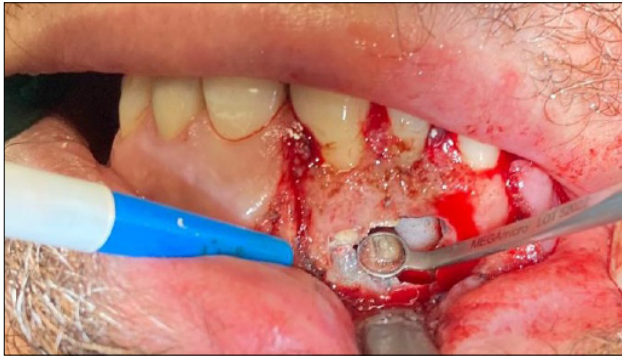
to the patient along with a 0.12% chlorhexidine mouth rinse for maintenance of oral hygiene. The patient was recalled after 5 days for the removal of sutures and evaluation of the treatment.

The outcome was comprehensively evaluated based on clinical and radiographic examinations. Pain on pressure, presence of inflammation or fistula, tooth mobility, and pain on percussion were checked during the control visit. The patient was asymptomatic; he did not report swelling or pain after the surgery (Fig. 10).

The material collected from the lesion was subjected to histopathological examination. The result was an odontogenic keratocyst (OKC). The patient was informed of the diagnosis and made aware of the necessity for regular



**Fig. 8.** The retrograde filling.



**Fig. 9.** The retrograde filling in tooth.

check-up visits due to the tendency for reoccurrence of this type of lesions.

The patient reported a first control visit five months after surgery. Periapical X-rays revealed a decrease in the size of the lesion (Fig. 11). The patient was asymptomatic. Further appointments for check-ups were scheduled.

## Discussion

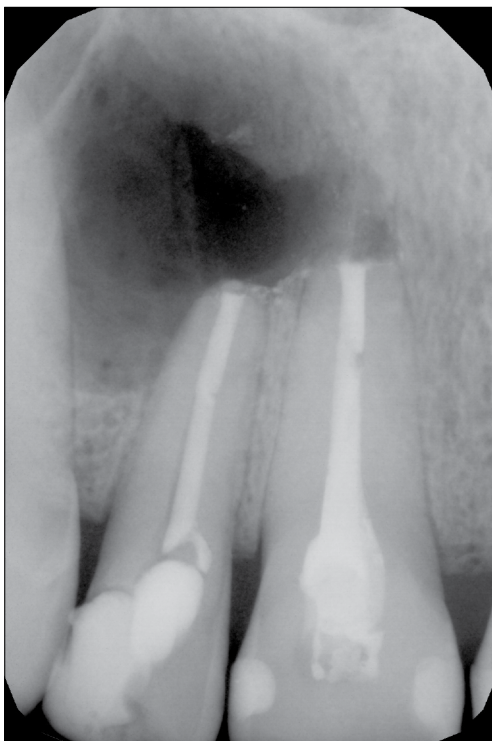
Various factors, including dental caries or trauma, can cause inflammation of the pulp and pulp necrosis as a result. The bacterial infection then spreads into the canal system to the apex of the root and into the periapical tissues, causing periapical periodontitis, which leads to either an acute abscess or a chronic granuloma when left

untreated. Persistent chronic infection can proceed into formation of a periapical cyst (1, 6). In the presented case, the patient had confessed to a history of traumatic injuries. Radicular cysts are the most common cystic lesions that affect the jaw. They make up about 52–68% of all the cysts that affect the human jaw (6). They are most commonly found at the apices of the infected teeth or in relation to lateral accessory root canals. They are symptomless and usually diagnosed during routine radiographic investigations. A radiographically radicular cyst appears as an oval or pear-shaped unilocular radiolucency in the periapical region (7). Some can cause pain and/or discomfort when infected or due to nerve compression if they become large enough. After trauma, a frequent symptom is discoloration of the affected tooth (1, 7).

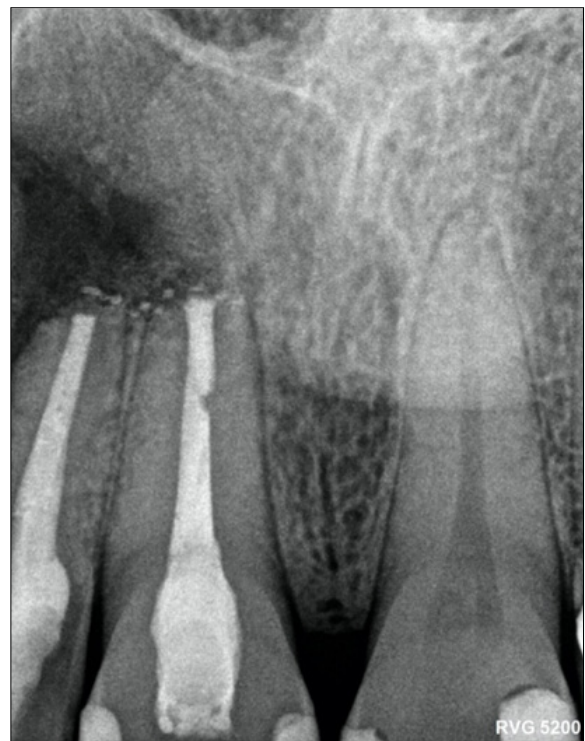
OKC is a benign tumor derived from the remains of the original tooth germ, or dental lamina. Unlike most other jaw cysts, it has a very high recurrence rate and a tendency to become cancerous.

OKC can occur in any location of the jaw, but a cyst in the mandible occurs much more frequently than in the maxilla (3:1). The lesion shows a slight male predilection, usually occurring in young adult patients (30–50 years).

There are generally no obvious warning symptoms with early-stage OKC, as even if the lesion is large, it still does not cause evident jaw expansion, making it unnoticeable by standard clinical examination procedures such



**Fig. 10.** The control X-ray after procedure.



**Fig. 11.** The control X-ray after 5 months.

as inspection and palpation. Occasionally, patients present symptoms such as swelling, pain, abnormal sensation, pus outflow, and increased mobility of adjacent teeth (8). Among these, swelling is the most common clinical manifestation of OKC. If an OKC continues to grow, the bone gradually expands around it, and facial deformity will occur. If OKC is in close proximity to the teeth, progressive expansion can cause the adjacent teeth to become compressed, resulting in changes in location, position, increased mobility, or even tooth loss.

The presence of OKC can be suspected after performing a proper clinical examination and gathering a meticulous medical history. Diagnostic biopsy is a quite reliable additional diagnostic examination method. Yellow and white keratin-like (sebum-like) substances can be seen on the site in most cases. Keratin staining of the extracted material will further validate the diagnosis of OKC. An X-ray examination is also extremely useful for the diagnosis. A radiograph will usually show a clear, round or oval, transparent shadow with well-defined edges. This is, however, typical for all types of cysts, and so the final diagnosis is possible only after results from the histopathological report (9,10).

In the anterior maxillary region, OKC is rare. The patient described in the article had no previous medical history of similar cysts. Also, the radiological imaging did not indicate any distinction from a true cyst. Due to the bone expansion around the lesion, there was no possibility of performing a diagnostic biopsy before surgery without drilling through a bone. Because of those reasons, the operators performed surgery without indication that the lesion would turn out to be OKC. However, the surgery was performed with caution, and the cyst was first carefully separated from the cavity's walls and then drained. This technique facilitates the removal of the sac in one piece. Complete removal of the cyst's envelope is one of the main factors enhancing the chances of no relapses. Since OKC has a relatively high recurrence rate, it is especially important to remove the whole sac. In this case, the sac was not ripped during the surgery, which gives us quite good prospects for healing without recurrence or reappearance.

For infected teeth with an ongoing inflammatory process, nonsurgical root canal treatment is always the first-line approach to remove the contamination (11). Therefore, in the presented clinical case, nonsurgical root canal treatment was performed to contain the infection in tooth 11. Due to the massive, golden-yellow exudation from the canal of tooth 12 and the size of the lesion, it was decided to proceed immediately with periapical surgery, with the main objective of removing the disease of periapical tis-

ues as well as sealing the apical root canal system with biocompatible material.

The main cause of apical periodontitis is a microbial infection in the canal system. A successful outcome of root canal treatment is highly dependent on the elimination of persistent infection and the prevention of reinfection of the root canal system. Therefore, it is very important to seal the canal system that remains after the resection (3,5,12).

Apicoectomy with retrograde filling is an efficient treatment method (2,3,5,11-13). Lesions around the roots can be reliably removed with surgical access. The operator should visually inspect the resected root canal surface with the use of a dental operating microscope after dyeing with Methylene Blue. Root fractures, lateral canals, and isthmuses can be identified with this technique, and the root canal system can be completely sealed or disqualified from further treatment. The apical 3 mm of the root contains 98% of apical ramifications and 93% of lateral branches. Therefore, most endodontists agree that the last 3 mm of the root should be removed during microsurgery. According to current guidelines, cutting perpendicular to the longitudinal axis of the root is recommended to minimize the number of exposed dental tubules.

The aim of the root-end retro preparation is to create a 3 mm cylindrical cavity, free of bacteria, intracanal material, and other irritants, that can be subsequently filled. Kim and Kratchman (5) define the ideal root-end preparation as a class 1 cavity, at least 3 mm into root dentine, with walls parallel to and corresponding to the anatomic outline of the root canal space.

The use of retrotips allows for precise preparation of the canal and isthmus, thus reducing the risk of perforation. There is no possibility of performing apical microsurgery properly without the use of a microscope. Only a dental operating microscope provides the light and magnification necessary to precisely visualize the anatomical details of the resected root surface. Performing a resection without a surgical microscope should be a procedure of the past, without justification in modern dentistry (3-5).

Endodontic microsurgery is a safe and adequate alternative when teeth are not responding to primary or secondary endodontic treatment (1,3,5,14). Bacteria adhere to damaged tissue in a hydrated matrix of polysaccharide and protein, forming a biofilm. Noiri et al. (15) suggested that bacterial biofilms formed in the extra-radicular areas were related to persistent periapical periodontitis. Bacteria in the biofilm are 10–1000 times more antibiotic-resistant than airborne bacteria (16). Biofilms on an external root surface are impossible to remove with conventional endodontic treatment, requiring patients to undergo end-

**Table 1.** Classification of clinical cases in microsurgical apicoectomy according to Kim and Kratchman (5)

Class A	Represents the absence of a periapical lesion, no mobility and normal pocket depth, but unresolved symptoms after nonsurgical approaches have been exhausted. Clinical symptoms are the only reason for the surgery.
Class B	Represents the presence of a small periapical lesion together with clinical symptoms. The tooth has normal periodontal probing depth and no mobility. The teeth in this class are ideal candidates for microsurgery
Class C	Teeth have a large periapical lesion progressing coronally but without periodontal pocket and mobility.
Class D	Clinically similar to those in class C, but have deep periodontal pockets.
Class E	Teeth have a deep periapical lesion with an endodontic periodontal communication to the apex but no obvious fracture
Class F	Represents a tooth with an apical lesion and complete denudement of the buccal plate but no mobility.

odontic surgery to achieve healing and full functional recovery (3,14).

Endodontic surgery is a widely studied procedure. According to the meta-analysis of Tsesis et al., (17) the success rate of endodontic surgery is 91.6%, while the failure rate is 4.7%. However, its prognosis is influenced by several factors, such as different surgical procedures and materials, systemic conditions, local factors such as involved teeth and their anatomy, conventional treatment or previous root canal retreatment, and restoration quality. It is therefore of clinical relevance to perform a thorough clinical and radiographic examination of the tooth before apical surgery (including adjacent and opposing teeth) (4,12). Special care should be placed upon the pocket examination since teeth referred for apical surgery due to chronic inflammation shouldn't be compromised periodontally. Also, a deepening of the pocket, limited to one spot around the tooth, may indicate a vertical fracture and needs to be inspected thoroughly.

Endodontic microsurgery is a predictable procedure that eliminates the unfavorable elements of traditional surgical approaches (5). Complete, precise surgical cyst removal and management of root canal infection from causative teeth is the basic strategy, even for extensive lesions.

According to Kim and Kratchman's (5) classification of clinical cases, our patient was in Class C, where teeth have a large periapical lesion progressing coronal but without periodontal pocket and mobility (Table 1). These types of microsurgical cases have a positive success rate and are predictable. A study by Rubinstein and Kim (18) shows a 96.8% healing rate after 1 year in this category.

Cyst treatment depends on the location of the lesion and the proximity of other anatomical structures such as the mental foramen, palatine, or nerve canal. Proper planning of the surgical approach should be based on modern diagnostics. In such cases, it is advisable to use computed tomography (3). Also, in cases of excessive bone loss, it is worth to consider a procedure of decompression before surgery. It can be a good solution, especially if the lesion is in the area of important neurological structures (19).

Preserving patients' natural dentition should be our primary goal whenever possible. Endodontic microsurgery with state-of-the-art equipment, instruments, and materials that match biological concepts is predictable and recommended (5). Dentists should expand the scope of their surgical skills or be aware of the possibility of performing a root apex resection in order to offer their patients the most modern services.

**Authorship Contributions:** Concept: J.K.S.; Design: J.K.S., K.F. Supervision: K.F.; Materials: J.K.S., K.F.; Data: D.H.; Analysis: J.K.S, K.F.; Literature search: J.K.S.; Writing: J.K.S.; Critical revision: K.F.

**Source of Funding:** None declared.

**Conflict of Interest:** None declared.

**Informed consent:** Written informed consent was obtained from patients who participated in this study.

## References

1. Chauhan D, Thakur S, Slingh D. Management of teeth with trauma induced crown fractures and large periapical lesions following apical surgery (Apicoectomy) with retrograde filling. *Int J Appl Dent Sci* 2021; 7: 309–13. [\[CrossRef\]](#)
2. Velip C, Agarawal M, Goel D, Binawara KK. Surgical endodontic management of non healing periapical lesion – case report. *IOSR J Dent Med Sci* 2021; 20: 42–5.
3. Setzer FC, Kratchman SI. Present status and future directions: surgical endodontics. *Int Endod J* 2022; 55 Suppl 4: 1020–58. [\[CrossRef\]](#)
4. Kim S. Principles of endodontic microsurgery. *Dent Clin North Am* 1997; 41: 481–97. [\[CrossRef\]](#)
5. Kim S, Kratchman S. Modern endodontic surgery concepts and practice: a review. *J Endod* 2006; 32: 601–23.
6. Kadam NS, Ataide Ide N, Raghava P, et al. Management of large radicular cyst by conservative surgical approach: a case report. *J Clin Diagn Res* 2014; 8: 239–41. [\[CrossRef\]](#)
7. Vijay P, Singhal I, Singh N, et al. Radicular cyst and its management: a case report. *Int J Dent Med Res* 2015; 1: 80–1.
8. Hadziabdic N, Dzinovic E, Udovicic-Gagula D, et al. Non-

- syndromic examples of odontogenic keratocysts: presentation of interesting cases with a literature review. *Case Rep Dent* 2019; 2019: 9498202. [\[CrossRef\]](#)
9. From the Department of Pathology, Woodland Hills Medical Center, Southern California, Permanente Medical Group, Woodland Hills, Calif. Thompson LD. Keratocystic odontogenic tumor. *Ear Nose Throat J* 2014; 93: 386–8. [\[CrossRef\]](#)
  10. Chen P, Liu B, Wei B, et al. The clinicopathological features and treatments of odontogenic keratocysts. *Am J Cancer Res* 2022; 12: 3479–85.
  11. Ogawa M, Yokoo S, Koitabashi A, et al. A clinical study of endodontic microsurgery for extensive radicular cysts. *Int J Microdent* 2013; 4: 98–105.
  12. Chowdhury D, Samanta S, Das A, et al. Management of a large periapical pathology in maxillary anterior region with mineraltrioxideaggregate using retrograde filling technique- a case report. *Int J Innovat Res Dent Sci* 2018; 3: 361–70.
  13. Villarreal-Arango D, Ramos-Manotas J, Díaz-Caballero A. Apicoectomy and retrograde filling as periapical granuloma treatment: a case report. *Rev Fac Odontol Univ Antioq* 2016; 28: 203–9. [\[CrossRef\]](#)
  14. Khan A, Aziz H, Zaman H. Indication for surgical endodontics in accordance with Nice guidelines. *Int Dent J Stud Res* 2016; 4: 45–8.
  15. Noiri Y, Ehara A, Kawahara T, et al. Participation of bacterial biofilms in refractory and chronic periapical periodontitis. *J Endod* 2002; 28: 679–83. [\[CrossRef\]](#)
  16. Stewart PS, Costerton JW. Antibiotic resistance of bacteria in biofilms. *Lancet* 2001; 358: 135–8. [\[CrossRef\]](#)
  17. Tsesis I, Faivishevsky V, Kfir A, et al. Outcome of surgical endodontic treatment performed by a modern technique: a meta-analysis of literature. *J Endod* 2009; 35: 1505–11.
  18. Rubinstein RA, Kim S. Short-term observation of the results of endodontic surgery with the use of a surgical operation microscope and super-EBA as root-end filling material. *J Endod* 1999; 25: 43–8. [\[CrossRef\]](#)
  19. Torres-Lagares D, Segura Egea JJ, Rodríguez-Caballero Á, et al. Treatment of a large maxillary cyst with marsupialisation, decompression, surgical endodontic therapy and enucleation. *J Can Dent Assoc* 2011; 77: b87.