



Management of avulsed and severely intruded teeth in a patient

 Ayşegül Arkan İlik,  Cangül Keskin

Department of Endodontics, Ondokuz Mayıs University Faculty of Dentistry, Samsun, Türkiye

This case report describes the treatment of avulsion and intrusion trauma of the upper left incisors in a 21-year-old female patient. The avulsed tooth was stored in dry conditions for 48 h since the accident happened. Teeth were treated according to the trauma protocol recommended for avulsed and intruded teeth. During the 1-year follow-up period, absence of mobility, root resorption, or any symptoms were observed in the clinical and radiological examination.

Keywords: Avulsion, delayed replantation, dental injuries, intrusion.

Introduction

Dental injury is (DI) widespread. Nearly 30% of people worldwide experienced a DI during their lifetime (1). DI mainly involves the maxillary anterior teeth (2). Visibility of maxillary incisors, overjet, and interlabial gaps are considered predisposing factors associated with incisors' injury (3). The total displacement of the tooth out of its socket is described as avulsion and considered one of the most severe dental injuries (4). Avulsion in permanent dentition constitutes 0.5%–16% of all DIs (5,6). The prognosis depends on the time of replantation at the place of the accident or promptly after the avulsion (4). The optimal treatment is replantation of the avulsed tooth as immediately as possible (7). If the time out of the socket exceeds more than 30 min, all periodontal ligament cells become nonviable due to suffering from dehydration in severe cases (8–10). Therefore, it is important to learn the exact time of avulsion and storage conditions of the avulsed tooth before replantation to estimate a possible prognosis scenario and inform the patient (11). Despite the immediate replantation being currently the best option, replanted

avulsed teeth could present complications after following root canal treatment as development of infection-related (inflammatory) resorption and ankylosis-related (replacement) resorption.

The displacement of a tooth farther into the alveolar socket is described as intrusive luxation and occurs in 3% of all traumatic dental injuries in permanent dentition (12). The injury is severe because the pulp and periodontal ligament become extremely damaged. Thus, intruded tooth healing is complex and difficult (6). Inflammatory root resorption, pulp necrosis, loss of marginal bone support, gingival retraction, calcification of the pulp tissue, paralysis or disturbance of root development, and dentoalveolar ankylosis may occur as complications of intrusive luxation (13,14). For intruded teeth, different treatment procedures have been prepared by the International Association of Dental Traumatology (IADT) (15). Spontaneous re-eruption, surgical repositioning, orthodontic extrusion, and the combination of surgical repositioning and orthodontic extrusion are acceptable treatment options for intruded teeth (16,17). But the ideal treatment method

Cite this article as: Arkan İlik A, Keskin C. Management of avulsed and severely intruded teeth in a patient. Turk Endod J 2022;7:00-00.

Correspondence: Ayşegül Arkan İlik. Department of Endodontics, Ondokuz Mayıs University Faculty of Dentistry, Samsun, Türkiye

Tel: +90 554 – 671 03 44 e-mail: aysegularkan95@gmail.com

Submitted: April 14, 2022 Revised: July 18, 2022 Accepted: August 05, 2022

©2022 Turkish Endodontic Society



for an intruded tooth is not specified in the literature, and treatment procedures are usually conflicting (18).

In this study, a case of multiple dental trauma on the left upper incisors of a young female adult is reported. Considering the poor prognosis, this study describes the treatment planning of avulsed and intruded upper left incisors 48 h after the accident. This study aimed to highlight the importance of prompt treatment and management of oral trauma protocols.

Case Report

A systemically healthy 21-year-old female patient was referred to the endodontic department of Ondokuz Mayıs University clinic to treat a traumatically avulsed upper left central incisor after the accident. The patient went to the hospital's medical emergency services and antibiotics were given, but the avulsed tooth was not repositioned. After the clinical and radiological examination, it was found that the soft tissues were damaged, the maxillary left central incisor was avulsed, and the upper left lateral incisor was intruded (Fig. 1).

After the patient was informed about the treatment plans, the root surface of the upper left central incisor was cleaned, rinsed with sterile saline solution, and stored in sodium fluoride for 5 min. The tooth socket was rinsed with sterile saline solution, the upper left central tooth was reimplanted, and the upper left lateral tooth was repositioned. A semiflexible splint was made using orthodontic wire and composite resin for traumatized teeth. Endodontic access cavities were opened on the teeth, and root canal treatments were started (Fig. 2).

After determining the working length of the canals with the apex locator, the root canal system was chemomechanically instrumented using ProTaper Next (Dentsply Sirona, Ballaigues, Switzerland) rotary file systems. Root canals during preparation were irrigated with 5.25% sodium hypochlorite followed by 17% liquid ethylenediaminetetraacetic acid.

After the preparation, calcium hydroxide ($\text{Ca}(\text{OH})_2$), as an intracanal medicament, was placed and the patient was scheduled for control 2 weeks later. In the next appointment, the splint was removed and gutta-percha and

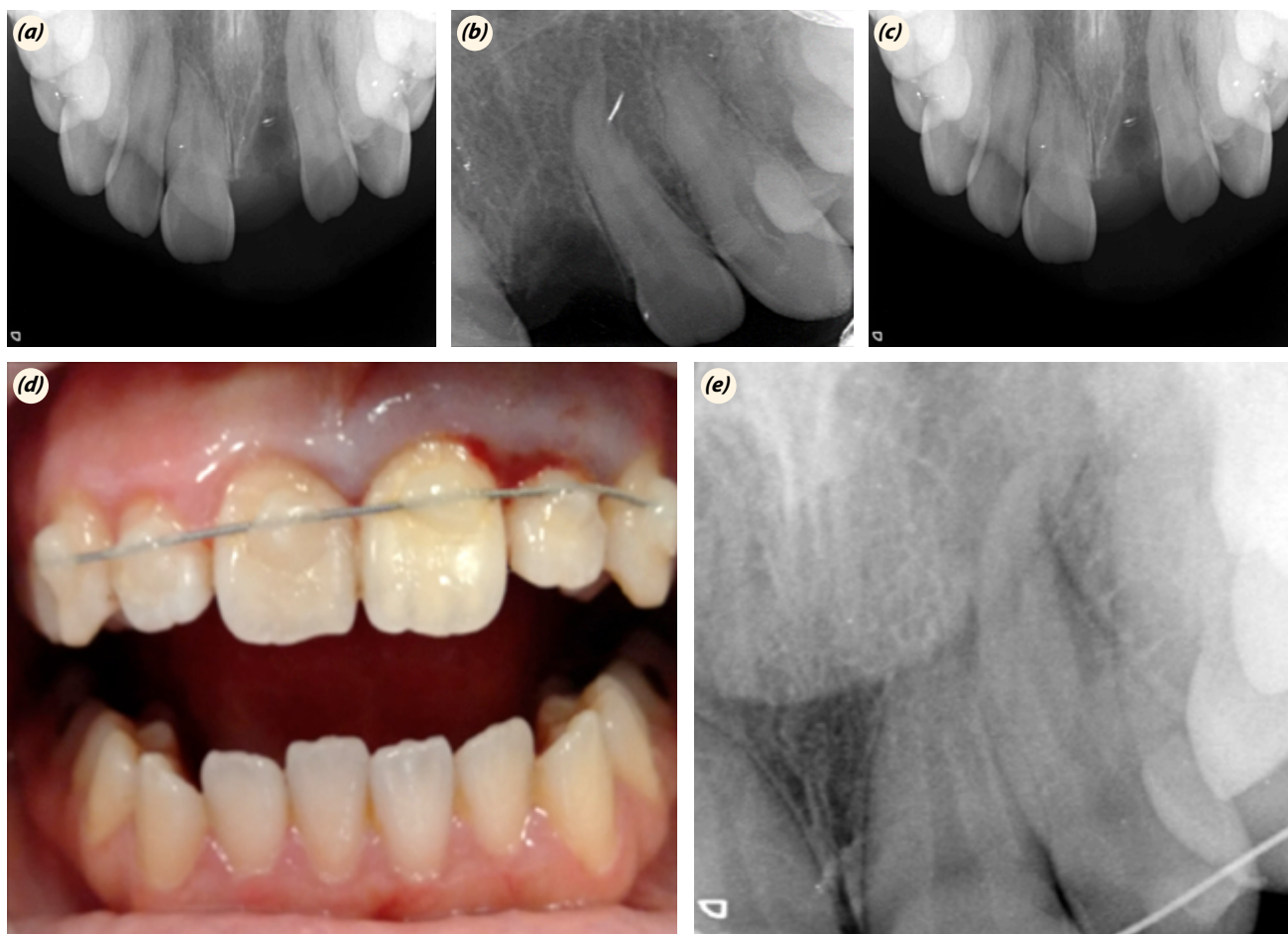


Fig. 1. Intraoral image taken after the accident in our clinic (a). Occlusal and periapical radiograph taken after 48 h of the accident: avulsed maxillary left incisor and intruded maxillary left lateral incisor (b, c). Periapical radiograph and clinical view of maxillary left incisors (d, e).

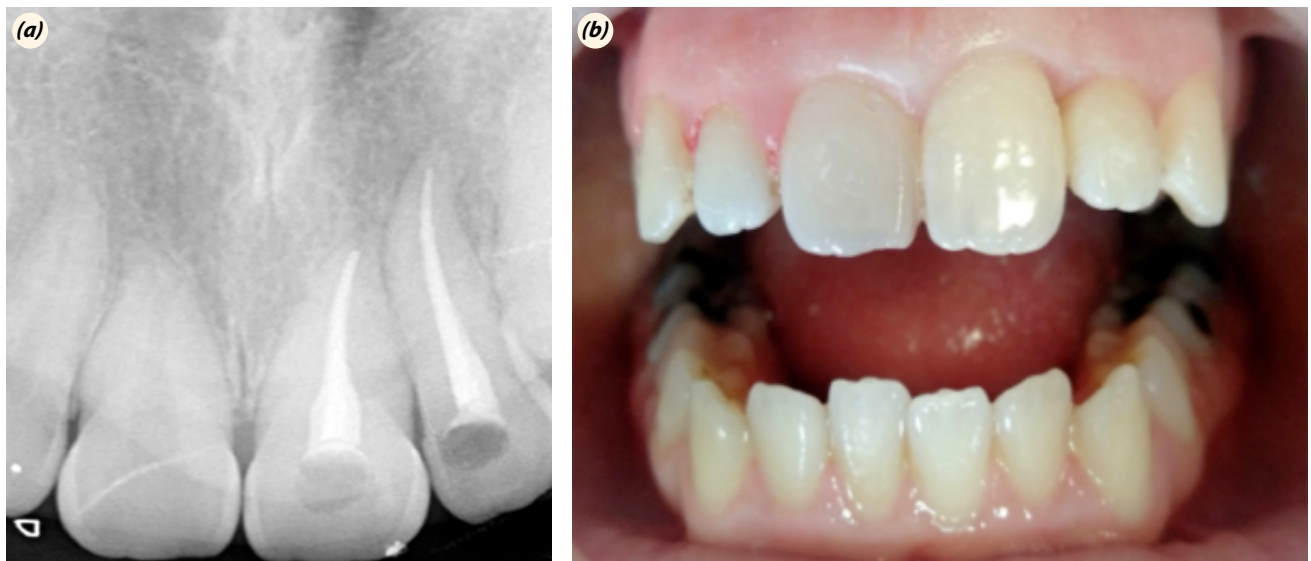


Fig. 2. Periapical radiograph demonstrating root canal treatment (a). Clinic view of maxillary left incisor two week later (b).

resin-based root canal paste (Adseal, Meta Biomed, South Korea) were applied. The root canal system was filled with the cold lateral compaction method. The permanent restoration of the teeth was completed using composite resin with dentin adhesive.

Discussion

A traumatically avulsed incisor is challenging for a clinician. This case report shows the importance of replantation of the traumatized teeth although cases such as this one has a poor prognosis. For avulsed teeth, the optimum treatment option is immediate replantation because periodontal ligament cells are protected and the probability of root resorption is decreased (6,9,19). Although an avulsed tooth may not be promptly replanted, the tooth must be kept in a storage medium such as milk, saline, water, saliva, or HBSS (20,21). Except for saliva, other storage solutions may not be found easily at the accident site. Although saliva has features such as nonsterile and low osmolarity, it prevents tooth suffering from dehydration until a more suitable storage medium is obtained (22). After period out of socket exceeds 60 min, all PDL cells become nonviable and the healing chances are less (8). In the present case, the tooth was kept in dry storage until reimplantation, and the avulsed tooth was replanted after 48 h. Although this case report had unfavorable storage conditions and more time elapsed after the event, traumatized teeth were successfully healed.

Splinting is important to providing patient comfort, keeping traumatized teeth in a suitable position in the socket and improving function (23–25). Studies have shown that the structure of the tissue and pulp recovery are positively

influenced, and root resorption is reduced if the replanted tooth is prevented from excess mobility and function (26,27). It was found in animal studies that injured PDL cells regained most of their mechanical properties 2 weeks after trauma (28). Therefore, traumatized teeth were splinted to adjacent teeth with composite resin and semi-rigid wire for 2 weeks.

In cases of avulsed teeth, the various agents used may slow down the resorption process (29–31). Fluoride is applied to the root surface of avulsed teeth to reduce root resorption and ensure optimal healing (32). The IADT recommended treating the root surface using 2.4% sodium fluoride for 5 min (33). In this case report, the root surfaces of avulsed teeth were replanted after treatment with 2.4% sodium fluoride for 5 min.

Antibiotics are recommended after dental injuries, particularly avulsion injuries, to reduce the probability of infection-related reactions and the incidence of root resorption (34,35). The efficacy of tetracycline administered after replantation and avulsion injury has been demonstrated in animal studies (35). However, the administration of tetracycline may cause discoloration in patients under 12 years of age. Due to the adverse effect of tetracycline, its administration in young patients is not recommended (36). In this case, a minocycline antibiotic was used because the patient was over 12 years of age.

The IADT recommended that if mature teeth intruded 3–7 mm, the treatment choice is surgical (preferably) or orthodontic (37). Some authors have reported that surgical positioning may be preferred for the treatment option of intruded teeth (38,39). However, according to Andreasen, orthodontic repositioning treatment of intruded

luxation is better than surgical repositioning because the possibility of undesirable postoperative complications such as ankylosis, external root resorption, and loss of marginal bone increases due to surgical repositioning (40). Despite the possibility of these complications, Cunha et al. (41) reported in animal studies that rapid replantation shows good healing in permanent teeth with completed root development. However, it has been reported that these complications also occur in cases with orthodontic positioning (42). Patient cooperation is an important factor, as treating intrusive teeth with orthodontic positioning needs a long time. In the present case, surgical repositioning was the treatment of choice to accelerate treatment.

If intrusive luxation occurs in mature teeth, the pulp commonly becomes necrotic. Therefore, endodontic treatment of intruded teeth should begin immediately, and intracanal medicaments such as $\text{Ca}(\text{OH})_2$ should be used (37). The aim of using intracanal medicaments is to reduce complications such as inflammatory external root resorption (37,43). The IADT recommended $\text{Ca}(\text{OH})_2$ paste as an intracanal medicament until 1 month in the avulsion cases (11). Therefore, in this case report, $\text{Ca}(\text{OH})_2$ paste was used as a dressing in the left incisors.

Although no radiological or clinical abnormality was observed in the follow-up period, it should be kept in mind that these complications may occur in the long term. Therefore, long-term follow-up periods are needed in these cases.

Conclusions

Treatment protocols applied in avulsion and intrusion injuries are important in terms of prognosis. For this reason, dentists should follow up-to-date treatment protocols.

Authorship Contributions: Concept: A.A.İ.; Design: A.A.İ.; Supervision: A.A.İ.; Materials: A.A.İ.; Data: A.A.İ.; Analysis: A.A.İ.; Literature search: A.A.İ.; Writing: A.A.İ., C.K.; Critical revision: A.A.İ., C.K.;

Source of Funding: None declared.

Conflict of Interest: None declared.

Informed consent: Written informed consent was obtained from patient who participated in this study.

References

- Moule A, Cohenca N. Emergency assessment and treatment planning for traumatic dental injuries. *Aust Dent J* 2016; 61 Suppl 1: 21–38. [CrossRef]
- Zaleckiene V, Peciuliene V, Brukiene V, Drukteinis S. Traumatic dental injuries: etiology, prevalence and possible outcomes. *Stomatologija* 2014; 16: 7–14.
- Kania MJ, Keeling SD, McGorray SP, Wheeler TT, King GJ. Risk factors associated with incisor injury in elementary school children. *Angle Orthod* 1996; 66: 423–32.
- Kargul B, Welbury R. An audit of the time to initial treatment in avulsion injuries. *Dent Traumatol* 2009; 25: 123–5. [CrossRef]
- Glendor U, Halling A, Andersson L, Eilert-Petersson E. Incidence of traumatic tooth injuries in children and adolescents in the county of Västmanland, Sweden. *Swed Dent J* 1996; 20: 15–28.
- Andreasen JO, Andreasen FM, Andersson L. Textbook and color atlas of traumatic injuries to the teeth. Hoboken: John Wiley & Sons; 2018. [CrossRef]
- Day PF, Duggal M, Nazzal H. Interventions for treating traumatised permanent front teeth: avulsed (knocked out) and replanted. *Cochrane Database Syst Rev* 2019; 2: CD006542. [CrossRef]
- Andersson L, Andreasen JO, Day P, et al. International Association of Dental Traumatology guidelines for the management of traumatic dental injuries: 2. Avulsion of permanent teeth. *Dent Traumatol* 2012; 28: 88–96. [CrossRef]
- Andreasen JO. Effect of extra-alveolar period and storage media upon periodontal and pulpal healing after replantation of mature permanent incisors in monkeys. *Int J Oral Surg* 1981; 10: 43–53. [CrossRef]
- Barbizam JV, Massarwa R, da Silva LA, et al. Histopathological evaluation of the effects of variable extraoral dry times and enamel matrix proteins (enamel matrix derivatives) application on replanted dogs' teeth. *Dent Traumatol* 2015; 31: 29–34. [CrossRef]
- Fouad AF, Abbott PV, Tsilingaridis G, et al. International Association of Dental Traumatology guidelines for the management of traumatic dental injuries: 2. Avulsion of permanent teeth. *Dent Traumatol* 2020; 36: 331–42. [CrossRef]
- Andreasen JO. Etiology and pathogenesis of traumatic dental injuries. A clinical study of 1,298 cases. *Scand J Dent Res* 1970; 78: 329–42. [CrossRef]
- Sapir S, Mamber E, Slutzky-Goldberg I, Fuks AB. A novel multidisciplinary approach for the treatment of an intruded immature permanent incisor. *Pediatr Dent* 2004; 26: 421–5.
- Andreasen JO, Andreasen FM. Essentials of traumatic injuries to the teeth: a step-by-step treatment guide. John Wiley & Sons; 2010. [CrossRef]
- Umesan UK, Chua KL, Kok EC. Delayed orthodontic extrusion of a traumatically intruded immature upper permanent incisor - a case report. *Dent Traumatol* 2014; 30: 406–10. [CrossRef]
- Andreasen JO, Bakland LK, Matras RC, Andreasen FM. Traumatic intrusion of permanent teeth. Part 1. An epidemiological study of 216 intruded permanent teeth. *Dent Traumatol* 2006; 22: 83–9. [CrossRef]
- Diangelis AJ, Andreasen JO, Ebeleseder KA, et al. Interna-

- tional Association of Dental Traumatology guidelines for the management of traumatic dental injuries: 1. Fractures and luxations of permanent teeth. *Dent Traumatol* 2012; 28: 2–12. [\[CrossRef\]](#)
18. AlKhalifa JD, AlAzemi AA. Intrusive luxation of permanent teeth: a systematic review of factors important for treatment decision-making. *Dent Traumatol* 2014; 30: 169–75. [\[CrossRef\]](#)
 19. Patel S, Dumsha TC, Sydiskis RJ. Determining periodontal ligament (PDL) cell vitality from exarticulated teeth stored in saline or milk using fluorescein diacetate. *Int Endod J* 1994; 27: 1–5. [\[CrossRef\]](#)
 20. Layug ML, Barrett EJ, Kenny DJ. Interim storage of avulsed permanent teeth. *J Can Dent Assoc* 1998; 64: 357–69.
 21. dos Santos CL, Sonoda CK, Poi WR, Panzarini SR, Sundefeld ML, Negri MR. Delayed replantation of rat teeth after use of reconstituted powdered milk as a storage medium. *Dent Traumatol* 2009; 25: 51–7. [\[CrossRef\]](#)
 22. Blomlöf L. Storage of human periodontal ligament cells in a combination of different media. *J Dent Res* 1981; 60: 1904–6. [\[CrossRef\]](#)
 23. Kwan SC, Johnson JD, Cohenca N. The effect of splint material and thickness on tooth mobility after extraction and replantation using a human cadaveric model. *Dent Traumatol* 2012; 28: 277–81. [\[CrossRef\]](#)
 24. Hinckfuss SE, Messer LB. Splinting duration and periodontal outcomes for replanted avulsed teeth: a systematic review. *Dent Traumatol* 2009; 25: 150–7. [\[CrossRef\]](#)
 25. Andersson L, Lindskog S, Blomlöf L, Hedstrom KG, Hammarstrom L. Effect of masticatory stimulation on dentoalveolar ankylosis after experimental tooth replantation. *Endod Dent Traumatol* 1985; 1: 13–6. [\[CrossRef\]](#)
 26. Andreasen J. The effect of splinting upon periodontal healing after replantation of permanent incisors in monkeys. *Acta Odontol Scand* 1975; 33: 313–23. [\[CrossRef\]](#)
 27. Andreasen JO, Andreasen FM, Mejäre I, Cvek M. Healing of 400 intra-alveolar root fractures. 2. Effect of treatment factors such as treatment delay, repositioning, splinting type and period and antibiotics. *Dent Traumatol* 2004; 20: 203–11. [\[CrossRef\]](#)
 28. Mandel U, Viidik A. Effect of splinting on the mechanical and histological properties of the healing periodontal ligament in the vervet monkey (*Cercopithecus aethiops*). *Arch Oral Biol* 1989; 34: 209–17. [\[CrossRef\]](#)
 29. Kum KY, Kwon OT, Spångberg LS, *et al.* Effect of dexamethasone on root resorption after delayed replantation of rat tooth. *J Endod* 2003; 29: 810–3. [\[CrossRef\]](#)
 30. Selvig KA, Bjorvatn K, Claffey N. Effect of stannous fluoride and tetracycline on repair after delayed replantation of root-planed teeth in dogs. *Acta Odontol Scand* 1990; 48: 107–12. [\[CrossRef\]](#)
 31. da Silva LAB, Longo DL, Stuardi MBS, *et al.* Effect of root surface treatment with denosumab after delayed tooth replantation. *Clin Oral Investig* 2021; 25: 1255–64. [\[CrossRef\]](#)
 32. Shulman LB, Gedalia I, Feingold RM. Fluoride concentration in root surfaces and alveolar bone of fluoride-immersed monkey incisors three weeks after replantation. *J Dent Res* 1973; 52: 1314–6. [\[CrossRef\]](#)
 33. Flores MT, Andreasen JO, Bakland LK, *et al.* Guidelines for the evaluation and management of traumatic dental injuries. *Dent Traumatol* 2001; 17: 49–52. [\[CrossRef\]](#)
 34. Hammarström L, Blomlöf L, Feiglin B, Andersson L, Lindskog S. Replantation of teeth and antibiotic treatment. *Endod Dent Traumatol* 1986; 2: 51–7. [\[CrossRef\]](#)
 35. Sae-Lim V, Wang CY, Choi GW, Trope M. The effect of systemic tetracycline on resorption of dried replanted dogs' teeth. *Endod Dent Traumatol* 1998; 14: 127–32. [\[CrossRef\]](#)
 36. Andreasen JO, Jensen SS, Sae-Lim V. The role of antibiotics in preventing healing complications after traumatic dental injuries: a literature review. *Endod Topics* 2006; 14: 80–92. [\[CrossRef\]](#)
 37. Bourguignon C, Cohenca N, Lauridsen E, *et al.* International Association of Dental Traumatology guidelines for the management of traumatic dental injuries: 1. Fractures and luxations. *Dent Traumatol* 2020; 36: 314–30. [\[CrossRef\]](#)
 38. Calişkan MK. Surgical extrusion of a completely intruded permanent incisor. *J Endod* 1998; 24: 381–4. [\[CrossRef\]](#)
 39. Ebeleseder KA, Santler G, Glockner K, Hulla H, Pertl C, Quehenberger F. An analysis of 58 traumatically intruded and surgically extruded permanent teeth. *Endod Dent Traumatol* 2000; 16: 34–9. [\[CrossRef\]](#)
 40. Andreasen J. *Traumatic injuries of the teeth*. Philadelphia: Saunders; 1981.
 41. Cunha RF, Pavarini A, Percinoto C, Lima JE. Influence of surgical repositioning of mature permanent dog teeth following experimental intrusion: a histologic assessment. *Dent Traumatol* 2002; 18: 304–8. [\[CrossRef\]](#)
 42. Calişkan MK, Gomel M, Türkün M. Surgical extrusion of intruded immature permanent incisors: case report and review of the literature. *Oral Surg Oral Med Oral Pathol Oral Radiol Endod* 1998; 86: 461–4. [\[CrossRef\]](#)
 43. Cvek M. Treatment of non-vital permanent incisors with calcium hydroxide. II. Effect on external root resorption in luxated teeth compared with effect of root filling with gut-tapucha. A follow-up. *Odontol Revy* 1973; 24: 343–54.