

VERTEBROBASILAR INSUFFICIENCY DURING HEAD ROTATION IN THORACIC OUTLET SYNDROME: A CASE REPORT

Mustafa GÜRELİK, H. Murat GÖKSEL, Özen KARADAĞ, Ünal ÖZÜM

Cumhuriyet University School of Medicine, Department of Neurosurgery, Sivas

ÖZET

Torasik çıkış sendromunun nadiren vertebrobaziler yetmezliğe yol açtığı bildirilmiştir. Bu hastalar başlarını döndürdükleri zaman ortaya çıkan vertebrobaziler yetmezlik bulgularına sahiptirler. Başın rotasyonu sırasındaki anjiyografi ile vertebral arterdeki oklüzyonu göstermek mümkündür.

Sol torasik çıkış sendromu bulgularına sahip olan genç erkek hastanın Adson manevrası sırasında başını sola döndürdüğünde ortaya çıkan çift görme şikayeti vardı. Anjiyografide, başın rotasyonu sırasında vertebral arterde oklüzyon olduğu ortaya konuldu. Hem nötral hem de başın rotasyonu sırasında beyin sapı işitsel uyarılmış potansiyel çalışması yapıldı ve başın rotasyonu sırasında beyin sapı iskemi bulgularının ortaya çıktığı gösterildi. Cerrahi tedaviden sonra hasta yakınmalarının tam olarak düzeldiğini ifade etti. Geç postoperatif beyin sapı uyarılmış potansiyel çalışması iskemi bulgularının düzeldiğini gösterdi. Bu bulgular bize vertebrobaziler yetmezlik ve torasik çıkış sendromu olgularının değerlendirilmesinde, başın rotasyonu sırasında anjiyografi yapılmasının ve beyin sapı işitsel uyarılmış potansiyel çalışmasının önemini ortaya koydu.

Anahtar Sözcükler: Torasik çıkış sendromu, uyarılmış potansiyeller, vertebrobaziler yetmezlik

VERTEBROBASILAR INSUFFICIENCY DURING HEAD ROTATION IN THORACIC OUTLET SYNDROME: A CASE REPORT

Thoracic outlet syndrome leading to vertebrobasilar insufficiency had been reported very rarely. These patients have signs of vertebrobasilar insufficiency when they rotate their heads. It is possible to demonstrate occlusion of vertebral artery with angiography during head rotation.

A young man with left sided symptoms of thoracic outlet syndrome had also complained of diplopia when his head had turned to the left side during Adson maneuver. Angiography revealed occlusion of vertebral artery during head rotation. Brain stem auditory evoked potential study performed in both neutral and rotated head position and evidences of brainstem ischemia has been demonstrated during head rotation. The patient reported a complete improvement of his symptoms after surgical therapy. Late post-operative brain stem auditory evoked potential study revealed lack of abnormal findings.

These findings led us to emphasize the importance of performing the vertebral angiography while the head rotated; and the possible role of brain stem auditory evoked potential study in evaluation of vertebrobasilar insufficiency and thoracic outlet syndrome cases.

Key words: Evoked potentials, thoracic outlet syndrome, vertebrobasilar insufficiency

Introduction

Syndrome of hemodynamic vertebrobasilar insufficiency is known as "bow hunter's stroke". Intermittent vertebral artery compression occurs at the atlantoaxial level during the rotational head movements. But this occlusion is usually asymptomatic due to sufficient collateral flow (1,2, 3, 4, 5, 6).

In our case, thoracic outlet syndrome was leading vertebrobasilar insufficiency (VBI) with associated hemodynamic vertebrobasilar insufficiency when the head was turned on the left side. In patients who have VBI symptoms and signs, brain stem auditory evoked potential study is as valuable as angiography for diagnosis.

Case Report

Medical History: A 25-years old male patient was admitted to our clinic, with a 10-months history of headache and pain with early fatigue on the left arm. He was also complaining of diplopia and vertigo, which occur when he turns his head to the left side.

Physical and Neurological Examination: There was no major abnormal finding in the patient's general physical examination. Right and left arm arterial blood pressures were virtually equal. Adson test was positive on the left side. The patient reported diplopia with left sided head rotation during this maneuver.

There were only minor neurological

abnormalities, which were moderate atrophy on hypothenar and interosseous muscles of left hand with slight weakness of left thumb adduction.

Diagnostic Evaluation: Plain films of skull and cervical spine were normal. Electromyography (EMG) revealed affliction of the lower truncus of the left brachial plexus. Cranial computed tomography revealed no abnormality of the brain. Cervical angiography demonstrated a mild (20%) stenosis of the left proximal vertebral artery at C 5-6 level, during rotation of the head (Fig. 1). In addition, the left vertebral artery blood flow was relatively more than that of right vertebral artery in angiography during head rotation to both sides. Brain stem auditory evoked potential (BAEP) study performed in this patient; both in the neutral and bilaterally rotated positions of his head. When the head was in the neutral position, BAEP latencies were in normal limits, in both sides. However, when the head was turned to the left side and BAEP study performed; a clearly increased P5 wave latency had been detected in the right side of the brain stem (Fig. 2).

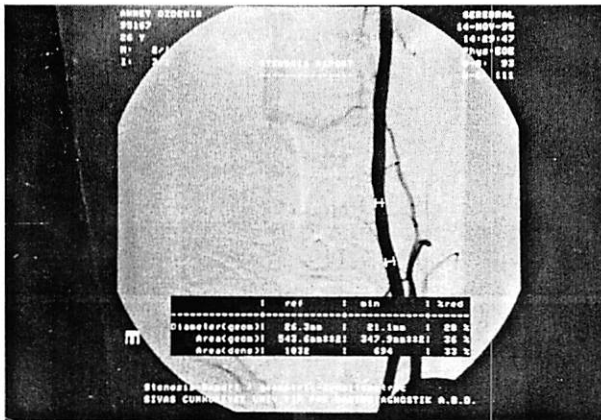


Fig. 1. Cerebral DSA image. Stenosis is seen on the left proximal vertebral artery (at C5/C6 level) with rotation of the head.

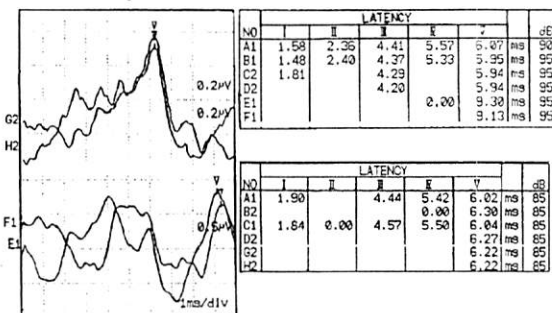


Fig. 2. E and F are preoperative tracings of the right side in rotation position of the head in BAEP studying, G and H are postoperative tracings of the right side in rotation position of the head.

Surgical Treatment: The left anterior scalen muscle was cut, in addition to removal of first 2 thoracic sympathetic chain with 2/3 distal portion of stellate ganglion.

Follow-up: All symptoms were completely relieved, immediately after the surgical treatment and the patient remained symptomless during the follow-up period. He refused a postoperative angiography; but BAEP study repeated two months after the surgery and normal latencies were detected both in neutral and rotated positions of the head (Fig. 2).

Discussion

Thoracic outlet syndrome presented with symptoms and signs of VBI had been infrequently reported in the literature. In these cases, VBI occur with rotation of the head (1, 2, 3, 4, 5, 6, 7, 8, 9). Under physiological conditions, it is well known that when the head is turned 60 degrees to one side, an overt decrease occurs in opposite vertebral artery blood flow, even it completely ceases at 80 degrees of rotation (10). If there is any pathological condition, causing a borderline vertebral artery blood flow in one side; brain stem ischemia is inevitable with significant physiological decrease of opposite vertebral artery blood flow following rotation of the head to the affected side. We believe in that, left sided thoracic outlet syndrome causing an external compression of the left proximal vertebral artery, thus hypoperfusion of the brain stem occurs with left sided head rotation due to above mentioned mechanism.

Digital angiography is the best way to measure the diameter of cervical vertebral artery. Otherwise BAEP is a useful tool to assess brain stem function (11, 12). The fourth and fifth peak waves reflect the electrical activity in inferior collicular part of vestibulocochlear pathways. Changes in amplitude and latencies of these waves may be an indicator of partial brain stem dysfunction (11). In our case, we accepted the increased P5 latency as an evidence of brain ischemia. The improvement of this pathological BAEP finding after surgical treatment supports this explanation.

Depending on the course of this case, we can recommend a careful history taking and neurological examination, targeting to find slight or hidden evidences of VBI in thoracic outlet syndrome patients. If there is a suspicion about the occurrence of VBI, BAEP study should be

performed both in neutral and rotated positions of the head. Vertebral angiography must be done to diagnose a stenotic vertebral artery only if P4 and/or P5 wave abnormalities are present in BAEP study. Angiography should also be performed both in neutral and rotated positions of the head in thoracic outlet syndrome cases.

REFERENCES

1. Barton JW, Margolis MT: Rotational obstruction of the vertebral artery at the atlantoaxial joint. *Neuroradiology* 1975; 9: 117-120.
2. Erwin CW, Erwin AC, Drake ME: Evoked potentials from the visual, auditory, and somatosensory systems, in Wilkins RH, Rengachary SS (ed), *Neurosurgery*, volume 1, second edition, New York: McGraw Hill, 1996: 217-229.
3. Fox MW, Piepgras DG, Bartleson JD: Anterolateral decompression of the atlantoaxial vertebral artery for symptomatic positional occlusion of the vertebral artery. *J Neurosurg* 1995; 83: 737-740.
4. Frizoni GB, Anzola GP: Vertebrobasilar ischemia after neck motion. *Stroke* 1991; 22: 1452-1460.
5. Husni EA, Storer J: The syndrome of mechanical occlusion of the vertebral artery; A new clinical concept. *JAMA* 1996; 196: 475-478.
6. Kuether TA, Nesbit GM, Clark WM, Barnwell SL: Rotational vertebral artery occlusion; A mechanism of vertebrobasilar insufficiency. *Neurosurgery* 1997; 41: 427-433.
7. Murray NMF: Evoked Potentials, in Crockard A, Hayward R, Hoff JT (eds), *Neurosurgery*, Volume 2, second edition, Boston:Blackwell scientific publications, 1992: 717-734.
8. Nagler W: Vertebral artery obstruction by hyperextension of the neck; report of three cases. *Arch Phys Med Rehabil* 1973; 54: 237-240.
9. Sell JJ, Rael JR, Orrison WW: Rotational vertebrobasilar insufficiency as component of thoracic outlet syndrome resulting in transient blindness. *J Neurosurg* 1994; 81: 617-619.
10. Shimizu T, Shiro W, Kojima T: Decompression of the vertebral artery for bow hunter stroke; Case report. *J Neurosurg* 1988; 69: 127-131.
11. Sorenson BF. Bow hunter's stroke. *Neurosurgery* 1978; 2: 259-261.
12. Toole JF and Burrow DD: Pathophysiology and clinical evaluation of ischemic vascular disease, in Youmans JR (ed), *Neurological Surgery*, volume 3, third edition, Philadelphia: W.B. Saunders, 1990: 1463-1509.