



Case Report

The Cause of an Unusual Abdominal Pain in Children: Splenic Torsiyon – Three Case Report

Mesut Demir, Seyma Demirci, Ceylan Hamzaoglu, Meltem Kaba, Nihat Sever

Department of Pediatric Surgery, Sisli Hamidiye Etfal Training and Research Hospital, University of Health Sciences, Istanbul, Türkiye

Abstract

Splenic torsion is a rare cause of abdominal pain that may develop due to laxity or absence of the ligaments that stabilize the spleen. A torsioned spleen may present with an acute abdomen clinically and may require urgent surgical intervention. We aimed to discuss three pediatric cases who applied to our clinic with acute abdomen symptoms after splenic torsion and their treatment approaches. Case 1: A 10-year-old female patient presented with complaints of progressive abdominal pain and non-bilious vomiting. On examination, there was abdominal tenderness and palpable fullness in the left lower quadrant. Imaging methods were compatible with splenic torsion. Laparoscopic splenectomy was performed. Case 2: A 4-year-old girl presented with complaints of abdominal pain and non-bilious vomiting. On examination, diffuse tenderness in the abdomen and defense-rebound were positive. Imaging methods were compatible with splenic torsion. On exploration, it was observed that the spleen was torsioned in different directions around the double pedicle. Splenectomy was performed. Case 3: A 5-year-old male patient was operated in another hospital with the complaint of abdominal pain, with the diagnosis of acute appendicitis, with open surgery. However, there was no improvement in the patient's symptoms after surgery. The patient was consulted to our clinic on the 5th post-operative day. Imaging methods were found to be compatible with splenic torsion. Laparoscopic splenectomy was performed. In the pediatric population, splenic torsion can cause acute or chronic abdominal pain of unknown cause. Splenopexy should be the first goal of treatment in torsion, but splenectomy is the only treatment option in complicated cases and laparoscopy can be used safely even in complicated cases.

Keywords: Laparoscopy, splenic torsion, splenopexy

Please cite this article as "Demir M, Demirci S, Hamzaoglu C, Kaba M, Sever N. The Cause of an Unusual Abdominal Pain in Children: Splenic Torsiyon – Three Case Report. Med Bull Sisli Etfal Hosp 2022;56(3):435–438".

Splenic torsion is a rare clinical condition which results of absence or looseness of ligaments which stabilize the spleen.^[1,2] Its incidence is 0.2–0.25% of cases with total splenectomy.^[3] In pediatric population, splenic torsion is caused by a congenital abnormality of splenic ligaments,^[4] spleen can move freely in abdominal cavity.^[5,6] The splenic torsion can occur as a mobile mass in the abdomen, episodes of chronic abdominal pain, and acute abdomen or

remain asymptomatic. Splenic torsion can cause an acute abdomen and may require emergency surgery.

Spleen protective approach should be the first goal of treatment in splenic torsion. However, splenectomy is the only treatment option in complicated cases. Laparoscopic splenectomy can be performed safely even in complicated cases.

In this study, we aimed to present our three cases who were

Address for correspondence: Mesut Demir, MD. Sisli Hamidiye Etfal Egitim ve Arastirma Hastanesi, Cocuk Cerrahisi Anabilim Dalı, Saglik Bilimleri Universitesi, Istanbul, Türkiye

Phone: +90 532 362 04 38 **E-mail:** dr.mesut.demir@gmail.com

Submitted Date: June 01, 2021 **Accepted Date:** July 16, 2021 **Available Online Date:** September 22, 2022

©Copyright 2022 by The Medical Bulletin of Sisli Etfal Hospital - Available online at www.sislietfalthip.org

OPEN ACCESS This is an open access article under the CC BY-NC license (<http://creativecommons.org/licenses/by-nc/4.0/>).



operated in our clinic for splenic torsion. The procedure we aim for was laparoscopic splenopexy, but laparoscopic splenectomy performed due to splenic infarction and ischemia in all three of our cases.

Case Report

Case 1 – A 10-year-old female patient was admitted to our emergency department with complaints of abdominal pain, non-bilious vomiting, diarrhea, and fewer symptoms that started 3 days ago and gradually increased. In physical examination, tender abdomen and palpable fullness in the left quadrant were found, but no sign of defense or rebound. Laboratory test results were white blood cell (WBC) $15.690/\text{mm}^3$ and C-reactive protein (CRP) 178 mg/L. Abdominal Doppler ultrasonography (USG) and intravenous (IV) contrast abdominal computed tomography (CT) findings were coherent with spleen torsion (Fig. 1). Laparoscopic exploration was planned. In the per-operative exploration, a necrotic appearance was observed in the spleen. Laparoscopic splenectomy was performed, because the spleen blood circulation did not return after splenic detorsion.

Case 2 – A 4-year-old female patient was admitted to our emergency department with complaints of abdominal pain and non-bilious vomiting that started 2 days ago. In physical examination, diffuse abdominal tenderness, defense, and rebound were found. Laboratory test results were WBC $19.900/\text{mm}^3$ and CRP 189.9 mg/L. In abdominal Doppler USG, it was determined that the ectopic spleen moved toward the right lower quadrant, and the WS had no blood circulation. It was consistent with splenic torsion on IV contrast abdominal CT imaging. Laparoscopic exploration was planned. In the per-operative exploration, splenic torsion was observed in two different directions around two separate pedicles in the spleen. The operation was continued with laparotomy and the splenic torsion was successfully detorsioned. However, splenectomy was performed because spleen blood circulation did not reappear (Fig. 2).

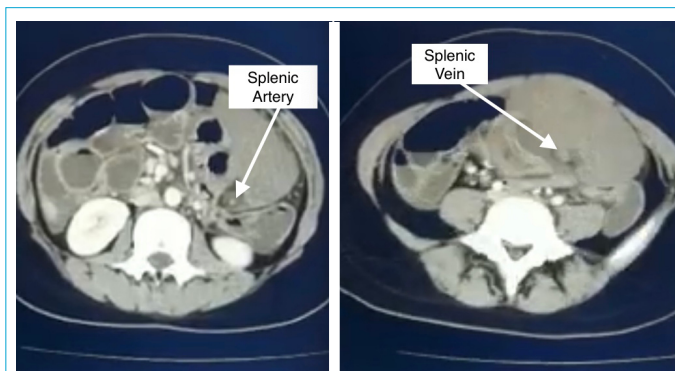


Figure 1. Intravenous contrast abdominal Computed tomography view of splenic torsion and splenic vessels.

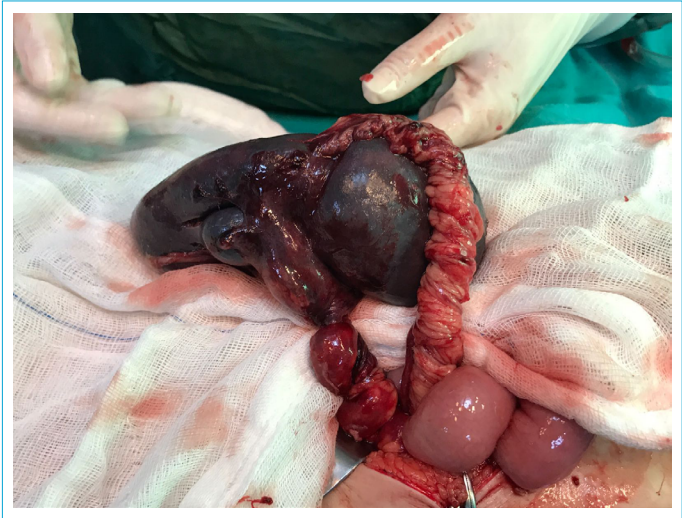


Figure 2. Intraoperative view of splenic torsion around the two pedicles.

Case 3 – A 5-year-old male patient was admitted to our emergency department with complaints of abdominal pain and bilious vomiting that started 5 days ago. In the patient's history, he reported that he had undergone an open appendectomy operation with a preliminary diagnosis of appendicitis in another center 3 days ago. In physical examination, diffuse abdominal tenderness and defense were found. Laboratory test results were WBC $14600/\text{mm}^3$, CRP 53 mg/L, and PLT $1.100.10^9/\text{L}$. On IV contrast, abdominal CT imaging revealed an enlarged ectopic spleen moving in the lower abdomen, and the ectopic spleen was found to have no blood circulation. In the pre-operative hematology consultation, it was stated that elevated PLT values may be secondary to splenic torsion and would gradually regress in the post-operative period. Laparoscopic splenectomy was planned. In the per-operative exploration, a necrotic appearance was observed in the spleen. The splenic torsion was successfully detorsioned. However, splenectomy was performed, because spleen blood circulation did not reappear (Fig. 3). The patient's PLT values decreased to $648.10^9/\text{L}$ at the 3rd month and to $322.10^9/\text{L}$ at the 6th month. The first and last post-operative incision images of the patient are shown (Fig. 4).

All three of our patients recovered completely on the third post-operative day and were discharged from the hospital. Pathology results of all the cases were coherent with venous congestion and infarction.

Discussion

Splenic torsion is congenital or acquired clinical entity of absence or laxity of the splenic ligaments.^[2] Loose or deficient the splenic ligaments would not be able to fixate the spleen and cause its hypermobile movement in the abdominal cavity. This hypermobile spleen may remain as-

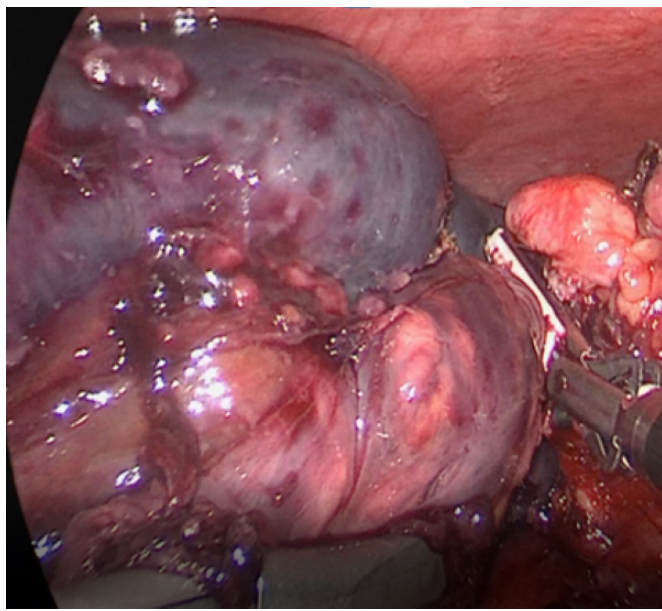


Figure 3. Laparoscopic view of torsioned spleen.

ymptomatic for many years or may become symptomatic due to movement around the pedicle of the spleen. It can cause acute abdominal complications such as splenic torsion, splenic infarction, splenic vein thrombosis, intestinal obstruction, pancreatitis, and gastric outlet obstruction.^[4] Splenic torsion is a rare cause of acute abdomen and should be considered among the differential diagnosis of acute abdomen.

All three of our cases were admitted to the hospital with acute abdomen symptoms. Case 3 was operated in another center with the preliminary diagnosis of acute appendicitis, and splenic torsion was diagnosed by means of detailed imaging methods. It is very difficult to diagnose splenic torsion cases, while they are asymptomatic, as they apply to the hospital after splenic torsion develops and becomes complicated.^[3,4] The diagnosis of splenic torsion can be made by abdominal color Doppler USG and IV contrast abdominal CT taken in emergency situations.^[7] Abdominal color Doppler USG is the most commonly used imaging to evaluate blood circulation in cases of splenic torsion.^[8] On IV contrast abdominal CT imaging, an empty spleen region, an ectopic spleen, and whirlpool sign helps diagnose splenic torsion.^[9] Splenopexy is the preferred treatment method when a splenic torsion is diagnosed, even if the patient is asymptomatic. Splenopexy can be performed with open or laparoscopic methods. In splenopexy, a pouch is created in the omental or retroperitoneal space and the spleen is fixed to the left upper quadrant of the abdomen.^[10] However, when the complications occur, preferred procedure is the splenectomy.^[11,12] We performed splenectomy in all our cases because the blood circulation of the spleen did

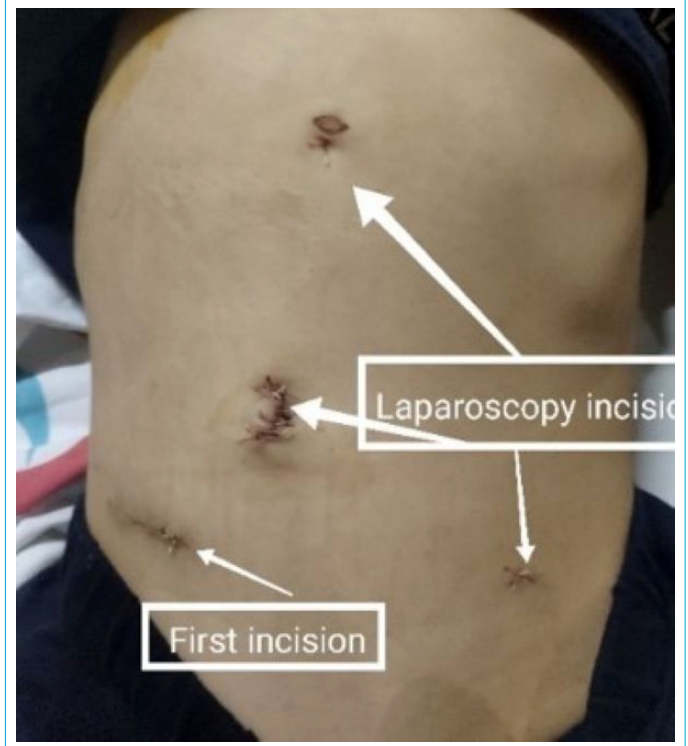

Figure 4. Appendicitis and laparoscopic incisions of the patient.

not return despite detorsioning the spleen. Laparoscopic splenectomy can be performed safely even in complicated cases.^[13] We can see the importance of laparoscopy in Case 3. When the patient was admitted to another center with acute abdominal symptoms, open appendectomy was performed with the preliminary diagnosis of acute appendicitis. McBurney incision is made in open appendectomy, but this incision is not sufficient to diagnose per-operative splenic torsion. The patient was referred to our clinic due to abdominal tenderness and defense did not regress in the post-operative follow-up. The patient was diagnosed with splenic torsion after IV contrast abdominal CT imaging, and laparoscopic splenectomy was performed. Laparoscopy has the advantage of displaying the entire abdomen (liver, spleen, inguinal canal, pelvis, gallbladder, anterior and posterior walls of stomach, and duodenum) in acute abdomen cases and helps us to identify pathologies that cannot be seen with small laparotomy incisions. In two of the three cases, the surgery was completed without complications with laparoscopic splenectomy. In Case 2, the reason for the transition to laparotomy was due to the surgeon's inexperience in laparoscopic surgery.

Conclusion

Spleen torsion is a rare abdominal emergency. It occurs due to the absence or laxity of the normal spleen ligaments. Splenic torsion can cause unexplained acute or chronic ab-

dominal pain. Splenopexy is the primary approach in splenic torsion, but splenectomy should be performed in complicated cases. Laparoscopy can be safely performed even in cases with complicated splenic torsion. In the pediatric population, the laparoscopic approach is also preferred in acute abdomen cases due to its known advantages such as less comorbidity, effortless exploration, easy progression in case of misdiagnosis, reduction in post-operative pain, and better cosmetic results. For these reasons, laparoscopy should be the first choice in pediatric splenic torsion.

Disclosures

Informed consent: Written informed consent was obtained from the patient for the publication of the case report and the accompanying images.

Peer-review: Externally peer-reviewed.

Conflict of Interest: None declared.

Authorship Contributions: Concept – M.D.; Design – S.D.; Supervision – M.D.; Materials – C.H.; Data collection &/or processing – M.K.; Analysis and/or interpretation – N.S.; Literature search – C.H.; Writing – S.D.; Critical review – N.S.

References

1. Cecchetto G, Dall'Igna P, Dalle Nogare C, Gasparella P, Zanon GF. Acute splenic torsion in children: which is the best treatment? A case report. *Pediatr Med Chir* 2012;34:146–7. [\[CrossRef\]](#)
2. Ben Ely A, Segulier E, Lotan G, Strauss S, Gayer G. Familial wandering spleen: a first instance. *J Pediatr Surg* 2008;43:E23–5. [\[CrossRef\]](#)
3. Assaf R, Shebli B, Alzahran A, Rahmeh AR, Mansour A, Hamza R, et al. Acute abdomen due to an infarction of wandering spleen: case report. *J Surg Case Rep* 2020;2020:rjz378. [\[CrossRef\]](#)
4. Bond LM, Doud AN, Downard CD, Bond SJ. Acute presentation of pediatric splenic torsion. *J Pediatr Surg Case Rep* 2019;48(2019)101267. [\[CrossRef\]](#)
5. Palanivelu C, Rangarajan M, Senthilkumar R, Parthasarathi R, Kavalakat AJ. Laparoscopic mesh splenopexy (sandwich technique) for wandering spleen. *JSLs* 2007;11:246–51.
6. Seashore JH, McIntosh S. Elective splenopexy for wandering spleen. *J Pediatr Surg* 1990;25:270–2. [\[CrossRef\]](#)
7. Nemcek AA Jr, Miller FH, Fitzgerald SW. Acute torsion of a wandering spleen: diagnosis by CT and duplex Doppler and color flow sonography. *AJR Am J Roentgenol* 1991;157:307–9. [\[CrossRef\]](#)
8. Cohen O, Baazov A, Samuk I, Schwarz M, Kravarusic D, Freud E. Emergencies in the treatment of wandering spleen. *Isr Med Assoc J* 2018;20:354–7.
9. Peretti M, Mariotto A, Scirè G, Pani E, Zambaldo S, Bianchi S, et al. Wandering spleen with a ten-time twisted vascular pedicle. *Pediatr Med Chir* 2016;38:119. [\[CrossRef\]](#)
10. Hedeshian MH, Hirsh MP, Danielson PD. Laparoscopic splenopexy of a pediatric wandering spleen by creation of a retroperitoneal pocket. *J Laparoendosc Adv Surg Tech A* 2005;15:670–2. [\[CrossRef\]](#)
11. Awan M, Gallego JL, Al Hamadi A, Vinod VC. Torsion of wandering spleen treated by laparoscopic splenopexy: A case report. *Int J Surg Case Rep* 2019;62:58–61. [\[CrossRef\]](#)
12. Kargl S, Sekyra P, Pumberger W. Acute abdomen due to splenic torsion. *Arch Dis Child* 2013;98:537. [\[CrossRef\]](#)
13. Alqadi GO, Saxena AK. Is laparoscopic approach for wandering spleen in children an option? *J Minim Access Surg* 2018;15:93–7.