



Original Research

Hormonally Active Adrenal tumors; Challenges and Outcomes for Different Surgical Approaches

Husnu Aydin,¹ Ahmet Cem Dural,¹ Nuri Alper Sahbaz,¹ Sezer Bulut,¹ Deniz Guzey,¹ Cevher Akarsu,¹
 Evin Bozkur,² Mehmet Karabulut¹

¹Department of General Surgery, Bakırkoy Dr Sadi Konuk Training and Research Hospital, İstanbul, Turkey

²Department of Endocrinology, Bakırkoy Dr Sadi Konuk Training and Research Hospital, İstanbul, Turkey

Abstract

Objective: The aim of this study is to compare the intraoperative and short-term outcomes of different surgical approaches for hormone active and non-functional adrenal masses.

Methods: The data of 206 patients who underwent adrenal gland surgery in our clinic between 2012 and 2020 were retrospectively analyzed. Pre-operative outpatient clinic records of the patients, imaging methods, laboratory results and surgery records, operation time (OT), amount of bleeding, duration of hospital stay, and complications were evaluated. Patients were divided into two groups as those with non-functional mass ($n=80$) and those with hormoneactive mass ($n=126$).

Results: The median age of the patients was 52 (range 19–83) and 77.2% of them were female. Tumor size was larger in hormone active group ($p=0.311$), and the difference was more pronounced in the pheochromocytoma subgroup ($p=0.088$). The rate of transition to open surgery was similar in both groups (0.959), and no conversion to laparoscopy or conventional open surgery was performed in robotic cases. The duration of surgery ($p=0.669$), mean amount of blood loss ($p=0.834$), and mean hospital stay ($p=0.195$) were also similar between the two groups. Intraoperative and post-operative complications were similar between two groups ($p=0.573$ and $p=0.415$, respectively). Considering the subgroup analysis of the patients in hormone active group; the duration of hospital stay was longer in patients with Cushing syndrome ($p=0.001$), while there was no difference in OT and estimated blood loss between patients who were operated for Conn, Cushing, and pheochromocytoma ($p=0.086$ and $p=0.099$; respectively).

Conclusion: Surgical results of hormone active adrenal masses were found to be similar to non-functional masses. Although the hormonal condition of the mass does not change the difficulty level of the surgical procedure, it may be recommended that the robotic approach be preferred to facilitate manipulation in these masses.

Keywords: Adrenal gland surgery; hormone active adrenal mass; minimally invasive surgery.

Please cite this article as: Aydin H, Dural AC, Sahbaz NA, Bulut S, Guzey D, Akarsu C, et al. Hormonally Active Adrenal tumors; Challenges and Outcomes for Different Surgical Approaches. Med Bull Sisli Etfal Hosp 2021;55(3):325–332.

Address for correspondence: Husnu Aydin, MD. Bakırkoy Dr. Sadi Konuk Eğitim ve Araştırma Hastanesi, Genel Cerrahi 4. Kat Zuhuratbaba Mah. Tevfik Sağlam Cd. No:11 Bakırkoy / İstanbul / Turkey

Phone: +90 532 247 11 52 **E-mail:** drhusnuaydin@gmail.com

Submitted Date: May 20, 2021 **Accepted Date:** July 18, 2021 **Available Online Date:** September 24, 2021

©Copyright 2021 by The Medical Bulletin of Sisli Etfal Hospital - Available online at www.sislietfaltip.org

OPEN ACCESS This is an open access article under the CC BY-NC license (<http://creativecommons.org/licenses/by-nc/4.0/>).



Introduction

In recent years, advances in imaging technologies and easier access to health-care services have enabled adrenal gland masses to be detected more frequently. Although adrenal tumors are among the most common tumors in humans, they are often adenomas that do not require any treatment.^[1]

One of the operation criteria is hormonal status the patient and the current guidelines recommend surgical removal of all hormonally active tumors regardless of the size.^[1,2] Majority of hormone active (functional) adrenal masses present with glucocorticoid (Cushing's syndrome), mineralocorticoid (Conn's syndrome), or catecholamine (pheochromocytoma) hypersecretion.^[3] In different series, the probability of adrenal masses to be functional varies between 6% and 30%.^[4,5]

The main indication for surgery for non-secretary (non-functional) adrenal tumors is suspicion of malignancy. In pre-operative imaging examinations, invasion to surrounding tissues or metastasis is the most important marker for malignancy. In addition, surgical resection is recommended for tumors larger than 4 cm due to the increased risk of malignancy.^[2,3,6]

Although surgical resection of adrenal tumors can be performed with minimally invasive methods (laparoscopic or robotic), laparotomy may also be the first choice for patients with a large tumor size or suspicion of malignancy. Conversion to laparotomy due to unmanageable situations during laparoscopic or robotic surgery is also a possibility.^[6]

In recent years, advances in anesthesia and surgical techniques have contributed to the reduction of morbidity of adrenalectomy operations. However, functional adrenal tumors are associated with higher operational risk due to both hormone-related comorbidities of the patients and hemodynamic effects of hormone excess during surgery.^[7]

This study aimed to compare functional and non-functional adrenal tumors, which we operated with minimal invasive methods or laparotomy, the operative challenges regarding intraoperative parameters and short-term outcomes.

Methods

Study Design

Between 2009 and 2020, 208 adrenalectomy procedures were performed at our department. Two patients were excluded from the study due to the dearth of precise determination of the hormonal status preoperatively. The remaining 206 patients were divided into two groups as

patients with functional tumors (Group 1, $n=126$) and non-functional tumors (Group 2, $n=80$).

Adrenal masses were evaluated in terms of size and hormonal activity with laboratory results and radiological evaluation according to the current guidelines.^[2,6] The indication for adrenalectomy was made by the multidisciplinary endocrine board, which includes specialists in general surgery, endocrinology, pathology, radiology, and nuclear medicine.

Patients' demographic findings, body mass indexes, American Society of Anesthesiologists scores, Charlson comorbidity index scores, imaging results, laboratory findings, and medical history were evaluated retrospectively. Surgical findings, duration of surgery, the rate of conversion to laparoscopic or open surgery, perioperative blood loss, intraoperative complications, and length of hospital stay (LOS) were also investigated.

The two groups were compared regarding the demographic data, clinical features, and perioperative outcomes. Surgical resection indications for non-secretary (non-functional) adrenal tumors were suspicion of malignancy and tumor size. In imaging examinations, invasion to surrounding tissues or metastasis was considered as malignancy suspicion, and surgical resection was performed. Furthermore, tumors were resected which larger than 4 cm due to the increased risk of malignancy.

Plasma and urine tests were performed to determine hormonal activity in all patients whose adrenal mass was detected in a computerized tomography scan or magnetic resonance imaging. For this purpose; plasma cortisol, dehydroepiandrosterone sulfate, and adrenocorticotrophic hormone were examined for Cushing's syndrome. In addition; a 1 mg dexamethasone suppression test (DST) was applied. While values above 5 mcg/dL were considered Cushing's syndrome, 4 mg DST (2-day 2 mg) was administered to patients with values between 1.8 and 5 mcg/dL. Plasma renin activity and serum aldosterone values were measured for Conn's syndrome. A ratio of aldosterone/renin over 20 was considered positive for Conn's. Catecholamine metabolites in 24h urine sample were analyzed for pheochromocytoma in all patients. For the diagnosis of pheochromocytoma, values 3–4 times higher than the upper limit were expected. If pheochromocytoma was diagnosed, thyroid and neck ultrasound was performed to exclude multiple endocrine neoplasia syndrome. In addition, serum calcium, parathormone, and calcitonin levels were also measured.

Patients with hypercortisolism findings underwent surgery on an appropriate steroid treatment protocol. Alpha

and beta-blockers were administered to patients diagnosed with pheochromocytoma in the 10–14 days before the operation. The patients were followed up after discharge in endocrinology and general surgery outpatient clinics.

Operative Technique

Standard lateral transperitoneal adrenalectomy operation was performed under general anesthesia in all patients, as we have described in details in our previous studies.^[8–10]

All procedures have been performed by experienced endocrine surgeons who had completed their learning curve. Our general surgery department and the endocrine surgery division are established with four surgeons who have completed their learning curve and provide specific services with a high volume (approximately 20 adrenalectomy surgery/year).

The decision to laparoscopic or robotic procedure was determined by surgeon's preference. In laparoscopic and robotic methods, patient preparation, position, and defined trocar insertion sites were similar, but an additional trocar was used for irrigation or clip application in the robotic procedure. The placement of these trocars, which were used to facilitate surgical manipulation, was determined according to the patient's weight and anatomical structure. Three ports were used in the left adrenalectomy, and four ports (for one port liver retractor) were used in the right adrenalectomy. Laparotomy was performed in two patients in the functional group and one patient in the non-functional group due to the mass size.

The subcostal incision was used for laparotomy. Hook cautery and vessel sealing devices were used for adrenal gland dissection. Operation time (OT) was recorded from skin incision to skin closure.

Ethics

Informed consent was obtained from all patients regarding the procedure and possible complications of adrenal gland surgery. All procedures were carried out by the ethical standards and subsequent amendments of the 1964 Helsinki Declaration. Ethics committee approval was received from the local ethics committee (No: 2020-5-10 Date: March 2, 2020).

Statistical Analysis

Statistical analyses were conducted on JMP® software version 9.0.1 (SAS®, Cary, NC). Continuous variables were expressed as mean±SD and median (IQR). Categorical variables were expressed as frequencies and percentages. Student's *t*-test was used to compare parametric

continuous variables, and the Mann–Whitney U-test was used to compare non-parametric continuous variables. Categorical variables were compared with the Chi-square test. $p < 0.05$ was considered statistically significant.

Results

The median age of the patients was 52 (range 19–83) and 77.2% of them were female ($n=159$). Demographic findings and tumor sizes were similar between the two groups (Table 1). In non-functional group, 72 patients were operated laparoscopically, 7 robotically, and 1 by laparotomy. In hormone active group, 92 patients were operated laparoscopically, 32 patients robotically, and 2 patients by laparotomy ($p=0.011$). The rates of conversion to open surgery were similar in both groups (0.959), and no conversion to laparoscopy or conventional open surgery was performed in robotic cases. The reason for conversion from laparoscopic to open method in both groups was exploration difficulty and bleeding. The mean duration of surgery ($p=0.669$), mean amount of blood loss ($p=0.834$), and mean LOS were also similar between the two groups ($p=0.195$) (Table 1).

Intraoperative complications were observed in five patients as diaphragm injury, left colon serosal hematoma, pancreatic injury, small bowel injury, and bleeding in the functional group and in one patient as bleeding in the non-functional group ($p=0.207$) (Table 1).

Post-operative complications were observed in six patients in the functional group. These were pancreatic fistula, atelectasis, wound infection ($n=2$), urinary tract infection, and ileus. In the non-functional group, one patient had ileus, and two patients had atelectasis ($p=0.415$) (Table 1).

In hormone active group, 53% of the patients had Cushing's syndrome ($n=67$), 27% had pheochromocytoma ($n=34$), 16% had Conn's syndrome ($n=20$), and 4% ($n=5$) had other diagnoses (metastatic mass, congenital adrenal hyperplasia, etc.). Considering the subgroup analyses of the patients in hormone active group; while there was no difference in OT and estimated blood loss (EBL) between patients who were operated for Conn, Cushing, and pheochromocytoma ($p=0.086$ and $p=0.099$; respectively), the LOS was longer in patients with Cushing ($p=0.001$) (Table 2).

According to the final post-operative histopathology results, the most frequently detected pathology in both the functional and non-functional groups was adrenocortical adenoma (73.8% and 48.75%, respectively). The second most common pathology was pheochromocytoma in the functional group with a rate of 18.25% and adrenal cyst in the non-functional group with a rate of 27.5% (Table 3).

Table 1. Demographic findings and intraoperative outcomes of functional and non-functional tumors

Parameter	Non-functional (n=80)	Functional (n=126)	p value
Age(years), median (IQR)	53 (45–61)	52 (43–58)	0.07
Gender, n (%)			0.105
Female	57 (71)	102 (81)	
Male	23 (29)	24 (19)	
BMI (kg/m²), mean±SD	31±6.6	29.6±5.5	0.122
ASA score, n(%)			0.184
1	8 (10)	5 (4)	
2	49 (61)	71 (56)	
3	21 (26)	47 (37)	
4	2 (3)	3 (3)	
CCIscore, n(%)			0.852
2–3	42 (52)	68 (54)	
4–5	27 (34)	44 (35)	
6–7	11 (14)	14 (11)	
Previous abdominal surgery			0.292
Yes	30 (37.5)	38 (30)	
No	50 (62.5)	88 (70)	
Localization			0.152
Right	45 (56)	58 (46)	
Left	35 (44)	68 (54)	
Tumor size (mm), mean±SD	58.2±25.8	62.1±27.8	0.311
Operation time (min), mean±SD	131±49	134±46.5	0.669
Intraoperative complication, n (%)	1 (1.3)	5 (4)	0.573
EBL(ml), mean±SD	60±24	61±34	0.834
Post-operative complication, n (%)	2 (2.5)	6 (4.8)	0.415
Length of hospital stay (days), mean±SD	2.4±2	2.8±1.7	0.195
Approach, n (%)			0.011
Open	1 (1)	2 (2)	
Laparoscopic	72 (90)	92 (73)	
Robotic	7 (9)	31 (25)	
Conversion to open, n (%)			0.959
Laparoscopic	2 (1)	2 (1)	
Robotic	0	0 (0)	

SD: Standard deviation; ASA: American Society of Anesthesiologists; BMI: Body mass index; CCI: Charlson comorbidity index; EBL: Estimated blood loss.

Discussion

This article showed that the perioperative outcomes of hormone active adrenal tumors are similar to non-functional tumors. In addition, subgroup analysis of patients with functional tumors (Conn, Cushing, and pheochromocytoma)

showed that the perioperative outcomes were similar among these tumors.

Functional adrenal tumor surgery possesses challenges due to both direct and indirect effects of the secreted hormones.^[7]

Table 2. Intraoperative outcomes of functional tumors

Parameter	Conn (n=20)	Cushing (n=67)	Pheochromocytoma (n=34)	p value
Tumor size (mm)	50.1±23.3	56±19.7	63.2±23.1	0.088
Approach, n (%)				0.354
<i>Laparoscopic</i>	13 (65)	49 (73.1)	28 (82.4)	
<i>Robotic</i>	7 (35)	18 (26.9)	6 (17.6)	
Operation time, mean (min)	141±45.9	125.1±45	142.8±7.6	0.086
Estimated blood loss (ml)	59±17	56.6±27.5	69±43.7	0.099
Length of hospital stay (days)	1.9±1.3	3.1±1.9	2.4±1.2	0.001

Table 3. Final histopathology results of patients

Final pathology results, n (%)	Non-functional (n=80)	Functional (n=126)
Adrenal cortical adenoma	39 (48.75)	93 (73.8)
Pheochromocytoma	1 (1.25)	23 (18.25)
Adrenal cyst	22 (27.5)	1 (0.79)
Adrenal cortical nodular hyperplasia	5 (6.25)	4 (3.17)
Myelolipoma	3 (3.75)	2 (1.59)
Adrenal cortical carcinoma	5 (6.25)	-
Extra-adrenal metastasis	2* (2.5)	1** (0.79)
Other	3 [†] (3.75)	2 [‡] (1.59)

*Renal cell carcinoma and invasive ductal carcinoma; **Lung carcinoma,

[†]Ganglioneuroma, schwannoma, and hibernoma, [‡]Hemangioma and inflammatory pseudotumor.

Excessive manipulation during surgical dissection of pheochromocytoma can cause catecholamine secretion and unexpected hemodynamic instability, leading to serious cardiovascular events. In addition, a capsule rupture that may occur during surgical dissection may have disruptive consequences for the patient due to its malignant potential.^[7]

Patients with Cushing's syndrome, comorbidities caused by cortisol hypersecretion may also cause troubles in the perioperative period. Electrolyte abnormalities and increased blood pressure can be seen during surgery. In addition, potential thromboembolic events can lead to life-threatening risks. The increased risk of infection should also be taken into account.^[4,7]

In primary hyperaldosteronism, where surgical resection is curative in unilateral disease, the tumor size is usually

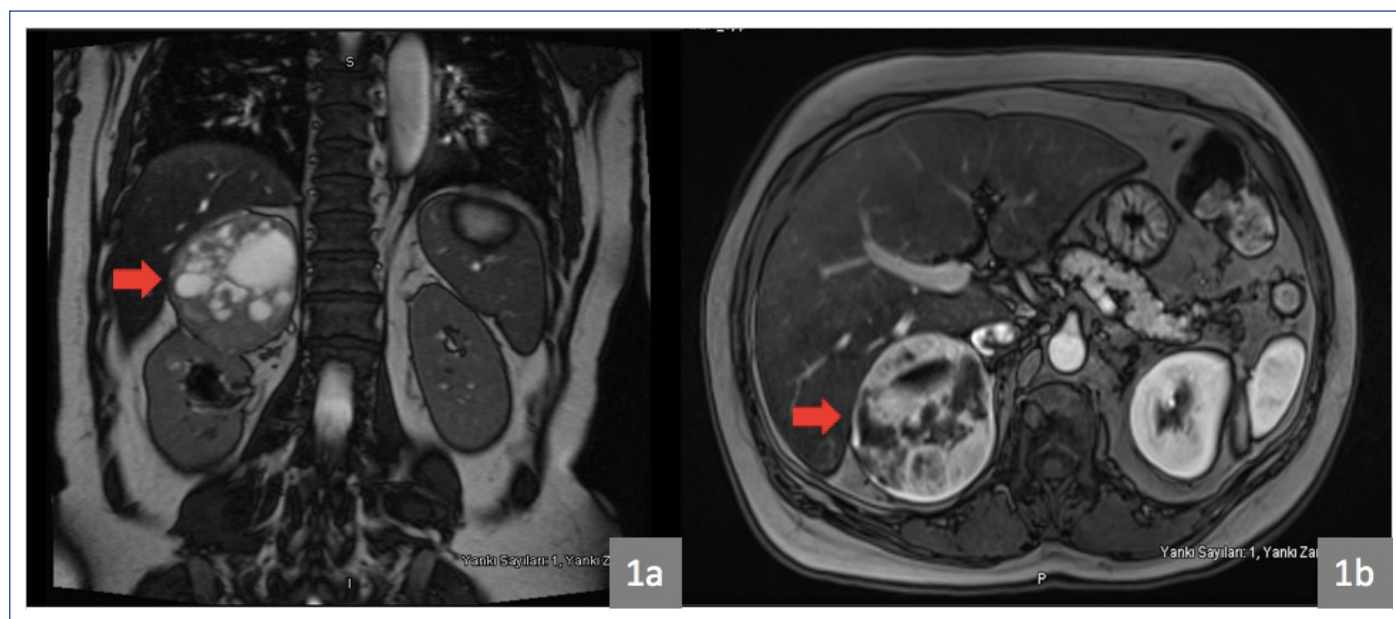

Figure 1. A serious contrast enhancement is observed in the solid areas of the well-circumscribed lesion measuring approximately 75 × 75 × 71 mm, in a heterogeneous structure containing fluid and solid areas suggesting pheochromocytoma. **(a)** Tumor extension to liver and kidney in T2 coronal series on magnetic resonance imaging. **(b)** Appearance of the tumor in T1 transverse series.

smaller than other functional tumors. However, hypertension, associated end-organ damage, and cardiac diseases (such as increased left ventricular thickness and impaired ventricular diastolic function) require caution during the operation.^[7,11]

For the past two decades, laparoscopic approach is accepted as the gold standard in the surgical treatment of adrenal tumors. Furthermore, there are many publications reporting that the robotic approach can be applied safely, hence, there are some conflict sin terms of cost and appropriate indication.^[11] Although the robotic approach has some features such as a more stable camera with 3D view, articulated instruments, and a tremor filtration; the

lack of tactile feedback mechanism may appear to be a disadvantage for hormone active adrenal tumors, especially pheochromocytoma. However, especially with articulated instruments, adrenalectomy was facilitated with the robotic technique.^[12] In our study, regarding the surgical method, the rate of functional tumors was higher in robotic surgery.

The results between the two groups were similar in terms of tumor size, OT, EBL, and LOS. In subgroup analysis of the functional group, LOS was longer patients with Cushing's syndrome because of the required intravenous steroid treatment protocol in post-operative period.

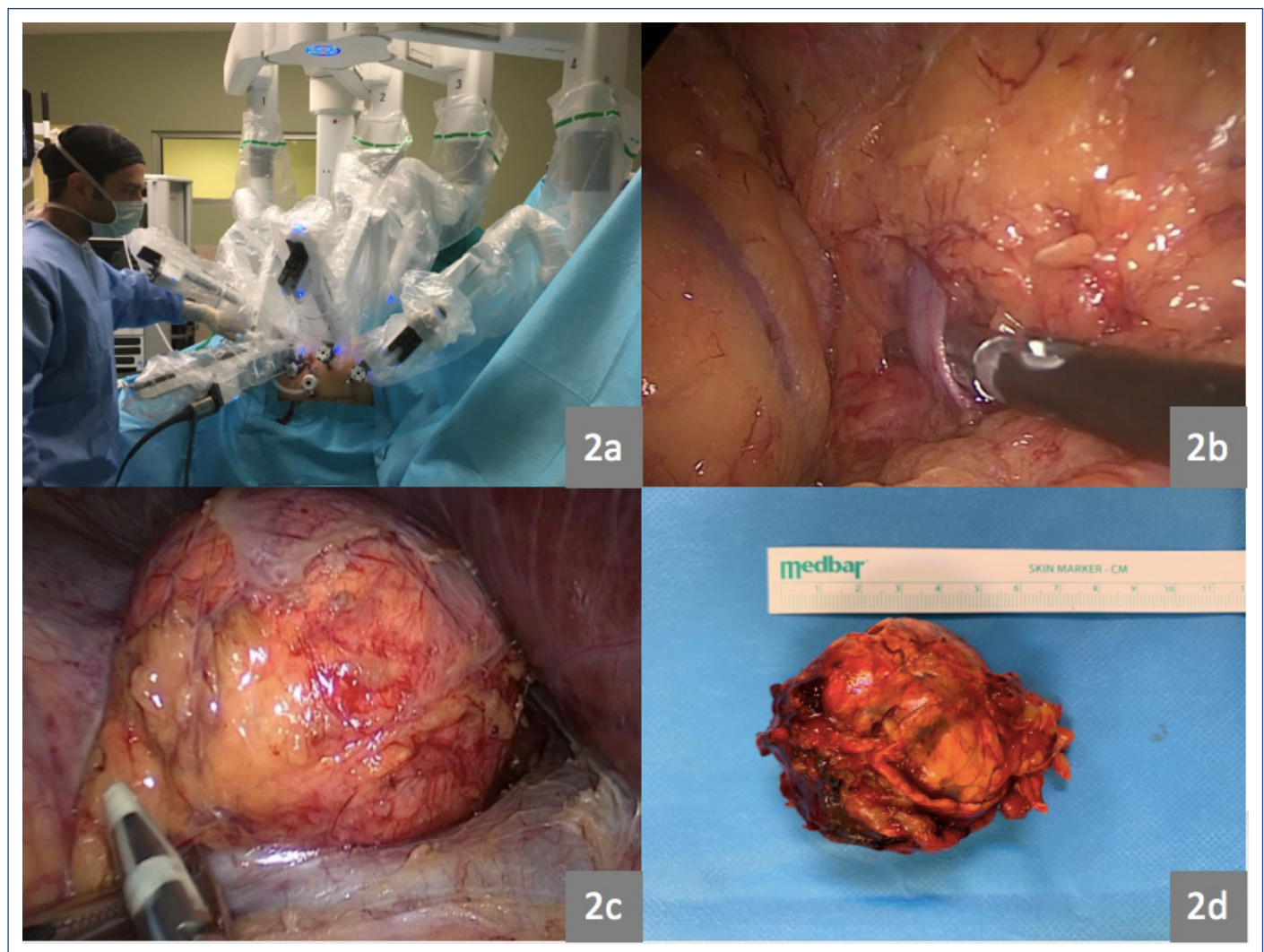


Figure 2. (a) Intraoperative photo demonstrating the 4-arm robotic transabdominal lateral adrenalectomy technique, position of robotic arms after docking. (b) Intraoperative photo showing adrenal vein dissection during laparoscopic left lateral adrenalectomy for Cushing's syndrome. (c) Dissection of the adrenal gland laparoscopic right lateral adrenalectomy for non-functioning adrenal mass. (d) Adrenalectomy specimen approximately 10 cm in size.

Although intraoperative and post-operative complications were higher in the functional group, the difference was not statistically significant. In the literature, complication rates of 2.9%–15.5% have been reported in different studies for adrenalectomy operation, with an average rate of <9%.^[13–16] Since the evaluation of adrenal masses, surgical indication, and the management of complications require a certain experience and a multidisciplinary approach, we think that the treatment of adrenal masses should be done in tertiary reference hospitals.^[17,18]

The high rates of previous abdominal surgeries in both our groups (30% in Group 1 and 37.5% in Group 2) did not constitute a difficulty for the minimally invasive approach. Many studies have demonstrated that previous abdominal surgeries no longer are a contraindication for minimally invasive surgery.^[12,13,19]

One of the limitations of our study is the retrospective design. In addition, the heterogeneity of the groups of the operated patients in terms of operative approach should also be considered as a limitation.

Conclusion

Surgery of functional adrenal tumors involves different perioperative risks depending on the hormone secreted by the tumor. Although randomized controlled studies are needed, it may be recommended to prefer the robotic approach to facilitate manipulation in these masses. Management should be done with a multidisciplinary approach in tertiary care centers with sufficient experience.

Disclosures

Ethics Committee Approval: Ethics committee approval was received from the local ethics committee (No: 2020-5-10 Date: March 2, 2020).

Peer-review: Externally peer-reviewed.

Conflict of Interest: None declared.

Authorship Contributions: Concept and Design – H.A., A.C.D., N.A.S.; Supervision – M.K., D.G.; Materials – S.B., E.B.; Data collection &/or processing – S.B., E.B.; Analysis and/or interpretation – H.A., A.C.D.; Literature search – H.A.; Writing – H.A., A.C.D.; Critical review – M.K., N.A.S.

References

1. Türkiye Endokrinoloji ve Metabolizma Derneği. Adrenal ve gonadal hastalıklar kılavuzu. 2020. 16th ed. Available at: https://temd.org.tr/admin/uploads/tbl_kilavuz/20210104142630-2021tbl_kilavuz72fa0dc2c2.pdf. Accessed Aug 11, 2021.
2. Zeiger MA, Thompson GB, Duh QY, Hamrahian AH, Angelos P, Elaraj D, et al; American Association of Clinical Endocrinologists; American Association of Endocrine Surgeons. American Association of Clinical Endocrinologists and American Association of Endocrine Surgeons medical guidelines for the management of adrenal incidentalomas: executive summary of recommendations. *Endocr Pract* 2009;15:450–3. [\[CrossRef\]](#)
3. Uludağ M, Aygün N, İşgör A. Surgical indications and techniques for adrenalectomy. *Sisli Etfal Hastan Tip Bul* 2020;54:8–22.
4. Kim BY, Chun AR, Kim KJ, Jung CH, Kang SK, Mok JO, et al. Clinical characteristics and metabolic features of patients with adrenal incidentalomas with or without subclinical Cushing's syndrome. *Endocrinol Metab (Seoul)* 2014;29:457–63. [\[CrossRef\]](#)
5. Comlekci A, Yener S, Ertılav S, Secil M, Akinci B, Demir T, et al. Adrenal incidentaloma, clinical, metabolic, follow-up aspects: single centre experience. *Endocrine* 2010;37:40–6. [\[CrossRef\]](#)
6. Stefanidis D, Goldfarb M, Kercher KW, Hope WW, Richardson W, Fanelli RD; Society of Gastrointestinal and Endoscopic Surgeons. SAGES guidelines for minimally invasive treatment of adrenal pathology. *Surg Endosc* 2013;27:3960–80. [\[CrossRef\]](#)
7. Schreiner F, Anand G, Beuschlein F. Perioperative management of endocrine active adrenal tumors. *Exp Clin Endocrinol Diabetes* 2019;127:137–46. [\[CrossRef\]](#)
8. Akarsu C, Dural AC, Kankaya B, Çelik MF, Köneş O, Mert M, et al. The early results of our initial experience with robotic adrenalectomy. *Ulus Cerrahi Derg* 2014;30:28–33. [\[CrossRef\]](#)
9. Sahbaz NA, Dural AC, Akarsu C, Guzey D, Kulus M, Dogansen SC, et al. Transperitoneal laparoscopic surgery in large adrenal masses. *Wideochir Inne Tech Maloinwazyjne* 2020;15:106–11. [\[CrossRef\]](#)
10. Ozdemir M, Dural AC, Sahbaz NA, Akarsu C, Uc C, Sertoz B, et al. Robotic transperitoneal adrenalectomy from inception to ingenuity: the perspective on two high volume endocrine surgery centers. *Gland Surg* 2020;9:815–25. [\[CrossRef\]](#)
11. Pang TC, Bambach C, Monaghan JC, Sidhu SB, Bune A, Delbridge LW, et al. Outcomes of laparoscopic adrenalectomy for hyperaldosteronism. *ANZ J Surg* 2007;77:768–73. [\[CrossRef\]](#)
12. Aliyev S, Karabulut K, Agcaoglu O, Wolf K, Mitchell J, Siperstein A, et al. Robotic versus laparoscopic adrenalectomy for pheochromocytoma. *Ann Surg Oncol* 2013;20:4190–4. [\[CrossRef\]](#)
13. Economopoulos KP, Phitayakorn R, Lubitz CC, Sadow PM, Parangi S, Stephen AE, et al. Should specific patient clinical characteristics discourage adrenal surgeons from performing laparoscopic transperitoneal adrenalectomy? *Surgery* 2016;159:240–8. [\[CrossRef\]](#)
14. Bittner JG 4th, Gershuni VM, Matthews BD, Moley JF, Brunt LM. Risk factors affecting operative approach, conversion, and morbidity for adrenalectomy: a single-institution series of 402 patients. *Surg Endosc* 2013;27:2342–50. [\[CrossRef\]](#)
15. Coste T, Caiazzo R, Torres F, Vantyghem MC, Carnaille B, Do Cao C, et al. Laparoscopic adrenalectomy by

- transabdominal lateral approach: 20 years of experience. *Surg Endosc* 2017;31:2743–51. [\[CrossRef\]](#)
16. Raffaelli M, De Crea C, Bellantone R. Laparoscopic adrenalectomy. *Gland Surg* 2019;8:S41–52. [\[CrossRef\]](#)
17. Kabuli H, Dural AC, Akarsu C, Ünsal MG, Halicioğlu İ, Karakaya P, et al. Effect of multidisciplinary board on the diagnosis and treatment of endocrine diseases. *Journal of Istanbul Faculty of Medicine* 2018;81:25–32. [\[CrossRef\]](#)
18. Dural C, Sahbaz NA, Akarsu C, Guzey D, Aydin H, Kulus M, et al. Transperitoneal Surgery in Adrenal Gland Lesions: Comparison of Robotic and Laparoscopic Methods. Athens, Greece: 16th Panhellenic Congress of Endocrine Surgery with Turkish Participation; Nov 22–24, 2019.
19. Stránský P, Hora M, Eret V, Klecka J, Urge T, Grégrová H, et al. Laparoscopic adrenalectomy. [Article in Czech]. *Rozhl Chir* 2009;88:514–20.