



Original Research

Cranio-Orbital Tumors: Clinical Results and A Surgical Approach

Mustafa Kılıç, Barış Özöner, Levent Aydın, Burak Özdemir, İlhan Yılmaz, Ahmet Murat Müslüman, Adem Yılmaz, Halit Çavuşoğlu, Yunus Aydın

Department of Neurosurgery, Sisli Etfal Training and Research Hospital, Istanbul, Turkey

Abstract

Objectives: In this study, we aimed to share the surgical approaches and clinical experiences of cranio-orbital tumors, which are surgically difficult anatomies.

Methods: A total of 22 orbital tumors with extraorbital-transcranial pathology between January 2004 and December 2017 were retrospectively reviewed. Information was obtained from hospital, operation and outpatient records for this study. Preoperative demographic data, ophthalmologic examination findings, clinical and radiological findings were recorded. All patients had cranial magnetic resonance and cranial computerised tomography examinations at this time. The location of the tumor, its size and its relation to neighboring structures were recorded in the light of these examinations.

Results: The lateral approach was performed in 12 cases. The lateral approach was performed with frontotemporal craniotomy. Because of the lateral inferior location of the tumor in three of 12 cases, zygoma osteotomy was added to classical osteotomy. In 10 cases, the anterior approach was applied and the frontal craniotomy was found sufficient in seven cases. In three cases subfrontal craniotomy was added to classical craniotomy.

Conclusion: The findings obtained in this study suggest that high resection rates can be achieved with appropriate surgical intervention in orbital tumors requiring a transcranial surgical approach. The most important factor in surgical planning is the location of the tumor. The size of the tumor and the expectation of the percentage of surgical removal are the other important factors. In our series, it has reached high excision ratio in most cases with low complication rate, good visual field and eye movements results.

Keywords: Cranio-orbital tumors; proptosis; extraorbital - transcranial approach.

Please cite this article as "Kılıç M, Özöner B, Aydın L, Özdemir B, Yılmaz İ, Müslüman AM, et al. Cranio-Orbital Tumors: Clinical Results and A Surgical Approach. Med Bull Sisli Etfal Hosp 2019;53(3):240–246".

Orbit is an anatomical structure measuring approximately 40 mm in height, 45 mm in depth and up to 30 ml in volume and confined with cranial, facial and nasal. Bones Cranio-orbital tumors can be divided schematically into three groups. Primary lesions originate from structures within the orbit. Secondary lesions are intracranial tumors and paranasal sinuses that extend into the orbit from surrounding structures. The third group is metastatic tumors.^[1]

Orbital tumors can be divided into three categories according to their anatomic location: 1) Intraconal (within the cone of extraocular muscles), 2) extraconal, and 3) intracanalicular (within the optic canal) tumors. This classification

of localization is made according to the cone shape starting from the posterior of the eye globe made by extraocular muscles and ending in the Zinn ring.^[2]

In terms of surgical approach to orbital tumors, three surgical approaches can be applied: 1) Transorbital approaches are generally used for tumors in the anterior part of the orbit.^[3] 2) Extraorbital-transcranial approaches are mostly used for lesions located on the posterior part of the orbit, lateral and superior optic nerve.^[4, 5] 3) Endonasal transcranial approaches can be used for tumors located in the medial part of the orbit.^[6, 7] The extraorbital-transcranial approaches are mainly divided into lateral and anterior

Address for correspondence: Mustafa Kılıç, MD. Sisli Etfal Eğitim ve Arastırma Hastanesi Beyin Cerrahisi Anabilim Dalı, Istanbul, Turkey

Phone: +90 212 373 50 00 **E-mail:** kilicnrs@gmail.com

Submitted Date: April 19, 2018 **Accepted Date:** June 21, 2018 **Available Online Date:** August 27, 2019

©Copyright 2019 by The Medical Bulletin of Sisli Etfal Hospital - Available online at www.sislietfaltip.org

OPEN ACCESS This is an open access article under the CC BY-NC license (<http://creativecommons.org/licenses/by-nc/4.0/>).



approaches.^[5] In the anterior approach, frontal craniotomy and subfrontal approach are used, and in the lateral approach, frontotemporal craniotomy is used and if necessary, osteotomy of zygomatic bone is included.

Methods

Between January 2004 and December 2017, a total of 22 orbital tumors operated by extraorbital - transcranial route were retrospectively reviewed. Information was obtained from hospital, surgical and polyclinic records. Preoperative demographic data, ophthalmologic findings, clinical and radiological findings were recorded. All patients underwent cranial MRI and cranial CT examinations. The location, size and relationship of the tumor with neighboring structures were recorded in the light of these investigations. Frontotemporal craniotomy was performed through lateral approach in 12 cases. In three of twelve cases, osteotomy of the zygomatic bone was added to classical osteotomy because the tumor had a lateral-inferior location. Anterior approach was used in 10 cases.

In seven cases, frontal craniotomy was sufficient and in three cases, subfrontal craniotomy was added to classical craniotomy. Postoperative cranial CT examination and contrast-enhanced cranial MRI examination (to determine the extent of tumor resection) were performed in all cases. Regarding tumor extraction, 22 cases were divided into four groups as total extraction, subtotal extraction (1-3% of the tumor was left), partial extraction and biopsy only. Postoperative follow-up was performed using ophthalmologic tests and pathological results. Control cranial MRI and operation records were compared in the first month and the expected resection rate was compared with the radiological results.

Surgical Technique

In this study, two different approaches were used according to the localization of the tumor in the orbit.

Anterior Approach

In the anterior approach, the bifrontal skin flap is elevated by dissection behind the hairline leaving the periosteal tissue intact with a curvilinear incision starting from 1 cm over the zygomatic arch on the operation side and extending to the temporal muscle on the other side. The periosteal flap was then removed separately. During dissection, the superior rim, medial and lateral walls of the orbit are opened. In the meantime, the supraorbital nerve is dissected over the supraorbital notch so as to protect the nerve. The reason of separate elevation of the periosteal flap is to provide flap tissue with intact blood supply for subsequent skull base reconstruction. A classic frontal craniotomy is then performed. The frontal craniotomy should be extended to the anterior

frontal sinus. Then, dura mater tissue should be dissected from the anterior fossa in skull base, and advanced to the posterior part of the ethmoid bone. The next step is to remove the superior orbital rim and orbital ceiling. For the removal of the orbital rim, suitable holes may be drilled open for the titanium plaques that may need to be placed at the medial and lateral to the points to be dissected during closure to obtain improved cosmetic results. Following removal of the orbital rim, the orbital roof is removed. After this phase, periorbital fascia is encountered.

Destruction of this tissue that arises from some lesions can be observed in this phase. However, in tumors that do not cause tissue destruction or tumors with intraconal location the tumor will come into sight after opening this periorbital fascia. Linear opening of the periorbital fascia in the anteroposterior direction would be appropriate. Extraconal tumors are seen at this stage. After tumor removal, it will be appropriate to re-suture the periorbital fascia to prevent the formation of exophthalmos by advancing the orbital tissues to the cranial area during surgical closure. Afterwards, the fascia lata graft can be used for reconstruction of the orbital roof after fixation of the superior orbital rim. Support can be provided with a previously removed periosteal flap. Titanium plate-screw can be applied on the orbital ceiling in large defects. After closure of the orbital ceiling, fibrin tissue adhesive is applied to the edges of the implanted tissue flap. The dura mater is sealed watertight. The frontal bone is placed in situ, and covered with a skin flap before termination of the operation (Figs. 1, 2).^[4, 5]

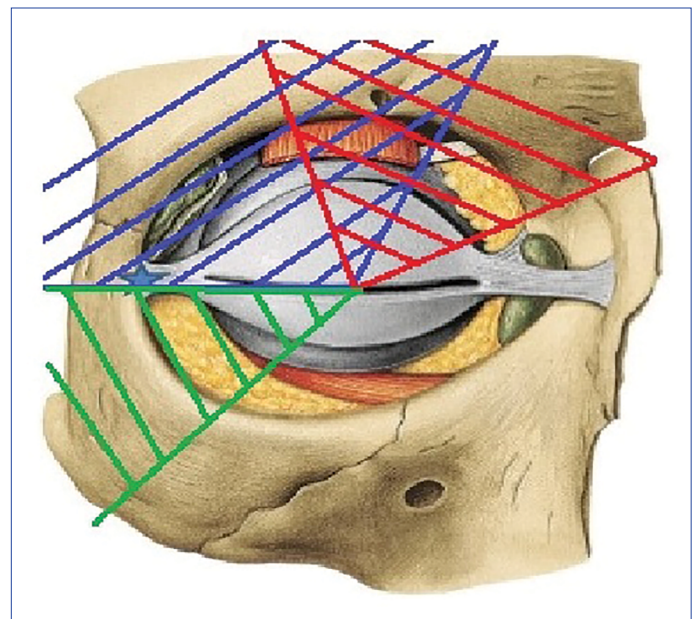


Figure 1. Red Striped Area: Localized lesions suitable for frontal and subfrontal craniotomy. Blue Striped Area: Lesions suitable for frontotemporal craniotomy. Green Striped Area: Lesions to which zygomatic osteotomy was added to the frontotemporal craniotomy.

Lateral Approach

In this approach, a linear skin incision is made behind the hairline, starting from the tragus to the end of the temporal muscle and from there a curvilinear skin incision extending to the midline is performed. In our approach, temporal muscle and skin flap are elevated together to reduce the risk of postoperative muscle atrophy. The skin and muscle flap are elevated forward and the lateral orbital rim is reached. If necessary, the skin incision is extended further on away the inferior part of the zygoma and posterior arch of the zygoma. In spheno-orbital meningiomas after dissection of muscle tissue away from the osseous structure, bone defects or hyperostosis in the lateral wall of the sphenoid bone is encountered. Drilling of this structure can be

performed at this time. Then, a frontotemporal craniotomy is performed. The dura is opened in the form of an arc and removed towards antero-inferior direction. Then, the dissection is advanced towards superior orbital fissure, where dura and surrounding bone tissue are dissected away and lateral and superior part of the orbit is reached. If necessary, the removal of the orbital ceiling is also performed in this phase. Afterwards, periorbital fascia comes into sight. Extraction of the tumor following opening of the periorbital fascia will be possible as described in the previous approach. The principles of closure are the same as the previous approach (Figs.1, 3).^[4, 5]

Results

In our clinic, 22 cases with the diagnosis of orbital tumor consisting of 14 (63.6%) female and 8 (36.4%) male patients were operated through extraorbital approach within 14 years. The age range of the patients was between 18 and 78 (mean 41.2, standard deviation 20.9) years. The most

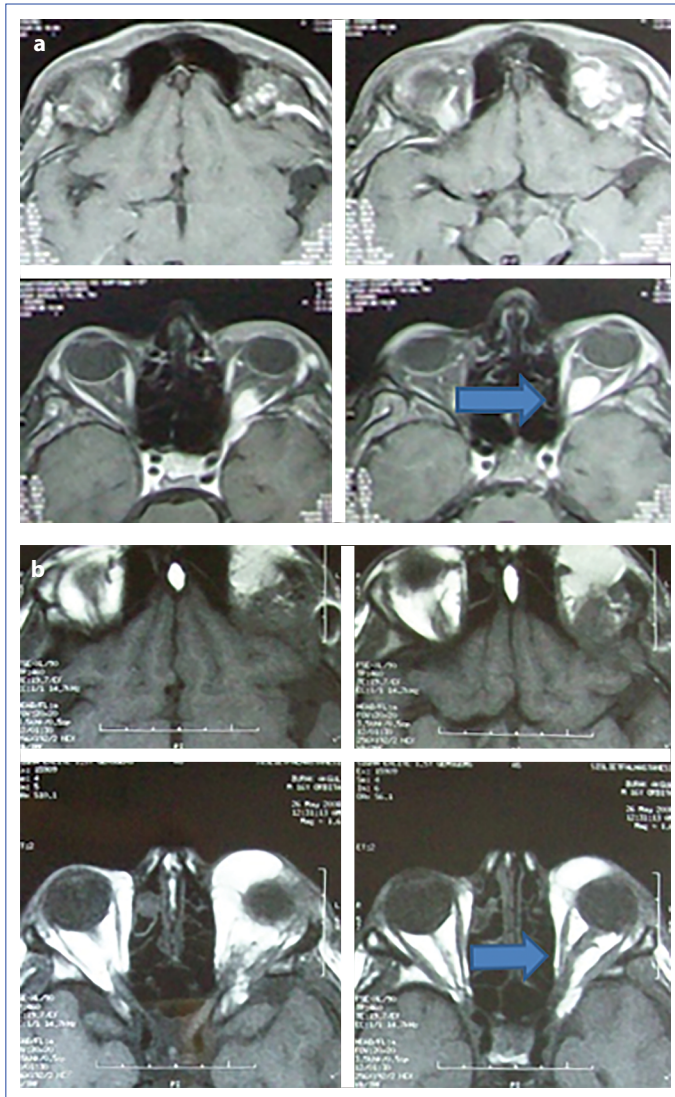


Figure 2. Axial T2-weighted contrast MR imaging revealed a mass compatible with meningioma (a) compressing the right optic nerve from superolateral and inferolateral aspect (a), In axial T2-weighted contrast MR image obtained after right frontotemporal craniotomy and lateral orbitotomy. (b) Complete removal of the mass is seen.

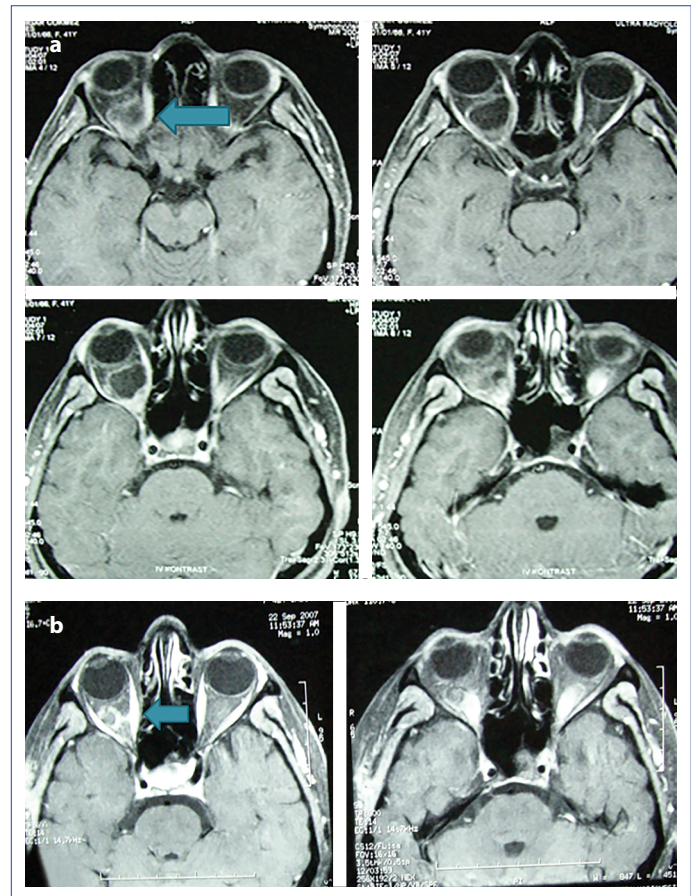


Figure 3. Axial T2-weighted contrast MR imaging shows a mass compatible with cavernous hemangioma compressing the left optic nerve from the superomedial aspect (a), and T2-weighted axial contrast MR image obtained (b) after the left frontal craniotomy revealed complete removal of the mass.

common clinical finding was proptosis (n=10, 45.4%), and the second most common finding was ptosis (n=8, 36.4%) (Table 1). According to the origin of the lesions, 8 (36.4%) primary, 11 (50%) secondary, and 3 (13.6%) metastatic cases were detected. The most common lesions were meningioma in five (22.7%) and cavernous hemangioma in five cases (22.7%) (Table 2).

A total of 17 cases (77.3%) had benign and five cases (22.7%) had malignant tumors (Table 2). Regarding surgical outcomes, total resection was performed in 13 (59.1%), subtotal resection in five (22.7%), partial resection in three (13.6%) and biopsy in only one case (4.5%). There was

no surgical mortality. One patient had diplopia, and exophthalmus of one patient deteriorated following surgery and both patients improved after follow-up. In one case, cerebrospinal fluid (CSF) leakage was observed and stopped by lumbar drainage. Total or subtotal resection was achieved in most of the cases (n=18; 81.8%).

The mean follow-up period was 60.35 ± 25 months, ranging between three and 120 months. During the follow-up, a second surgical intervention was required in three cases. In the follow-up of a meningioma with partial resection, visual field deterioration was detected, and total resection was performed through the previous frontotemporal craniotomy incision and visual improvement was observed (Fig. 4). Tumor resection was achieved in the case of metastasis from invasive ductal carcinoma that had previously undergone subtotal resection and in a case of small cell cancer of the lung using partial resection.

Visual field and ocular movement test results were favourable. The preoperative visual field defect in four patients improved significantly in three patients. New defects were detected in three patients who had no visual field impairment before the operation. During follow-ups, two patients had complete, and one patient had partial improve-

Table 1. Preoperative clinical findings of the patients

Clinical findings	Preoperative
Proptosis	10
Ptosis	8
Diplopia	4
Periorbital pain	4
Headache	4
Chemosis	4
Ocular movement disorder	3
Loss of vision	4

Table 2. Craniotomy types and resection degrees according to pathology results

Pathologic diagnosis	Number of patients (n)	Surgical approach	Resection	Relaps
Meningioma	5	1-FTC +ZO	STR	+
		2-FTC	TR	
		3-FTC	PR	
		4-FTC	PR	
		5-FTC	TR	
Cavernous hemangioma	5	1-FTC	TR	
		2-FC	STR	
		3-FC	TR	
		4-SFC	TR	
		5-FC	TR	
Carcinoma metastasis	3	1-FTC +ZO	STR	+
		2-SFC	PR	
		3-FC	TR	
Osteoma	2	1-FC	TR	
		2-FTC +ZO	TR	
Schwannoma	2	1-FTC	STR	
		2-SFC	TR	
Malignant nerve sheath tumor	1	SFC	Bx	
The frontal sinus induced tumors	1	FC	TR	
Dermoid tumor	1	FTC	TR	
Neurofibroma	1	FTC	TR	
Astrocytoma	1	FTC	STR	

Craniotomy type: FTC: Frontotemporal craniotomy; ZO: Zygoma osteotomy; FC: Frontal craniotomy; SFC: Subfrontal craniotomy; TR: Total resection; STR: Subtotal resection; PR: Partial resection; Bx: Biopsy.

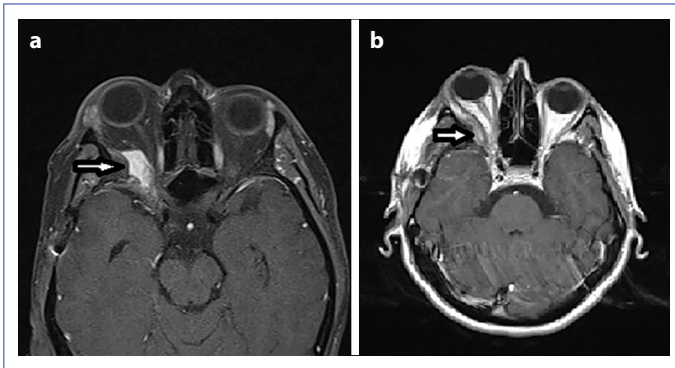


Figure 4. Axial T2-weighted contrast MR imaging demonstrates a mass compatible with dermoid cyst compressing superolateral of aspect the right optic nerve **(a)**, and T2 -weighted axial contrast MR image **(b)** showing partial removal of the mass after right frontotemporal craniotomy.

ment, and one patient had a permanent visual deficit. While diplopia was present in four patients, two patients recovered postoperatively.

In three patients de novo cases of diplopia were seen after the operation, while two of them demonstrated early and one patient delayed remission. Three patients developed ocular movement disturbances secondary to the operation, two of them improved during follow-up and one ocular movement disorder improved in the late period.

Discussion

The most common finding in orbital tumors is proptosis. Although visual loss is often seen later, it may be seen earlier in tumors close to the optic nerve and optic apex.

^[2] Clinical findings vary according to the localization of the tumor. Intraconal tumors compress the optic nerve and extraocular muscles, causing visual impairment and impaired eye movements in the early stage. In advanced phases, intraconal tumors cause axial proptosis. Extraconal tumors give rise to proptosis in the early period. Visual impairment is the advanced stage symptom of these tumors. Intra-canalicular tumors bring about visual loss and papillary edema in the early stage. Proptosis is almost never seen in these tumors.^[2] The most common finding in our series was proptosis at a rate of 45.4% (Table 1).

Primary lesions of orbital tumors are most frequently seen.

^[8, 9] Its incidence was reported as 64% in one study^[8] and as 89% in another study.^[9] In the same series, these incidence rates were 26% and 9% for secondary tumors. In our series, most frequently secondary tumors were seen with a rate of 50%, followed by primary tumors with a rate of 36.4%. The reason for this may be interpreted as the other two series screened for lesions involving the entire orbit, however, in our series, only lesions requiring a transcranial approach

were included in our study.

When the entire orbita is considered, the most common tumor is lymphoid tumors.^[10, 11] In the pediatric group, optic gliomas are the most commonly encountered eye tumors.^[11] According to the anatomical localization of the tumor, lymphoid tumors are most frequently encountered in the extraconal and cavernous hemangioma common in the intraconal location.^[9]

In our series, any lymphoid tumor was not encountered, which may be interpreted given that the lymphoid tumors have an extroconal location, and suitable for transorbital approaches rather than a transcranial approach. In our series, meningioma and cavernous hemangioma were the most frequently observed tumors (22.7%) (Table 2).

In a study involving the entire orbit, 64% of the lesions were benign, and 36% were malignant, and with increasing age, the incidence of lymphoma and metastasis increased to 58%.^[10] However, in another study dealing with the whole orbit, the malignancy rate was 63% in pediatric and 65% in elderly patients.^[8] In our series, more frequently benign tumors were detected and the rate of malignant tumors was only 22.7%.

The anatomical location, size of the tumor and surgical indication are effective in the choice of surgical approach in orbital tumors.^[12] When choosing surgical approach, the approach that is closest to the tumor that may require minimal neural tissue retraction should be preferred. Frontotemporo-zygomatic craniotomy can be used to provide a large surgical exposure. Especially in extradural tumors, frontotemporal craniotomy can be used for minimal neural tissue retraction. In posterior superomedial tumors, frontal and/or subfrontal craniotomy may be preferred regardless of tumor size.^[5, 13]

The use of intraorbital approaches will be effective in lesions localized 1/3 of anterior orbit due to ease of access.^[3] For the lesions localized in 1/3 of posterior to the orbit, a long distance is required with intraorbital approaches. Therefore, extraorbital transcranial approaches will be preferred in cases where the tumor is supereolateral, superomedial and inferolateral in relation to the optic nerve.^[4, 5, 13] If the tumor is located in the medial and inferior part of the the posterior region, transnasal endoscopic approaches would be appropriate.^[6, 7] Transorbital approach to an extraconal tumor localized in the 1/3 middle part of the orbit is suitable,^[3] whereas an extracorbital approach to an intracranial tumor will be appropriate because of the obstruction of the eye globe when transorbital approach is used.^[13]

In our series, localization of the tumor was effective in the selection of extraorbital transcranial approach. In posterior

1/3 tumors, anterior approach was preferred if the tumor was found in supero-medial location and the operation was performed using frontal craniotomy.^[4, 5, 14] If the tumor was located superolaterally or laterally, a lateral approach was preferred and a frontotemporal craniotomy was performed.^[4, 15] Transcranial approach was preferred for the intraconal tumors in the middle 1/3 part if the tumor. Superomedial lesions were operated by frontal craniotomy combined with subfrontal approach with removal of superior orbital rim.^[14] Superolaterally localized lesions were operated by frontotemporal craniotomy and zygomatic osteotomy was added to existing craniotomy for laterally and inferolaterally localized lesions.^[16]

The objective during the surgery of orbital tumors should be to remove as much tumor as possible and to preserve visual acuity and eye movements without damaging functional tissues. From this perspective, total or subtotal removal can be considered as surgical success. This rate was found to be 85% in a series of 41 cases.^[5] In our series, surgical success was consistent with the literature with a rate of 81.8%. When the complications in this study were compared, in the same case series, the patients had transient diplopia (n=2), CSF leakage (n=1) and enophthalmos (n=1).^[5]

In our series, the patients had transient diplopia (n=1), CSF leakage (n=1) and exophthalmos (n=1). In another study, exophthalmos was not seen in any patient who had not this disorder preoperatively.^[17] Although these smaller numbers are not suitable for statistical analysis, it can be said that there is no significant difference regarding complications.

When visual field test results and ocular movement results are compared, the results are favourable. In a study with 38 patients, in terms of visual field loss, no postoperative deterioration was observed and visual field defects in two patients were not reportedly improved.^[17] In our series, the preoperative visual field defects in three of four patients improved significantly. In three patients who did not have visual field impairment before the operation, de novo defects developed. During follow-up period, complete improvement in two and partial improvement in one case were observed. Permanent visual deficit occurred in one case.

Preoperatively diplopia was detected in four cases, and diplopia improved in two in the postoperative period. Three patients developed de novo diplopia postoperatively, while two of them had early and one patient had delayed remission. In the literature, it was emphasized that the rate of visual complications was low and in a series of 41 cases, in only two patients, transient diplopia was detected.^[5] In another series of 38 cases, permanent diplopia was detected in one patient who had not diplopia preoperatively.^[17]

Ocular movement disorder was resolved in two of three patients. Three patients had ocular movement disturbances due to the operation. In two of them ocular movement disorder improved during the follow-up period and one patient had late recovery. No permanent ocular loss was found in two studies.^[5, 17]

In our study, partial or complete improvement was achieved in three of four patients who had lost their vision before surgery. As a result of the operations performed, one patient had permanent vision loss. There was no permanent diplopia developed due to surgery. However, in two of four patients, preoperative diplopia was resolved after the operation. Permanent ocular movement disorder was observed in one patient due to surgery, and two of the three cases with preoperative ocular movement disorder improved after surgery. In our study with high resection rate, these numbers are considered to be within acceptable limits.

Conclusion

In orbital tumors that require transcranial surgical approach, high resection rates can be achieved by choosing an appropriate surgical intervention. Although the most important factor in surgical planning is the location of the tumor, the size of the tumor and the expectation on the percentage of surgical removal are other important factors. In our series, high excision rate was achieved in most cases with low complication rates, improved vision and normal eye movements.

Disclosures

Peer-review: Externally peer-reviewed.

Conflict of Interest: None declared.

Authorship Contributions: Concept – M.K.; Design – B.Özöner; Supervision – A.Y.; Materials – L.A.; Data collection &/or processing – L.A.; Analysis and/or interpretation – A.M.M., H.Ç.; Literature search – B.Ö.; Writing – M.K.; Critical review – Y.A.

References

1. Darsaut TE, Lanzino G, Lopes MB, Newman S. An introductory overview of orbital tumors. *Neurosurg Focus* 2001;10:E1. [\[CrossRef\]](#)
2. Winn HR, Youmans JR. *Youmans Neurological Surgery*. 5th ed. W B Saunders; 2004.
3. Cockerham KP, Bejjani GK, Kennerdell JS, Maroon JC. Surgery for orbital tumors. Part II: transorbital approaches. *Neurosurg Focus* 2001;10:E3. [\[CrossRef\]](#)
4. Bejjani GK, Cockerham KP, Kennerdel JS, Maroon JC. A reappraisal of surgery for orbital tumors. Part I: extraorbital approaches. *Neurosurg Focus* 2001;10:E2. [\[CrossRef\]](#)
5. Margalit N, Ezer H, Fliss DM, Naftaliev E, Nossek E, Kesler A. Orbital tumors treated using transcranial approaches: surgical technique

- and neuroophthalmological results in 41 patients. *Neurosurg Focus* 2007;23:E11. [\[CrossRef\]](#)
6. Abuzayed B, Tanriover N, Gazioglu N, Eraslan BS, Akar Z. Endoscopic endonasal approach to the orbital apex and medial orbital wall: anatomic study and clinical applications. *J Craniofac Surg* 2009;20:1594–600. [\[CrossRef\]](#)
 7. McKinney KA, Snyderman CH, Carrau RL, Germanwala AV, Prevedello DM, Stefkó ST, et al. Seeing the light: endoscopic endonasal intraconal orbital tumor surgery. *Otolaryngol Head Neck Surg* 2010;143:699–701. [\[CrossRef\]](#)
 8. Shinder R, Al-Zubidi N, Esmali B. Survey of orbital tumors at a comprehensive cancer center in the United States. *Head Neck* 2011;33:610–4. [\[CrossRef\]](#)
 9. Ohtsuka K, Hashimoto M, Suzuki Y. A review of 244 orbital tumors in Japanese patients during a 21-year period: origins and locations. *Jpn J Ophthalmol* 2005;49:49–55. [\[CrossRef\]](#)
 10. Shields JA, Shields CL, Scartozzi R. Survey of 1264 patients with orbital tumors and simulating lesions: The 2002 Montgomery Lecture, part 1. *Ophthalmology* 2004;111:997–1008. [\[CrossRef\]](#)
 11. Johansen S, Heegaard S, Bøgeskov L, Prause JU. Orbital space-occupying lesions in Denmark 1974-1997. *Acta Ophthalmol Scand* 2000;78:547–52. [\[CrossRef\]](#)
 12. Maroon JC, Kennerdell JS. Surgical approaches to the orbit. Indications and techniques. *J Neurosurg* 1984;60:1226–35. [\[CrossRef\]](#)
 13. Srinivasan A, Bilyk JR. Transcranial Approaches to the Orbit. *Int Ophthalmol Clin* 2018;58:101–10. [\[CrossRef\]](#)
 14. Troude L, Bernard F, Roche PH. The medial orbito-frontal approach for orbital tumors: a How I Do It. *Acta Neurochir (Wien)* 2017;159:2223–7. [\[CrossRef\]](#)
 15. Liu Y, Ma JR, Xu XL. Transcranial surgery through pterional approach for removal of cranio-orbital tumors by an interdisciplinary team of neurosurgeons and ophthalmologists. *Int J Ophthalmol* 2012;5:212–6.
 16. McDermott MW, Durity FA, Rootman J, Woodhurst WB. Combined frontotemporal-orbitozygomatic approach for tumors of the sphenoid wing and orbit. *Neurosurgery* 1990;26:107–16. [\[CrossRef\]](#)
 17. Gao D, Fei Z, Jiang X, Zhang X, Liu W, Fu L, et al. The microsurgical treatment of cranio-orbital tumors assisted by intraoperative electrophysiologic monitoring and neuronavigation. *Clin Neurol Neurosurg* 2012;114:891–6. [\[CrossRef\]](#)