

Sclerosing Stromal Tumor of the Ovary in a Postmenopausal Woman: Case Report

Seyhan Ozakkoyunlu Hascicek¹, Ahu Gulcin Sari¹, Fevziye Kabukcuoglu¹

ABSTRACT:

Sclerosing stromal tumor of the ovary in a postmenopausal woman: case report

Objective: Sclerosing stromal tumor of the ovary (SST) is a rare neoplasm of the sex cord stromal category. We present a case of a unilateral SST of the ovary in a 54-year-old woman with abdominal swelling and describe the clinical and histological findings with reference to other reported cases.

Case: Histopathologically, the lesion was characterized by a pseudolobular pattern of the edematous stroma containing focal sclerosis areas, a heterogeneous cell population and marked vascularization.

Conclusion: Ovary sclerosing stromal tumor is most commonly seen in the 2nd and 3rd decades, but it should be kept in mind that it may also be seen in postmenopausal patients.

Keywords: Benign, ovary, sclerosing stromal tumor

ÖZET:

Postmenopozal kadın hastada overde sklerozan stromal tümör: Olgu sunumu

Amaç: Overin sklerozan stromal tümörü, over tümörleri içinde oldukça nadir, benign karakterli en sık 2.-3. dekatta görülen bir tümördür. 54 yaşında karında şişlik şikayetiyle başvuran, uni-lateral overin sklerozan tümörü tanısı alan olguya ait klinik, histopatolojik ve immunohistokimyasal bulgular literatür eşliğinde sunulmuştur.

Olgu: Histopatolojik olarak fokal skleroz alanları içeren ödemli stromanın oluşturduğu psödolobüler görünüm, heterojen hücre popülasyonu ve belirgin vaskülarizasyon ile karakterize lezyon izlendi.

Sonuç: Overin sklerozan stromal tümörü, en sık 2.-3. dekatta görülür ancak postmenopozal hastalarda da rastlanılabileceği akılda tutulmalıdır.

Anahtar kelimeler: Benign, over, sklerozan stromal tümör

Ş.E.E.A.H. Tıp Bülteni 2017;51(2):161-4



¹Sisli Hamidiye Etfal Training and Research Hospital, Department of Medical Pathology, Istanbul - Turkey

Yazışma Adresi / Address reprint requests to: Seyhan Ozakkoyunlu Hascicek, Sisli Hamidiye Etfal Training and Research Hospital, Department of Medical Pathology, Istanbul - Turkey

E-posta / E-mail: shascicek@gmail.com

Geliş tarihi / Date of receipt: April 20, 2016 / 20 Nisan 2016

Kabul tarihi / Date of acceptance: June 7, 2016 / 7 Haziran 2016

INTRODUCTION

Sclerosing stromal tumor (SST) is a rare ovarian tumor of the sex cord stromal tumors category. It was defined as a different entity between sex cord stromal tumors by Chalvard and Scully in 1973 (1). Ovarian sclerosing stromal tumor is most commonly seen in the 2nd-3rd decades (2). The nonspecific symptoms associated with the adnexal mass and menstrual irregularities are the most common complaints. They generally show unilateral and solid development (3-5). Sclerosing stromal tumor is a benign neoplasm and diagnosed by postoperative pathological examination.

CASE REPORT

A mass was found in the right lower quadrant of the abdomen in a 54-year-old woman who presented to the obstetrics and gynecology outpatient clinic with a complaint of abdominal swelling. Serum hormone levels and tumor markers were within normal limits. Magnetic resonance imaging (MRI) of the abdomen revealed a mass of 214x188 mm associated with the uterine fundus, completely filling the lower right quadrant, with fine borders, and capsule-like appearance, and myometrium-like contrast enhancement. Total abdominal hysterectomy

and bilateral salpingo-oophorectomy were planned and the right ovary was sent for intraoperative frozen section evaluation. Macroscopic examination revealed a tumoral lesion which was right ovary-localized, with 24 cm diameter, uniformly bordered, cream-yellow coloured, including point bleeding areas, and involving occasional lobulations. Frozen section reported the mass as a stromal tumor. Paraffin sections showed a pseudolobular development pattern of cellular areas, separated by hypocellular, edematous and collagenous connective tissue and a high number of hemangiopericytoma-like proliferation of thin-walled vascular structures with several of them branched, in microscopic small

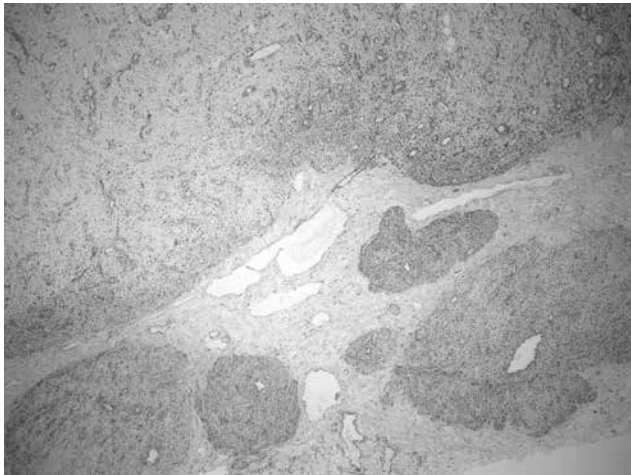


Figure-1: x4 Pseudolobular development pattern

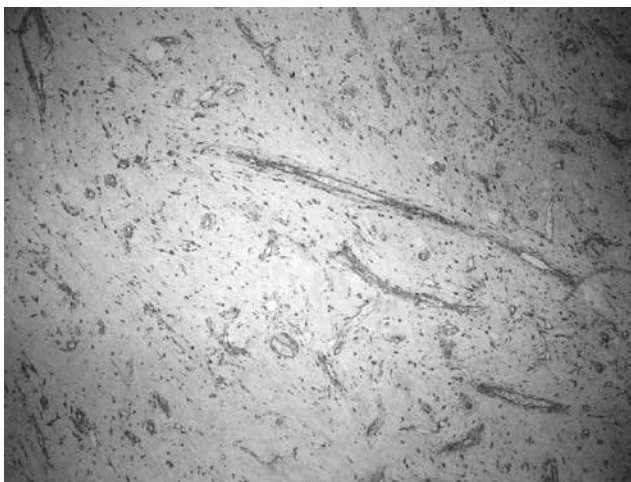

Figure-2: x10 Hemangioperistoma-like vascular proliferation

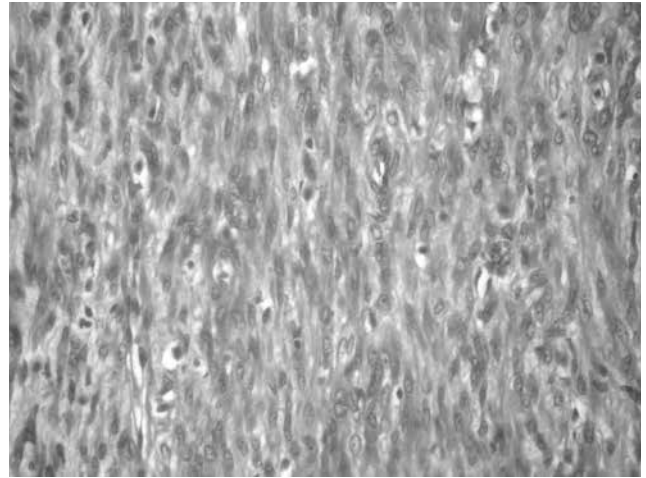


Figure-3: x40 Proliferation of cells with clear cytoplasm, vesicular nuclei and prominent nucleoli

enlargement (Figure-1,2). At large enlargement, proliferation of large cells with clear cytoplasm, vesicular nucleus, prominent nucleoli were observed, as well as spindle cells in cellular areas (Figure-3). Cytological atypia and necrosis were not observed. Signet-ring cell-like large cells with clear cytoplasm drew attention. Immunohistochemical study showed staining with vimentin, desmin, smooth muscle actin (SMA), estrogen and progesterone receptors (ER, PR), but no staining with pan-cytokeratin, calretinin and α inhibin. A 'sclerosing stromal tumor' was diagnosed with the present histomorphological findings.

CONCLUSION

Sclerosing stromal tumor (SST) constitutes 6% of ovarian stromal tumors (5). 80% of cases with SST diagnosis are in 2nd and 3rd decade. It is rare in postmenopausal patients. There are patients in the literature who are diagnosed as 'SST' in the 6th and 8th decades (1,6). Sclerosing stromal tumor cases present with menstrual irregularity, abdominal swelling and abdominal pain. Postmenopausal cases can be detected only when the mass reaches to large sizes and is palpated, and causes abdominal pain. A diagnosis of 'SST' is necessary in cases where the ultrasonographic examination suggests ovarian malignancy, cystic-solid component is observed

together and there is significant vascularity around the lesion in Doppler ultrasonographic examination (3). Especially in premenopausal patients, SST diagnosis is important in order to protect the contralateral ovary. Malignant SST cases have not been reported in the literature (7-9).

Pseudolobular development pattern, cellular areas separated by hypocellular, edematous and collagenous cell-poor areas, hemangiopericytoma-like vascular growth pattern and heterogeneous cell population are characterized for SST (7). Vascular, sclerotic, edematous stromal changes are associated with local elevation of vascular permeability factor and vascular endothelial growth factor (3,10).

In the differential diagnosis of sclerosing stromal tumors, other sex cord stromal tumors, such as fibroma-thecoma, vascular tumors, metastatic Signet-ring cell carcinoma, metastatic breast carcinoma and massive ovarian edema have to be considered. Fibrom is generally seen over 50 years of age. Morphology shows extensive hyalinized plaques, crossed fascicles and spindle cell proliferation which forms a storiform pattern. Pseudolobular development pattern and distinctive vascular framework are not seen. Thecoma is a tumoral lesion formed by spindle and luteinized cells, which can exhibit significant lobular growth pattern, usually seen in the postmenopausal period. There is no obvious vascular proliferation. Calretinin, α -inhibin, CD34 and α -glutathione-S-transferase (α -GST) are useful immunohistochemical markers for differentiating sclerosing stromal tumor. Staining is observed in all sex cord stromal tumors with calretinin and α -inhibin, while diffuse staining with α -GST is observed in thecoma. In fibroma, no staining is observed. Focal stained with α -GST may be seen in SST (11,12). Staining in vascular endothelium is present with CD34 in SST. It is

necessary to exclude metastatic Signet-ring cell carcinoma due to Signet-ring cell-like luteinized cells. While mucin accumulation is present in the cytoplasm of the Signet-ring cells, cytoplasmic staining with EMA and pancytokeratin is observed. If the luteinized cells are arranged to form cords, it is necessary to take metastatic breast carcinoma for differential diagnosis and it should be kept in mind that positive staining with ER - PR in both lesions may be present. In cases where the vascular framework is prominent, differentiation from vascular tumors may become necessary. Morphological findings, staining with calretinin and α -inhibin are helpful in diagnosing sclerosing stromal tumor. Massive edema is a non-neoplastic pathology seen in the ovary. It is important that the lesion is not heterogeneous and ovarian tissues preserved throughout the edematous stroma in differentiation of sclerosing stromal tumor.

In this case immunohistochemical study showed staining with vimentin, desmin, SMA, ER and PR, but no staining with calretinin and α -inhibin. Calretinin and α -inhibin are valuable predictors of ovarian sex cord stromal tumor, correlation was reported between the luteinization levels of tumor cells with calretinin and α -inhibin expressions (11,13). In the literature, sclerosing stromal tumor cases without α -inhibin staining have been reported (2,14). Staining with ER and PR is seen in sclerosing stromal tumors (5,15,16). Although variabilities in immunohistochemical analyzes were presented in SST, vimentin, SMA, desmin and positive staining support the diagnosis of sclerosing stromal tumors.

Although sclerosing stromal tumor is very rare in sex cord stromal tumors, it should be kept in mind that it may also be seen in postmenopausal cases with its characteristic macroscopic and histopathologic appearance.

REFERENCES

1. Chalvardjian A, Scully RE. Sclerosing stromal tumors of the ovary. *Cancer* 1973; 31: 664-70. [CrossRef]
2. Qureshi A, Raza A, Kayani N. The morphologic and immunohistochemical spectrum of 16 cases of sclerosing stromal tumor of the ovary. *Indian J Pathol Microbiol* 2010; 53: 658-60. [CrossRef]
3. Kawauchi S, Tsuji T, Kaku T, Kamura T, Nakano H, Tsuneyoshi M. Sclerosing stromal tumor of the ovary: A clinicopathologic, immunohistochemical, ultrastructural and cytogenetic analysis with special reference to its vasculature. *Am J Surg Pathol* 1998; 22: 83-92. [CrossRef]

4. Kuscü C, Oktem M, Karahan H, Bilezikci B, Demirhan B. Sclerosing stromal tumor of the ovary: a case report. *Eur J Gynaecol Oncol* 2003; 24: 442-4.
5. Kaygusuz El, Cesur S, Cetiner H, Yavuz H, Koc N. Sclerosing stromal tumour in young women: clinicopathologic and immunohistochemical spectrum. *J Clin Diagn Res* 2013; 7: 1932-5.
6. Kim TH, Lee HH, Hong JA, Park J, Jeon DS, Lee A, et al. Sclerosing stromal tumor in an elderly postmenopausal woman. *J Menopausal Med* 2014; 20: 80-3. [CrossRef]
7. Akyildiz EU, Ilvan S, Calay Z, Oktar H. Sclerosing stromal tumor of the ovary: Report of three cases. *J BUON* 2004; 9: 205-7.
8. Pai RR, Shaktawat SS, Khadilkar UN, Lobo FD, Rao VS, Philipose R. Sclerosing stromal tumour of the ovary – a clinico-pathologic spectrum. *Indian J Pathol Microbiol* 2005; 48: 370-2.
9. Mathur SR, Dahiya S, Nayak A, Bhatla N, Singh MK. Sclerosing stromal tumour of ovary- a clinicopathological and immunohistochemical study of five cases. *Indian J Pathol Microbiol* 2004; 47: 333-5.
10. Atram M, Anushu, Sharma S, Gangane N. Sclerosing stromal tumor of the ovary. *Obstet Gynecol Sci* 2014; 57: 405-8. [CrossRef]
11. Özdemir Ö, Sarı ME, Şen E, Kurt A, İleri AB, Atalay CR. Sclerosing stromal tumour of the ovary: A case report and the review of literature. *Niger Med J* 2014; 55: 432-7. [CrossRef]
12. Khanna M, Khanna A, Manjari M. Sclerosing stromal tumor of ovary: A case report. *Case Rep Pathol* 2012; 2012: 592836. [CrossRef]
13. Zekioglu O, Ozdemir N, Terek C, Ozsaran A, Dikmen Y. Clinicopathological and immunohistochemical analysis of sclerosing stromal tumours of the ovary. *Arch Gynecol Obstet* 2010; 282: 671-6. [CrossRef]
14. Kommoss F, Oliva E, Bhan AK, Young RH, Scully RE. Inhibin expression in ovarian tumors and tumor-like lesions: an immunohistochemical study. *Mod Pathol* 1998; 11: 656-64.
15. Lifschitz-Mercer B, Open M, Kushnir I, Jacob N, Caspi B, Czernobilsky B. Hyaline globules and progesterone receptors in an ovarian sclerosing stromal tumor. *Histopathology* 1995; 27: 195-7. [CrossRef]
16. Kostopoulou E, Moulla A, Giakoustidis D, Leontsini M. Sclerosing stromal tumors of the ovary: a clinicopathologic, immunohistochemical and cytogenetic analysis of three cases. *Eur J Gynaecol Oncol* 2004; 25: 257-60.