

Neuromyelitis Optica: Case Report

Nurgul Gurgen¹, Destina Yalcin¹, Salim Taner Gozukizil¹, Deniz Polisci¹

ABSTRACT:

Neuromyelitis optica: case report

Objective: Neuromyelitis optica or Devic's disease is a rare inflammatory demyelinating autoimmune disease of the central nervous system which affects the spinal cord and optic nerves and usually associated with increased disability and morbidity. The purpose of this case report is to present this rare disease and focus on the diagnosis criteria.

Case: A 63-year-old female patient defining visual loss 4 months ago and admitted to our clinic with prominent quadriparesis of the upper extremities was evaluated with examination, laboratory findings, and MRI and diagnosed with neuromyelitis optica.

Result: The case which was diagnosed according to the new and old criteria with detected previous optic neuritis, transverse myelitis and particularly aquaporin 4 positivity and its differential diagnosis were discussed in the light of the literature.

Keywords: Devic's disease, neuromyelitis optica, transverse myelopathy

ÖZET:

Nöromiyelitis optika: Olgu sunumu

Amaç: Nöromiyelitis optika ya da Devic hastalığı optik sinirler ve omuriliği tutan, nadir görülen, genellikle ağır sekillerle seyreden enflamatuar ve demiyelinizan natürde santral sinir sisteminin otoimmün bir hastalığıdır. Sunumun amacı nadir görülen bu hastalığı ve tanı kriterlerini gözden geçirmektir.

Olgu: Özgeçmişinde dört ay önce görme kaybı tanımlayan ve üst ekstremitelerde belirgin kuadriparezi tablosuyla kliniğimize başvuran 63 yaşındaki hasta muayene, laboratuvar bulguları ve manyetik rezonans görüntüleri ile değerlendirilmiş ve nöromiyelitis optika tanısı almıştır.

Sonuç: Geçirilmiş optik nörit, transvers miyelit ve özellikle aquaporin 4 pozitifliği saptanarak yeni ve eski kriterlere göre tanı alan olgu ve ayırıcı tanısı literatür ışığında tartışılmıştır.

Anahtar kelimeler: Devic hastalığı, nöromiyelitis optika, transvers miyelopati

Ş.E.E.A.H. Tıp Bülteni 2016;50(2):166-70



¹Umraniye Training and Research Hospital, Department of Neurology, Istanbul - Turkey

Address reprint requests to / Yazışma Adresi: Destina Yalcin, Umraniye Training and Research Hospital, Department of Neurology, Istanbul - Turkey

E-mail / E-posta: destinayalcin@yahoo.com

Date of receipt / Geliş tarihi: June 22, 2015 / 22 Haziran 2015

Date of acceptance / Kabul tarihi: August 6, 2015 / 6 Ağustos 2015

INTRODUCTION

The term Neuromyelitis optica (NMO) have been proposed for the first time in 1894 by Gault and Devic, for the disease that involves simultaneously bilateral optic nerves and the spinal cord (1). For nearly a hundred years, it was accepted as a subtype of multiple sclerosis (MS) and considered as a monophasic disease. With the recent studies, MS and NMO have been proven to be different entities (2). While MS causes lesions that do not exceed the length of one vertebral corpus in the spinal cord, in NMO, the lesions involve at least 3 segments, and may include also cavitations (3). NMO attacks generally heal with severe sequalee. In NMO, the

cranial MRI is usually normal. The cranial MRI lesions, which may rarely be seen do not meet the MS criteria. In NMO, oligoclonal bands are usually not detected at cerebrospinal fluid (CSF) and IgG index is negative. The most important laboratory finding is aquaporin-4-IgG (AQP4-IgG) antibody positivity (4). The antibodies are developed against a water channel molecule called aquaporin-4 (5). The sensitivity of these antibodies is quite high and they are diagnostic for NMO (6).

CASE

Sixty-three-year-old female patient admitted with numbness at upper and lower extremities, pain and

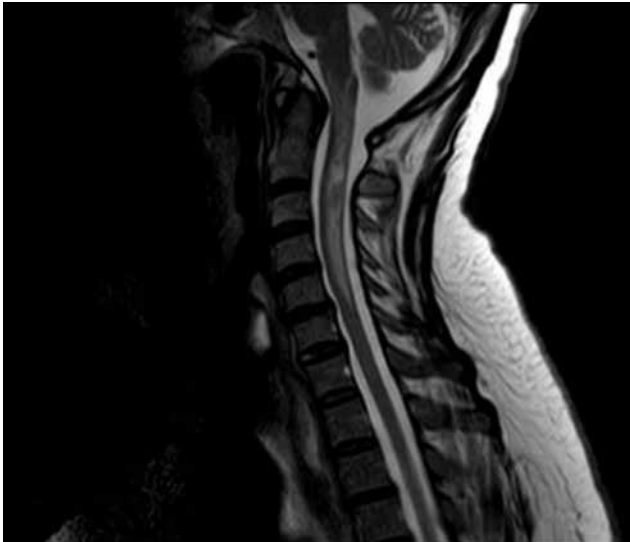


Figure-1: T1-hypointense and T2-hyperintense lesion extending from C1 to C4, with a cystic component all through the segment, expanding the spinal cord

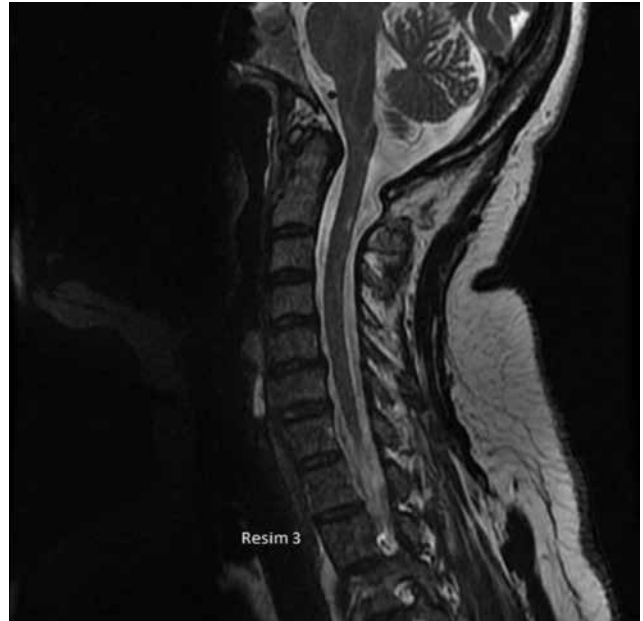

Figure-3: Almost full recovery in the repeated cervical MRI 3 months later

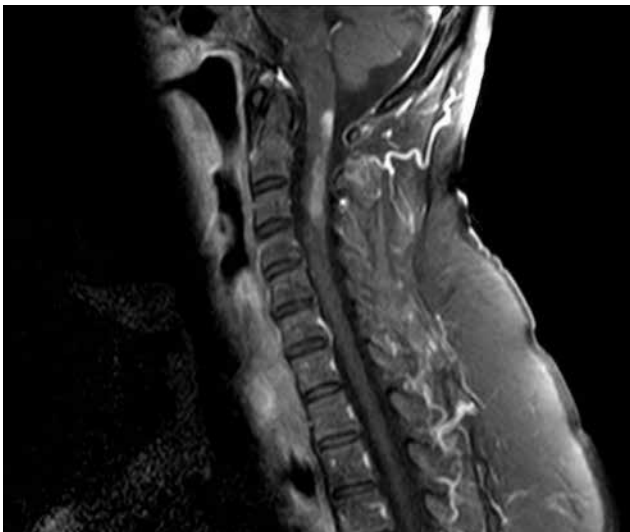


Figure-2: The contrast-enhanced state of the lesion that extends from C1 to C4

loss of power that began 15 days ago. In the neurological examination, the patient was fully awake, conscious and oriented. The cranial area was intact. In the motor examination, muscle strength was detected as 4/5 with being prominent at the right side and at upper extremities. The deep tendon reflexes were normoactive at the upper extremities, and hypoactive at the lower extremities, with bilateral extensor plantar reflexes. Although the

patient defined numbness at her arms and legs, objective sensory defects have not been detected. She didn't describe a sphincter defect. In her history, she admitted to the ophthalmology clinic for visual impairment at her right eye 4 months ago and the orbital MRI which was performed there revealed edema, thickening and contrast enhancement at the intracanalicular level. In the cervical MRI, a contrast enhanced T1-hypointense and T2-hyperintense (Figure-1) demyelinating area extending from C1 to C4, with a cystic component all through the segment, expanding the spinal cord was observed (Figure-2). The cranial MRI examination was normal. The cerebrospinal fluid (CSF) analysis revealed 5 leucocytes, protein levels of 37.5 mg/dl, and glucose levels of 56 mg/dl, with no atypical cells detected. No oligoclonal bands were detected, IgG index was negative. The blood examinations of complete blood count, liver, kidney and thyroid function tests, fasting blood glucose, electrolytes; sodium, potassium, calcium, ionized calcium, phosphorus, magnesium, erythrocyte sedimentation rate, C-reactive protein and vitamin B12 levels were normal. The vasculitis and paraneoplastic markers were detected as negative. AQP4-IgG antibody which was requested

from an outer center was found to be positive. In VEP examination, P100 latency was recorded bilateral long, prominent on the right side. With the clinical and laboratory findings, the patient was diagnosed with NMO according to the diagnostic criteria which were revised in 2006 and 2015, and 1 gr/day IV methylprednisolone was administered for 7 days. On the 6th week of the disease, the second cervical contrast-enhanced MRI revealed decreased contrast enhancement, but the length of the lesion remained the same. A mild improvement at the muscle strength of the patient was observed after the treatment, and she was discharged. Two months later the neurological findings of the patient did not change; however, the lesion disappeared almost completely at the cervical MRI (Figure-3). Azathioprine maintenance therapy was initiated and 1 gr pulse methylprednisolone/month for 6 months was continued until the effective dose was reached. The patient is still under follow-up with azathioprine treatment, and no attacks repeated.

DISCUSSION

Hydromyelia, demyelinating disease, infectious causes, tumor, vitamin B12 deficiency and metabolic disorders were suspected in the differential diagnosis of our patient who applied with transverse myelopathy findings. The CSF examination was negative in terms of infection and malignancy. Levels of vitamin B12 were normal. The history of our patient revealed no feature of possible MS attack, the cranial MRI was normal. In terms of collagenosis, both the anamnesis of the patient was unremarkable, and all the markers of collagenosis were found as negative. Transverse myelopathy, the optic nerve involvement in her past history, the spinal cord lesion including more than 3 segments at the cervical MRI, and the AQP4-IgG antibody positivity, were all compatible with the Diagnosis of NMO.

NMO is an inflammatory, demyelinating disease that primarily involves the spinal cord and the optic nerves in the nervous system. The ocular involvement may include optic neuritis or retrobulbar neuritis. Spinal cord involvement includes transverse myelopathy presented as sensory loss below the

lesion, motor power loss and sphincter defects (2).

Clifford Albutt first drew attention to the association of optic neuritis and spinal cord involvement in 1870 and later Eugene Devic and his student Fernand Gault suggested the term neuromyelitis optica in 1894 by presenting cases that developed simultaneously bilateral optic neuritis and myelitis attacks (2). NMO is accepted as a subtype of MS for about hundred years and thought to be a monophasic disease (3). Primarily two main course types were defined for NMO; in the first type, optic neuritis and transverse myelitis attacks occur with close intervals or simultaneously; in the second type, there are long intervals such as months or years between the attacks (2). In addition, 20% of the patients is monophasic, in 80%, its course shows relapses. While 60% of the patients experience their second attacks in the first year following the first attack, this rate reaches to 90% at the end of the first 3 years. In our case, there were 4 months between the optic nerve involvement and the transverse myelitis.

In 1999, a group of researchers in USA suggested some criteria to be used in the diagnosis of NMO and in 2006, these criterias were developed and organized as follows: The definitive criteria are: 1. Optic neuritis, 2. Transverse myelitis and two of the following: 1. A large lesion that exceeds 3 spinal cord segments; 2. Cranial MRI examination to be atypical for MS, 3. AQP4-IgG positivity. The cases that do not fully fill these criteria are defined as the NMO spectrum disorders (NMOSD) (7,8). In the year 2015, these criteria were revised again and NMO and the spectrum disorders were accepted as a single entity, and named as NMOSD. According to the new criteria, for cases with AQP4- IgG positivity, one main clinical finding is enough for the definitive diagnosis, the other possible diagnoses must be excluded. The main clinical findings are: 1. Optic neuritis 2. Acute myelitis 3. Area postrema syndrome 4. Acute brainstem syndrome 5. Symptomatic narcolepsy or acute diencephalic clinical syndrome 6. Symptomatic cerebral syndrome that includes typical brain lesions for NMOSD (9). Our case was fulfilling the old and revised new diagnostic criteria.

In some NMO cases, there may be some brain lesions that may not be typical for MS. These are

large, atypical lesions especially located in the hypothalamus, brainstem or cerebral convexity (10). In some brain lesions, there may be some imaging findings suggestive of vasogenic edema (11). In addition, the cloudy contrast enhancement is also suggested to be an important finding (12). The cranial MRI of our case was normal.

The autoantibody developed against Aquaporin 4, a water channel protein, and intensively present at the astrocytic protrusions, was suggested to be responsible from the pathogenesis of the disease (4,5). The binding of these antibodies to the aquaporin 4 channel protein, occurs hyperpermeability at the blood brain barrier, followed by perivascular inflammation, astrocyte damage and inflammation at the spinal cord and/or demyelination and cavitation at the optic nerve (2). Lennon et al. reported that the AQP4-IgG positivity shows 73% sensitivity and 91% specificity in patients with clinically NMO suspected patients. In the other autoimmune disease, however, the presence of NMO IgG couldn't be demonstrated (6). The AQP4-IgG antibody was also positive in our case.

The most important data showing the role of autoimmunity in NMO, is the association of NMO with other autoimmune diseases such as SLE, antiphospholipid syndrome, Sjögren syndrome, Hashimoto's thyroiditis, romatoid arthritis, ulcerative colitis, pernicious anemia and myasthenia gravis (13-15). In our case, however, neither clinical nor laboratory findings have been detected as a finding of such an association.

Cerebrospinal fluid (CSF) findings are important in the diagnosis and differential diagnosis from MS. In MS patients, the number of cells per cubic millimeter are below 50 (usually below 20) and there are only mononuclear cells, protein is normal or slightly

increased, and in more than 90% of the patients, there are oligoclonal bands that prove the synthesis of intrathecal IgG. However, in NMO patients, the number of cells may be above 50 and polymorphs may be seen, protein may be increased, and the oligoclonal band positivity is seen in about 1/5 of the patients, and may be temporary (3). The CSF examination of our cases was consistent with NMO, with the oligoclonal band negativity and the IgG index negativity.

NMO is a disease with a course with severe sequelae; for this reason, both the acute and maintenance therapies are important. In the acute period, very good results may be obtained with pulse steroid therapy. If the response to treatment is not good, plasmapheresis and IVIG and cytostatic drugs may be used (16). In addition, Rituximab, which is a monoclonal antibody against B lymphocytes is recommended (17). In our case, clinical improvement was observed with 7 day-pulse steroid treatment in the acute period, and the patient was followed with 1 gr/day steroid each month (for 6 months) and Azathioprine 2 mg/kg/day maintenance treatment.

The primary and secondary treatment strategies for NMOSDs are defined by study groups. Oral prednisolone combined with azathioprine and rituximab are recommended as first line treatment, while cyclophosphamide, mitoxantrone and mycophenolate mofetil are recommended as the secondary treatment (2).

In conclusion we emphasize the importance of the early and right diagnosis of NMO, and the management of the treatment of both acute and chronic phases and draw attention to the significance of the strict patient-physician collaboration in the follow-up period.

REFERENCES

1. Argyriou AA, Makris NN. *Neuromyelitis optica: a distinct demyelinating disease of the central nervous system. Acta Neurol Scand* 2008; 118: 209-17. [CrossRef]
2. Sellner J, Boggild M, Clanet M, Hintzen RQ, Illes Z, Montalban X, et al. *EFNS guidelines on diagnosis and management of neuromyelitis. Eur J Neurol* 2010; 17: 1019-32. [CrossRef]
3. Akman Demir G. *Nöromiyelitis optika: Klinik ve İmmünolojik Özellikler. Türkiye Klinikleri J Neurol-Special Topics* 2009; 4: 37-40.
4. Saikali P, Cayrol R, Vincent T. *Anti-aquaporin-4 autoantibodies orchestrate the pathogenesis in neuromyelitis optica. Autoimmun Rev* 2009; 9: 132-5. [CrossRef]

5. Lennon VA, Kryzer TJ, Pittock SJ, Verkman AS, Hinson SR. IgG marker of optic-spinal multiple sclerosis binds to the aquaporin-4 water channel. *J Exp Med* 2005; 202: 473-7. [\[CrossRef\]](#)
6. Lennon VA, Wingerchuk DM, Kryzer TJ, Pittock SJ, Lucchinetti CF, Fujihara K, et al. A serum autoantibody marker of neuromyelitis optica: distinction from multiple sclerosis. *Lancet* 2004; 364: 2106-12. [\[CrossRef\]](#)
7. Wingerchuk DM, Hogancamp WF, O'Brien PC, Weinshenker BG. The clinical course of neuromyelitis optica (Devic's syndrome). *Neurology* 1999; 53: 1107-14. [\[CrossRef\]](#)
8. Wingerchuk DM, Lennon VA, Lucchinetti CF, Pittock SJ, Weinshenker BG. The spectrum of neuromyelitis optica. *Lancet Neurol* 2007; 6: 805-15. [\[CrossRef\]](#)
9. Wingerchuk DM, Banwell B, Bennett JL, Cabre P, Carroll W, Chitnis T, et al. International consensus diagnostic criteria for neuromyelitis optica spectrum disorders. *Neurology* 2015; 85: 177-89. [\[CrossRef\]](#)
10. Pittock SJ, Lennon VA, Krecke K, Wingerchuk DM, Lucchinetti CF, Weinshenker BG. Brain abnormalities in neuromyelitis optica. *Arch Neurol* 2006; 63: 390-6. [\[CrossRef\]](#)
11. Matsushita T, Isobe N, Matsuoka T, Ishizu T, Kawano Y, Yoshiura T, et al. Extensive vasogenic edema of anti-aquaporin-4 antibody-related brain lesions. *Mult Scler* 2009; 15: 1113-7. [\[CrossRef\]](#)
12. Ito S, Mori M, Makino T, Hayakawa S, Kuwabara S. Cloud-like enhancement is a magnetic resonance imaging abnormality specific to neuromyelitis optica. *Ann Neurol* 2009; 66: 425-8. [\[CrossRef\]](#)
13. Min JH, Kim HJ, Kim BJ, Lee KW, Sunwoo IN, Kim SM, et al. Brain abnormalities in Sjogren syndrome with recurrent CNS manifestations: association with neuromyelitis optica. *Mult Scler* 2009; 15: 1069-76. [\[CrossRef\]](#)
14. Kim SM, Waters P, Vincent A, Kim SY, Kim HJ, Hong YH, et al. Sjogren's syndrome myelopathy: spinal cord involvement in Sjogren's syndrome might be a manifestation of neuromyelitis optica. *Mult Scler* 2009; 15: 1062-8. [\[CrossRef\]](#)
15. Mc Keon, Lennon VA, Jacob A, Matiello M, Lucchinetti CF, Kale N, et al. Coexistence of myasthenia gravis and serological markers of neurological autoimmunity in neuromyelitis optica. *Muscle Nerve* 2009; 39: 87-90. [\[CrossRef\]](#)
16. Jacob A, Matiello M, Weinshenker BG, Wingerchuk DM, Lucchinetti C, Shuster E, et al. Treatment of neuromyelitis optica with mycophenolate mofetil: retrospective analysis of 24 patient. *Arch Neurol* 2009; 66: 1128-33. [\[CrossRef\]](#)
17. Jacob A, Weinshenker BG, Violich I, McLinskey N, Krupp L, Fox RJ, et al. Treatment of neuromyelitis optica with rituximab: retrospective analysis of 25 patients. *Arch Neurol* 2008; 65: 1443-8. [\[CrossRef\]](#)