



## Case Report

# Ankyloblepharon Filiforme Adnatum in a 3-day-old Neonate: A Case Report

Cagri Cumhur Gok, Emrah Can, Sahin Hamilcikan

Department of Neonatal Intensive Care, University of Health Sciences Türkiye, Bagcilar Training and Research Hospital, Istanbul, Türkiye

### Abstract

Ankyloblepharon filiforme adnatum (AFA) is a rare congenital anomaly consisting of partial or complete fusion of the eyelid margins. It is usually isolated and benign, but its presence should alert the neonatologist as it may rarely be associated with other disorders. We present a case of a 3-day-old newborn presenting with isolated AFA at birth.

**Keywords:** Amblyopia, ankyloblepharon filiforme, neonate

Please cite this article as "Gok CC, Can E, Hamilcikan S. Ankyloblepharon Filiforme Adnatum in a 3-day-old Neonate: A Case Report. Med Bull Sisli Etfal Hosp 2023;57(2):279–282".

Ankyloblepharon filiforme adnatum (AFA) is a congenital condition where the eyelids are connected by a single or multiple tissue bridge, and therefore, the eyes are not allowed to open. AFA must be distinguished from ankyloblepharon; where the eyelid margins are directly attached to.<sup>[1]</sup> Despite its low incidence, it is important due to the risk of amblyopia.

It may be an isolated situation or may be associated with various syndromes. In this case, we presented a 3-day-old newborn with ankyloblepharon filiform. In this case presented, parental consent was obtained.

### Case Report

A 3300 g female neonate, born to a gravida 4 para 4, 40-year-old mother, after an uncomplicated 38-week pregnancy, was referred to our clinic on her 3<sup>rd</sup> day of life for general assessment. There is not any history of congenital anomalies in the female neonate's family history and pregnancy

and birth were unremarkable. The complete examination performed by the pediatrician did not reveal any unusual symptoms or findings except an adhesion between the left eyelids with a single thin band (Figs. 1 and 2). The patient was consulted at the ophthalmology clinic, and an ophthalmologist planned the operation. In the operation performed, a 0.5 cm band of fibrous tissue between the eyelids in the left eye was separated from the gray line connecting the eyelid margins (Figs. 3 and 4). The ophthalmologist recommended the post-operative use of an eye pomade of bacitracin and neomycin mixture and netilmicin eye drop for 14 days. The patient, who had no abnormality in the post-operative physical examination and blood tests, was discharged on the 7<sup>th</sup> day of her life and the 5<sup>th</sup> day of her hospitalization (Fig. 5). An additional anomaly was not detected in cranial ultrasonography, echocardiography, and abdominal ultrasonography examinations performed for other system anomalies.

**Address for correspondence:** Emrah Can, MD. Department of Neonatal Intensive Care, Health Sciences University, Bagcilar Training and Research Hospital, Istanbul, Türkiye

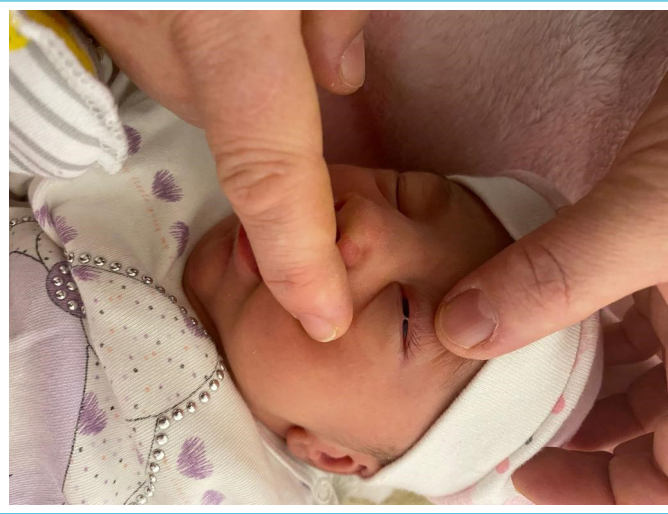**Phone:** +90 532 512 36 06 **E-mail:** canemrahcan@yahoo.com

**Submitted Date:** May 17, 2022 **Revised Date:** August 26, 2022 **Accepted Date:** September 06, 2022 **Available Online Date:** June 20, 2023

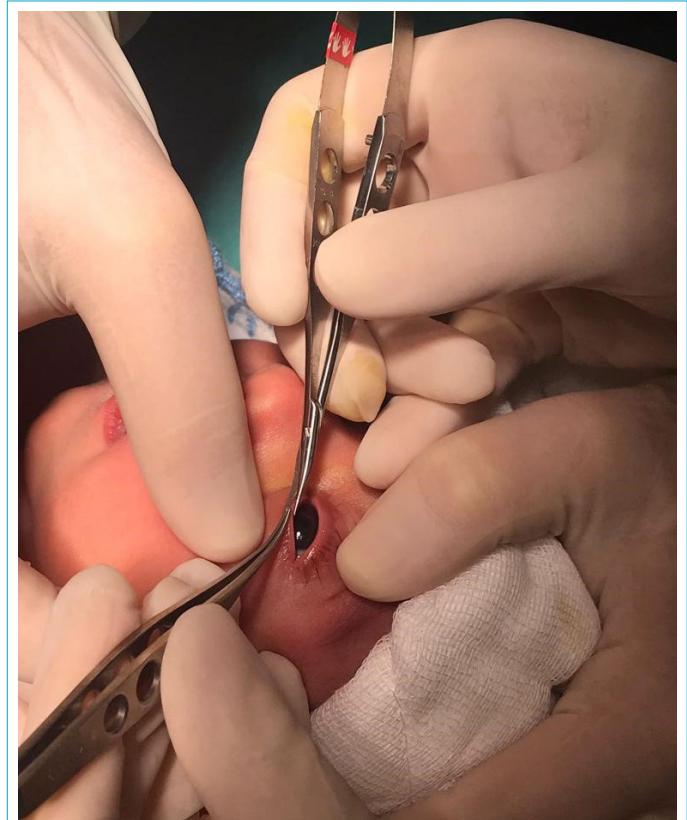
©Copyright 2023 by The Medical Bulletin of Sisli Etfal Hospital - Available online at [www.sislietfaltip.org](http://www.sislietfaltip.org)

**OPEN ACCESS** This is an open access article under the CC BY-NC license (<http://creativecommons.org/licenses/by-nc/4.0/>).

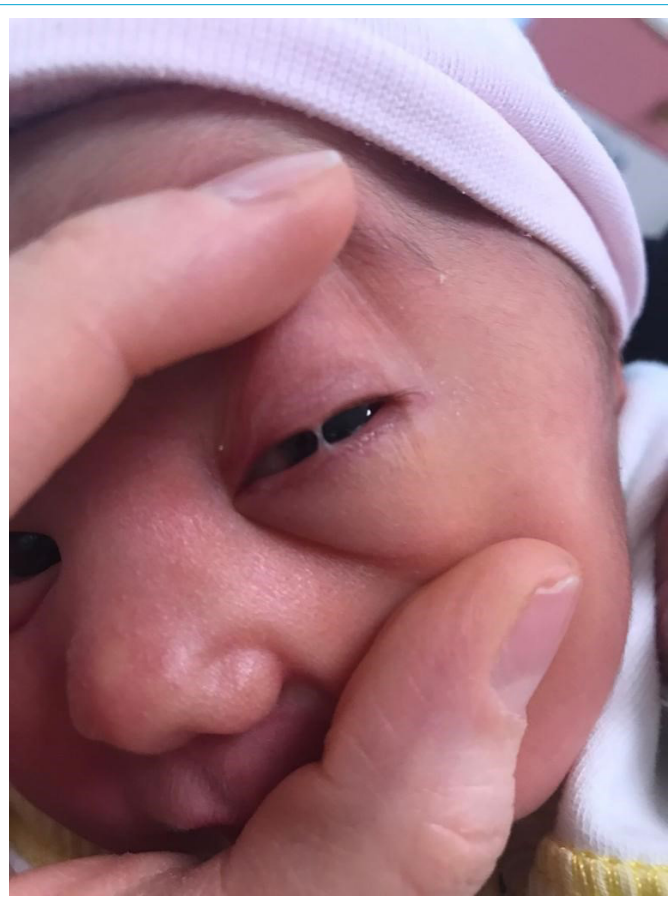



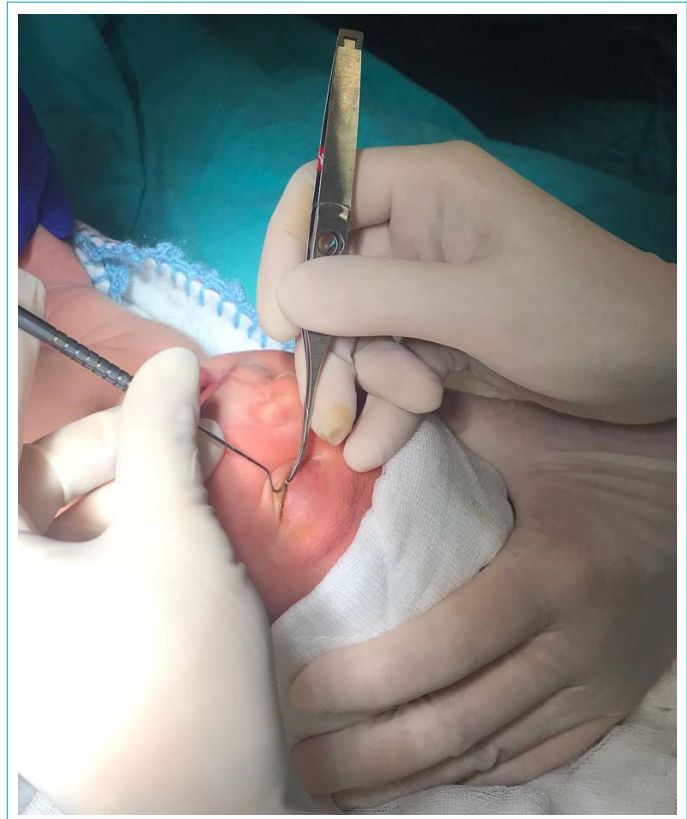
**Figure 1.** Left eye localized ankyloblepharon filiforme.



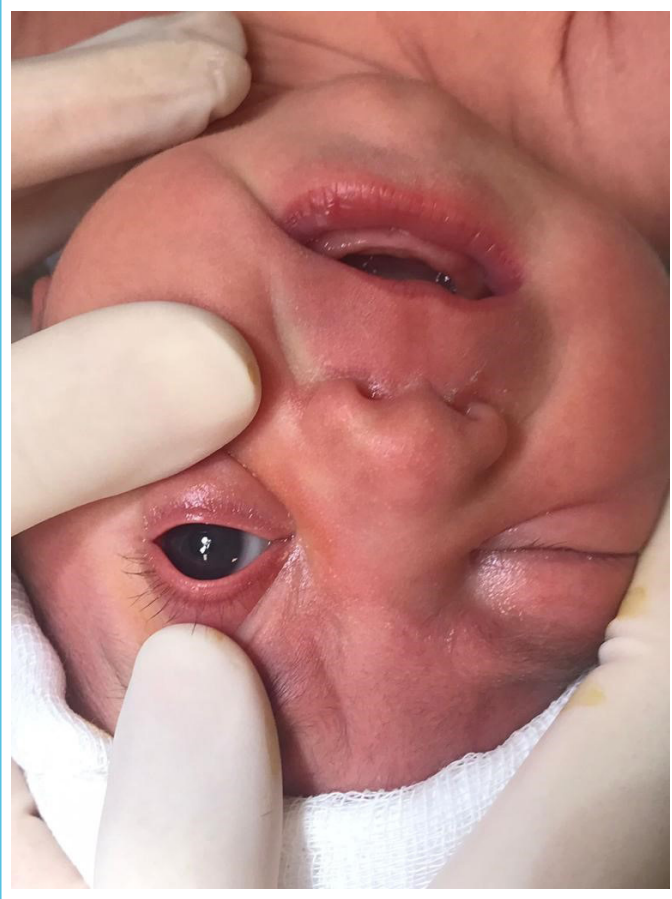**Figure 3.** Pre-operative appearance left ankyloblepharon filiforme.



**Figure 2.** Left eye localized ankyloblepharon filiforme.



**Figure 4.** Operation of left ankyloblepharon filiforme.



**Figure 5.** Post-operative appearance left eye.

## Discussion

AFA is rare, with an incidence of 4.4/100,000 births, but it is a benign condition of the eye.<sup>[2,3]</sup> Although it is associated with additional anomalies, sporadic cases have also been reported. The eyelids separate between the 5<sup>th</sup> and 7<sup>th</sup> months in utero. In the 5<sup>th</sup> month, desmosomes of the epithelial cells of the eyelids begin to rupture.<sup>[4]</sup> It is considered that lipid secretion of meibomian glands, keratinization, and traction force of orbicularis muscle is responsible for this separation.<sup>[2]</sup> Therefore, it is unusual for the eyelids to have adhered to each other with bands at birth.<sup>[5]</sup> Although the exact etiology is unknown, some theories have been put forward. The currently accepted theory is that this occurs through the interaction of transient epithelial arrest and rapid mesenchymal proliferation.<sup>[6]</sup> Ankyloblepharon filiforme may be sporadic, as in our case, or may accompany systemic diseases such as cleft lip and palate, ectodermal dysplasia syndromes, and popliteal pterygium syndrome.<sup>[6-8]</sup> It also might be associated with Edwards syndrome and curly hair, ankyloblepharon, nail dysplasia.<sup>[9,10]</sup> None of these associations were observed in our case, and associations such as hydrocephalus, meningomyelocele,

and imperforated anus were not detected.<sup>[11]</sup> In addition, although AFA may be associated with eye anomalies such as infantile glaucoma and iridodysgenesis, the ocular examination of our patient was normal except for AFA.<sup>[12,13]</sup> We did not find a genetic condition in our case's anamnesis and family history. Rosenman et al.<sup>[14]</sup> divided the ankyloblepharon filiforme into four groups, while AFA is not associated with any syndrome or disease in the first group, it is accompanied by the central nervous system and cardiovascular anomalies in the second group. In the third group, there is ectodermal dysplasia coexistence exists. In the fourth, cleft lip and cleft palate are additional pathologies to AFA. While the first and second groups are sporadic, the third and fourth groups may show autosomal dominant and variable expressivity. Bacal et al.<sup>[9]</sup> suggested a fifth group, in which AFA was accompanied by chromosomal anomalies.

Since there is a risk of amblyopia, the operation should be performed as soon as possible.<sup>[15]</sup> The treatment is very simple and relies on cutting the bands with a suture cutter without the need for local anesthesia or sedation.<sup>[5]</sup>

## Conclusion

In this case report, we wanted to emphasize that ankyloblepharon filiforme, which may also be associated with other diseases, can also be a sporadic and easy-to-manage condition that needs to be treated as soon as possible due to the development of amblyopia. It is essential that patients must be subjected to detailed tests for additional anomalies before a decision is made as sporadic.

## Disclosures

**Informed consent:** Written, informed consent was obtained from the patient's family for the publication of this case report and the accompanying images.

**Peer-review:** Externally peer-reviewed.

**Conflict of Interest:** None declared.

**Authorship Contributions:** Concept – C.C.G., E.C.; Design – C.C.G., E.C.; Supervision – E.C., S.H.; Fundings – C.C.G., S.H.; Materials – C.C.G., S.H.; Data collection &/or processing – C.C.G., S.H.; Analysis and/ or interpretation – E.C., S.H.; Literature search – E.C., C.C.G., S.H.; Writing – E.C., C.C.G., S.H.; Critical review – E.C., S.H.

## References

1. Duke-Elder S. System of Ophthalmology, Vol. 3, Part 2. London: Henry Kimpton; 1964. p.869.
2. Hamilton WJ, Boyd JD, Mossman HW. Hamilton, Boyd and Mossman's Human Embryology: Prenatal development of form and function. 4th ed. Cambridge: Heffer; 1972. [\[CrossRef\]](#)
3. Jain S, Atkinson AJ, Hopkisson B. Ankyloblepharon filiforme adnatum. Br J Ophthalmol 1997;81:708. [\[CrossRef\]](#)

4. Stolowy N, Ramtohol P, Caselles K, Denis D. Ankyloblepharon filiforme adnatum. *J Fr Ophtalmol* 2019;42:e125–6. [\[CrossRef\]](#)
5. Patra P, Singh A. Ankyloblepharon filiforme adnatum in a new born. *J Neonatal Surg* 2016;5:10. [\[CrossRef\]](#)
6. Vanderhooft SL, Stephan MJ, Sybert VP. Severe skin erosions and scalp infections in AEC syndrome. *Pediatr Dermatol* 1993;10:334–40. [\[CrossRef\]](#)
7. Long JC, Blandford SE. Ankyloblepharon filiforme adnatum with cleft lip and palate. *Am J Ophthalmol* 1962;53:126–9. [\[CrossRef\]](#)
8. Akkermans CH, Stern LM. Ankyloblepharon filiforme adnatum. *Br J Ophthalmol* 1979;63:129–31. [\[CrossRef\]](#)
9. Bacal DA, Nelson LB, Zackai EH, Lavrich JB, Kousseff BG, McDonald-McGinn D. Ankyloblepharon filiforme adnatum in trisomy 18. *J Pediatr Ophthalmol Strabismus* 1993;30:337–9. [\[CrossRef\]](#)
10. Toriello HV, Lindstrom JA, Waterman DF, Baughman FA. Re-evaluation of CHANDS. *J Med Genet* 1979;16:316–7. [\[CrossRef\]](#)
11. Kazarian EL, Goldstein P. Ankyloblepharon filiforme adnatum with hydrocephalus, meningomyelocele, and imperforate anus. *Am J Ophthalmol* 1977;84:355–7. [\[CrossRef\]](#)
12. Kuruvilla SE, Simha AR. A rare variant of ankyloblepharon filiforme adnatum associated with skin hypopigmentation: a case report from South India. *Indian J Ophthalmol* 2016;64:241–3. [\[CrossRef\]](#)
13. Chakraborti C, Chaudhury KP, Das J, Biswas A. Ankyloblepharon filiforme adnatum: report of two cases. *Middle East Afr J Ophthalmol* 2014;21:200–2. [\[CrossRef\]](#)
14. Rosenman Y, Ronen S, Eidelman AI, Schimmel MS. Ankyloblepharon filiforme adnatum: congenital eyelid-band syndromes. *Am J Dis Child* 1980;134:751–3. [\[CrossRef\]](#)
15. Ioannides A, Georgakarakos ND. Management of ankyloblepharon filiforme adnatum. *Eye* 2011;25:823. [\[CrossRef\]](#)