



## Case Report

# Endovascular Pipeline Shield Treatment of Iatrogenic Internal Carotid Artery Pseudoaneurysm and Carotid-Cavernous Fistula

Eyup Camurcuoglu,<sup>1</sup> Umut Erdem,<sup>2</sup> Ender Uysal<sup>3</sup>

<sup>1</sup>Department of Radiology, Sanliurfa Training and Research Hospital, Sanliurfa, Türkiye

<sup>2</sup>Department of Radiology, University of Health Sciences Türkiye, Sisli Hamidiye Etfal Training and Research Hospital, Istanbul, Türkiye

<sup>3</sup>Department of Radiology, Antalya Training and Research Hospital, Antalya, Türkiye

### Abstract

Pseudoaneurysm (PA) and carotid cavernous fistula (CCF) of the internal carotid artery (ICA) is an uncommon complication of endoscopic endonasal surgery that occurs in 1% of cases. We report on the successful placement of flow-diverting stents (FDS) to ICA pseudoaneurysm and carotidocavernous fistula caused by iatrogenic ICA injury for a pituitary adenoma in a 37-year-old female. After placement of the pipeline shield given a certain time, dual antiplatelet agents (DAPT) and follow-up angiogram verified complete aneurysm obliteration and effective endoluminal reconstruction of the injured vessel. In managing ICA pseudoaneurysms, the placement of flow-diverting stents is a viable vessel-sparing technique.

**Keywords:** Carotidocavernous fistula, endovascular treatment, flow diverting stent, intracranial pseudoaneurysm

Please cite this article as "Camurcuoglu E, Erdem U, Uysal E. Endovascular Pipeline Shield Treatment of Iatrogenic Internal Carotid Artery Pseudoaneurysm and Carotid-Cavernous Fistula. Med Bull Sisli Etfal Hosp 2024;58(1):135–137".

**T**ranssphenoidal sinus surgery (TSS) is a safe and highly effective approach for pituitary lesions, particularly adenomas, and has minimal complications. However, ICA injury is an uncommon and life-threatening complication of TSS that can result in massive bleeding, PA, and CCF. During TSS, the rate of internal carotid injury is 1%.<sup>[1]</sup>

Iatrogenic ICA injury should be detected immediately, and neurovascular treatment should be initiated. Although there are no definite standards for managing it, bleeding should be controlled with the proper hemostatic materials, and Digital subtraction angiography (DSA) should be performed. Endovascular treatments for iatrogenic ICA injuries include parent artery occlusion, coil embolization, graft stent implantation, and pipeline shield placement.<sup>[2]</sup> We present the most recent endovascular therapy procedure for the treatment of ICA injury: the placement of flow-

diverting stents (FDS) to eliminate ICA PA and CCF caused by iatrogenic ICA injury.

### Case Report

The patient was a 37-year-old woman. Magnetic resonance imaging (MRI) of the pituitary mass reveals encasement of the ICA. When the endoscopic tumor excision was performed, bleeding occurred from the carotid location. The surgeon controlled the bleeding with local packing and placed abdominal fat. The patient was transferred to the interventional radiology unit as intubated.

Cerebral DSA showed a pseudo-aneurysm proximal to the right ICA cavernous segment and a carotidocavernous fistula draining towards the inferior petrosal sinus (Fig. 1). We decided to attempt a flow diverter stent placement to treat the injury. A 6F guide catheter was used proximally in

**Address for correspondence:** Eyup Camurcuoglu, MD. Department of Radiology, Sanliurfa Training and Research Hospital, Sanliurfa, Türkiye

**Phone:** +90 414 317 17 17 **E-mail:** eyupcamurcuoglu@gmail.com

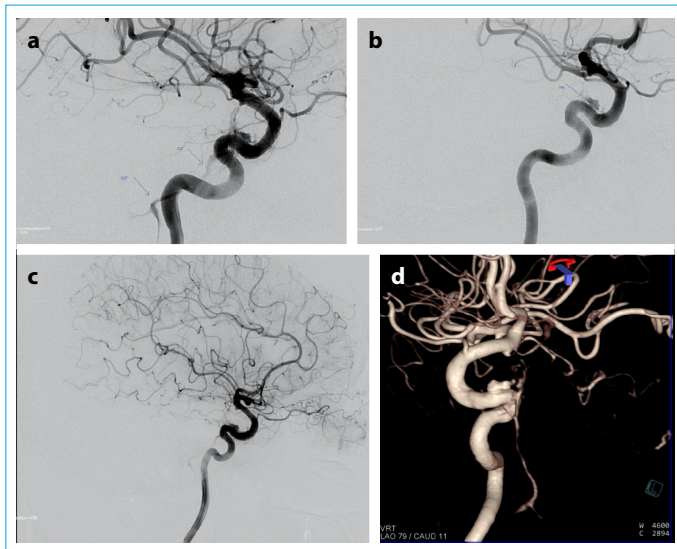
**Submitted Date:** August 21, 2023 **Revised Date:** October 22, 2023 **Accepted Date:** March 12, 2024 **Available Online Date:** April 05, 2024

©Copyright 2024 by The Medical Bulletin of Sisli Etfal Hospital - Available online at [www.sislietfaltip.org](http://www.sislietfaltip.org)

**OPEN ACCESS** This is an open access article under the CC BY-NC license (<http://creativecommons.org/licenses/by-nc/4.0/>).



the common carotid artery, and a 6F intracranial support catheter was advanced into the ICA distal segment. A microcatheter was passed through the injured part of the ICA using a micro guidewire. The microcatheter was replaced, and two intertwined flow diverter stents (4x25 mm) were placed across the neck of the aneurysm (Fig. 2A). A balloon catheter angioplasty was performed for wall apposition (Fig. 2B). We administered a 2,500 IU heparin bolus during the procedure after inserting the femoral sheath, followed by 1,000 IU every hour. In addition, the patient was given dual antiplatelet agents (DAPT) Acetylsalicylic acid (ASA) 300 mg and Clopidogrel 600 mg were loaded through a nasogastric tube after the Pipeline was placed.



**Figure 1.** Angiography was performed to confirm the iatrogenic ICA injury. Lateral projection (a, b) and 3D angiogram (c) was obtained. Carotico-cavernous fistula (a) draining towards to inferior petrosal sinus and Pseudo-aneurysm (b) was seen proximal to the right ICA cavernous segment.

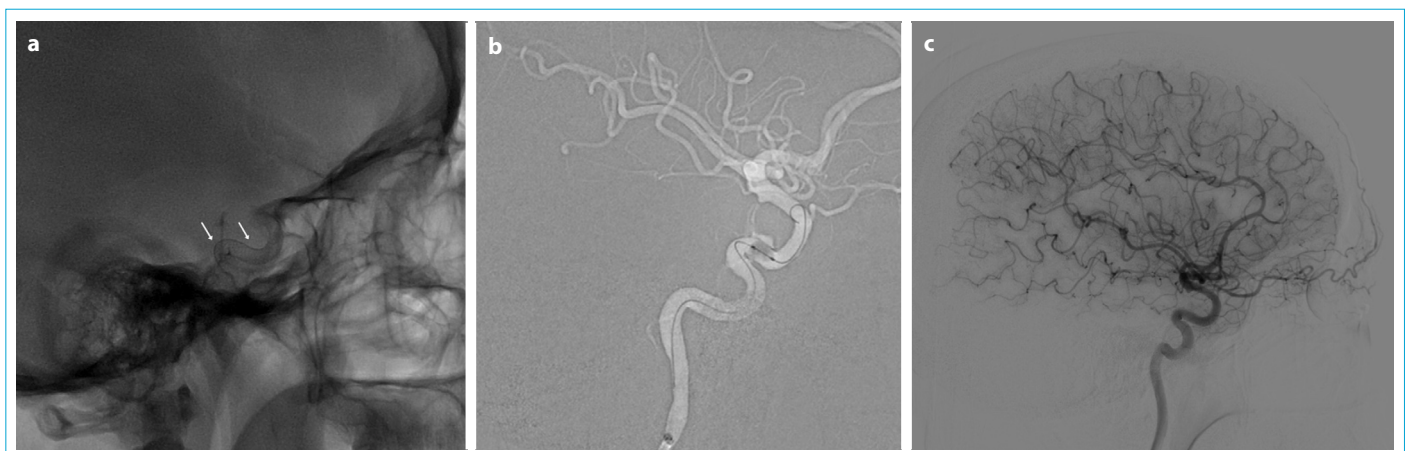
The patient was transferred to the intensive care unit; there was no neurological deficit. Follow-up DSA was obtained one day after stent placement, pseudoaneurysm size was reduced, and six months after, the patient was shown to have absent CCF filling, complete obliteration of the pseudoaneurysm, with normal patency of the ICA (Fig. 2C). Subsequently, aspirin (100mg\daily) and clopidogrel (75mg\ daily) were taken together for 6 months followed by aspirin alone for lifelong.

## Discussion

In this study, we demonstrate our management of cavernous ICA acute injury, representing a case of patients treated in the emergency department with endovascular FDS placement. We can treat pseudoaneurysms with less invasive methods using flow-diverting stents while preserving the parent artery.

ICA injury is an uncommon and life-threatening complication of TSS. The most common site of vascular injury during trans-sphenoidal surgery is the cavernous ICA.<sup>[3]</sup> PA, CCF, subarachnoid hemorrhage (SAH), and severe epistaxis are the most common manifestations of vascular injury during TSS.<sup>[4]</sup>

During an intra-operative ICA rupture, packing materials should be inserted with just enough force to limit bleeding while not obstructing vascular flow. Despite successful intraoperative tamponade, significant bleeding during trans-sphenoidal surgery requires urgent vascular imaging.<sup>[3]</sup> There are three treatment choices for such a condition: ICA sacrifice, endoluminal reconstruction, and embolization.<sup>[5]</sup> The occlusion of the parent artery (PAO) with endovascular methods remains the certain treatment for managing ICA injury. On the other hand, PAO is an invasive and destructive procedure. Moreover, there is still a 5–20% risk of developing ischemia complications.<sup>[6]</sup>



**Figure 2.** (a) Two intertwined flow diverter stents (4x25 mm) placed and balloon catheter angioplasty was performed (b). Six months after (c), the patient was shown to have absent CCF filling, complete obliteration of the pseudoaneurysm, with normal patency of the ICA.

The treatment of this lesion has lately evolved to a reconstructive vessel technique that merely removes an aneurysm from circulation while preserving vascular patency. Several cases of intracranial pseudoaneurysms have been treated using vessel-reconstructive endovascular methods such as covered or flow-diverting stents. Two retrospective studies on the outcomes of covered stent implantation were published by Zhang et al.<sup>[7]</sup> and Kim et al.<sup>[8]</sup> In the first, six injuries were treated with a covered stent, with good clinical outcomes (mRS=0). In the latter, six lesions were treated with covered stents, resulting in good outcomes (mRS=1–2). Griauzde et al.<sup>[9]</sup> The case series of cavernous ICA were successfully treated with FDS deployment and had a good clinical outcome (mRS=0-1). Giorgianni et al.<sup>[5]</sup> Endovascular FDS emergency placement can be effective with no periprocedural ischemic-hemorrhagic complications.

Flow diverters are the most effective method for stabilizing artery walls and reducing the procedural trauma associated with fragile aneurysms.<sup>[10,11]</sup> This technology is better for treatment because iatrogenic pseudoaneurysms are highly fragile and prone to rupture. Compared to conventional balloons or self-expanding stents, a flow-directing stent provides complete aneurysm neck coverage with better flexibility and adaptable radial force.<sup>[2]</sup>

Pipeline embolization frequently needs DAPT administration for a set amount of time. In our case study, we completely occluded the pseudoaneurysm and switched from DAPT to SAPT six months after placing the pipeline. The patient has had no symptoms for 18 months following the pipeline embolization.

The limitations of pipeline shield are bleeding-related conditions such as active bleeding, persistent rebleeding, and the need for post-procedural double antiplatelet therapy. The first stage in employing a flow-diverting stent is achieving hemodynamic stability with efficient packing. Finally, an endovascular technique for treating ICA pseudoaneurysm after transsphenoidal pituitary surgery may be an alternate option with similar effectiveness and fewer complications than previous procedures. Further studies are required to validate this theory in a larger patient population.

## Conclusion

ICA injury is an uncommon and life-threatening complication of TSS. There are a few treatment choices for such a condition: ICA sacrifice, endoluminal reconstruction, and embolization. In managing ICA injury, the placement of flow-diverting stents is a viable vessel-sparing technique.

## Disclosures

**Informed consent:** Written informed consent was obtained from the patient for the publication of the case report and the accompanying images.

**Peer-review:** Externally peer-reviewed.

**Conflict of Interest:** None declared.

**Authorship Contributions:** Concept – E.C.; Design – E.C., E.U.; Supervision – E.C., E.U.; Materials – U.E.; Data collection &/or processing – E.C., U.E.; Analysis and/or interpretation – E.U.; Literature search – E.U, U.E. ; Writing –E.C.; Critical review –E.U.

## References

- García-Garrigós E, Arenas-Jiménez JJ, Monjas-Cánovas I, Abarca-Olivas J, Cortés-Vela JJ, De La Hoz-Rosa J, et al. Transsphenoidal approach in endoscopic endonasal surgery for skull base lesions: what radiologists and surgeons need to know. *Radiographics* 2015;35:1170–85. [\[CrossRef\]](#)
- Sylvester PT, Moran CJ, Derdeyn CP, Cross DT, Dacey RG, Zipfel GJ, et al. Endovascular management of internal carotid artery injuries secondary to endonasal surgery: case series and review of the literature. *J Neurosurg* 2016;125:1256–76. [\[CrossRef\]](#)
- Karadag A, Kinali B, Ugur O, Oran I, Middlebrooks EH, Senoglu M. A case of pseudoaneurysm of the internal carotid artery following endoscopic endonasal pituitary surgery: endovascular treatment with flow-diverting stent implantation. *Acta Medica (Hradec Kralove)* 2017;60:89–92. [\[CrossRef\]](#)
- Aydin E, Gok M, Esenkaya A, Cinar C, Oran I. Endovascular management of iatrogenic vascular injury in the craniocervical region. *Turk Neurosurg* 2018;28:72–8.
- Giorgianni A, Agosti E, Terrana A, Pozzi F, Sileo G, Nativo L, et al. Emergency endovascular treatment of cavernous internal carotid artery acute bleeding with flow diverter stent: a single-center experience. *Acta Neurochir (Wien)* 2021;163:2055–61. [\[CrossRef\]](#)
- Nariai Y, Kawamura Y, Takigawa T, Hyodo A, Suzuki K. Pipeline embolization for an iatrogenic intracranial internal carotid artery pseudoaneurysm after transsphenoidal pituitary tumor surgery: case report and review of the literature. *Interv Neuroradiol* 2020;26:74–82.
- Zhang Y, Tian Z, Li C, Liu J, Zhang Y, Yang X, et al. A modified endovascular treatment protocol for iatrogenic internal carotid artery injuries following endoscopic endonasal surgery. *J Neurosurg* 2019;132:343–50. [\[CrossRef\]](#)
- Kim BM, Jeon P, Kim DJ, Kim DI, Suh SH, Park KY. Jostent covered stent placement for emergency reconstruction of a ruptured internal carotid artery during or after transsphenoidal surgery. *J Neurosurg* 2015;122:1223–8. [\[CrossRef\]](#)
- Griauzde J, Ravindra VM, Chaudhary N, Gemmete JJ, Mazur MD, Roark CD, et al. Use of the Pipeline embolization device in the treatment of iatrogenic intracranial vascular injuries: a bi-institutional experience. *Neurosurg Focus* 2017;42:E9. [\[CrossRef\]](#)
- Ghorbani M, Griessenauer CJ, Shojaei H, Wipplinger C, Hejazian E. Endovascular reconstruction of iatrogenic internal carotid artery injury following endonasal surgery: a systematic review. *Neurosurg Rev* 2021;44:1797–804. [\[CrossRef\]](#)
- Kaya V, Tahtabasi M, Yıldırım İO. Risk factors for the rupture of anterior communicating artery aneurysms: coexistence of fetal-type posterior cerebral artery and A1 segment hypoplasia/agenesis. *J Clin Neurosci* 2023;110:74–9. [\[CrossRef\]](#)