



## Review

# Anatomical, Functional, and Dynamic Evidences Obtained by Intraoperative Neuromonitoring Improving the Standards of Thyroidectomy

Nurcihan Aygun,<sup>1</sup> Mehmet Kostek,<sup>1</sup> Adnan Isgor,<sup>2</sup> Mehmet Uludag<sup>1</sup>

<sup>1</sup>Department of General Surgery, University of Health Sciences Turkey, Sisli Hamidiye Etfal Teaching and Research Hospital, Istanbul, Turkey

<sup>2</sup>Department of General Surgery, Bahcesehir University Faculty of Medicine, Istanbul; Sisli Memorial Hospital, Istanbul, Turkey

### Abstract

The use of intraoperative neuromonitoring (IONM) is getting more common in thyroidectomy. The data obtained by the usage of IONM regarding the laryngeal nerves' anatomy and function have provided important contributions for improving the standards of the thyroidectomy. These evidences obtained through IONM increase the rate of detection and visual identification of recurrent laryngeal nerve (RLN) as well as the detection rate of extralaryngeal branches which are the most common anatomic variations of RLN. IONM helps early identification and preservation of the non-recurrent laryngeal nerve. Crucial knowledge has been acquired regarding the complex innervation pattern of the larynx. Extralaryngeal branches of the RLN may contribute to the motor innervation of the cricothyroid muscle (CTM). Anterior branch of the extralaryngeal branching RLN has always motor function and gives motor branches both to the abductor and adductor muscles. In addition, up to 18% of posterior branches may have adductor and/or abductor motor fibers. In 70–80% of cases, external branch of superior laryngeal nerve (EBSLN) provides motor innervation to the anterior 1/3 of the thyroarytenoid muscle which is the main adductor of the vocal cord through the human communicating nerve. Furthermore, approximately 1/3 of the cases, EBSLN may contribute to the innervation of posterior cricoarytenoid muscle which is the main abductor of ipsilateral vocal cord. RLN and/or EBSLN together with pharyngeal plexus usually contribute to the motor innervation of cricopharyngeal muscle that is the main component of upper esophageal sphincter. Traction trauma is the most common reason of RLN injuries and constitutes of 67–93% of cases. More than 50% of EBSLN injuries are caused by nerve transection. A specific point of injury on RLN can be detected in Type 1 (segmental) injury, however, Type 2 (global) injury is the loss of signal (LOS) throughout ipsilateral vagus-RLN axis and there is no electrophysiologically detectable point of injury. Vocal cord paralysis (VCP) develops in 70–80% of cases when LOS persists or incomplete recovery of signal occurs after waiting for 20 min. In case of complete recovery of signal, VCP is not expected. VCP is temporary in patients with incomplete recovery of signal and permanent VCP is not anticipated. Visual changes may be seen in only 15% of RLN injuries, on the other hand, IONM detects 100% of RLN injuries. IONM can prevent bilateral VCP. Continuous IONM (C-IONM) is a method in which functional integrity of vagus-RLN axis is evaluated in real time and C-IONM is superior to intermittent IONM (I-IONM). During upper pole dissection, IONM makes significant contributions to the visual and functional identification of EBSLN. Routine use of IONM may minimize the risk of nerve injury. Reduction of amplitude more than 50% on CTM is related with poor voice outcome.

**Keywords:** Intraoperative monitoring; laryngeal nerve injuries; recurrent laryngeal nerve; thyroidectomy, vocal cord

Please cite this article as "Aygun N, Kostek M, Isgor A, Uludag M. Anatomical, Functional, and Dynamic Evidences Obtained by Intraoperative Neuromonitoring Improving the Standards of Thyroidectomy. Med Bull Sisli Etfal Hosp 2021;55(2):146–155".

**Address for correspondence:** Mehmet Kostek, MD. Saglik Bilimleri Universitesi, Sisli Hamidiye Etfal Egitim ve Arastirma Hastanesi, Genel Cerrahi Anabilim Dalı, Istanbul, Turkey

**Phone:** +90 542 391 00 56 **E-mail:** dr.mkostek@gmail.com

**Submitted Date:** May 28, 2021 **Accepted Date:** June 07, 2021 **Available Online Date:** July 02, 2021

©Copyright 2021 by The Medical Bulletin of Sisli Etfal Hospital - Available online at [www.sislietfaltip.org](http://www.sislietfaltip.org)

**OPEN ACCESS** This is an open access article under the CC BY-NC license (<http://creativecommons.org/licenses/by-nc/4.0/>).



Voice changes are the most frequent complications of thyroid surgery and these are multifactorial.<sup>[1]</sup> Main neural causes of post-operative vocal changes are injuries of recurrent laryngeal nerve (RLN) or external branch of the superior laryngeal nerve (EBSLN), however, this condition can be minimized in case of preservation of these two neural structures.<sup>[2]</sup>

Routine dissection and direct visualization of RLN, which was first described by Lahey in 1938 for the preservation of RLN in thyroidectomy, are still the gold standard techniques.<sup>[3]</sup> Nevertheless, anatomical integrity of a nerve does not warrant a preserved function for that nerve.

Intraoperative neuromonitorization (IONM) is a complementary technique which is based on the functional assessment of nerves in addition to the visual identification.<sup>[4]</sup>

### History of IONM in Thyroid Surgery

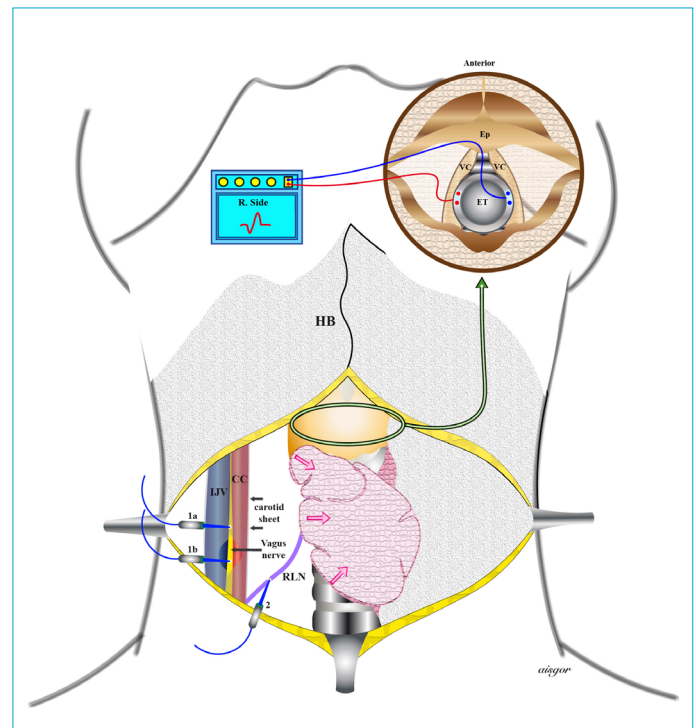
First techniques for identification with electrical stimulation of RLN and EBSLN in thyroid surgery using endolaryngeal balloon spirometry were described in 1966 in an experimental study. In the same study, it has been reported that pressure changes were recorded on endolaryngeal balloon after RLN stimulation in two human subjects.<sup>[5]</sup>

In 1970, Riddell mentioned in a study that during RLN stimulation vocal cord function can be assessed by intraoperative laryngoscopy, however, if laryngoscopy was not available, laryngeal palpation technique can be applied.<sup>[6]</sup> After this publication, to evaluate RLN stimulation, techniques of laryngeal palpation, glottic observation, glottic pressure monitorization, endoscopically implanted intramuscular electrodes, intramuscular electrodes implanted through cricothyroid membrane, endotracheal tube-based surface electrodes, and post-cricoid surface electrodes were described.<sup>[4]</sup>

XOMED NIM-2 electromyogram (EMG) endotracheal tube with surface electrodes which was industrially manufactured by Eisele for IONM was tested in 10 patients and approved by Food and Drug Administration. Eisele applied IONM with this endotracheal tube in 31 patients in 1996 and reported similar sensitivity compared with the intramuscular laryngeal electrodes for IONM.<sup>[7]</sup>

IONM using endotracheal tube-based surface electrodes has been popularized for its ease of use and installation, suitability for purpose, convenience, being non-invasive, and capacity for larger areas of contact with target muscles. Thus, endotracheal tube-based surface electrodes have become most commonly used standard technique for IONM (Fig. 1).<sup>[4,8]</sup>

First continuous IONM (C-IONM) system was described by Lamade et al. based on double balloon endotracheal tube



**Figure 1.** Schematic view of intermittent intraoperative neuromonitorization. According to suggestions of the International Neural Monitoring Study Group guidelines, intraoperative stimulations must acquire from vagus (V1) and RLN (R1) before thyroidectomy and RLN(R2) and vagus nerve (V2) after thyroidectomy. (Ep: Epiglottis, VC: Vocal cord, ET: Endotracheal tube, R. Side: Right side, HB: Hyoid bone, IJV: Internal jugular vein, CC: Common carotid artery, RLN: Recurrent laryngeal nerve, 1a: Stimulation of vagus nerve between two vascular structure without opening carotid sheath, 1b: Stimulation of vagus nerve by direct probe under direct visualization after carotid sheath is opened, 2: Stimulation of RLN by probe close to thyroid, Right upper arrow: Transverse section of larynx at the level of vocal cords and the position of surface electrode-based endotracheal tube placed between vocal cords.)

with stimulation and EMG recording electrodes.<sup>[8,9]</sup> Unfortunately, this system was not able to be used in routine practice due to the technical and economical reasons. C-IONM performed with a probe applied to the vagus nerve was first described by Lamade.<sup>[10]</sup> After that, various probes for vagus nerve were produced and used in C-IONM.<sup>[11]</sup>

In 2006, the International Neural Monitoring Study Group (INMSG) was established for neuromonitoring of the laryngeal nerves in thyroid and parathyroid surgery.<sup>[12]</sup> Study group published a guideline for standardization of RLN monitorization in 2011 and another guideline for standardization of EBSLN monitorization in 2013.<sup>[4,13]</sup> Study group published two more guidelines in 2018 after evaluating IONM data from literature. One of these guidelines was related with staged thyroidectomy in one sided loss of signal (LOS) during bilateral thyroidectomy and the other

guideline was about optimal RLN management in invasive thyroid cancer using surgical, laryngeal, and electroneurophysiologic data.<sup>[14,15]</sup>

As the debate continues whether IONM decreases the incidence of vocal cord paralysis (VCP) or not, data obtained from studies of IONM demonstrated that it has made important contributions for improving the standards of thyroidectomy.

### **Evidences Related with the Visual Identification of RLN**

Despite the fact that visual identification is the gold standard for preserving RLN in thyroidectomy, it can be difficult to visualize the nerve in case of the presence of etiological factors such as anatomical variations of RLN, recurrent goiter, enlarged substernal goiter or locally advanced thyroid cancer. IONM even helps early localization and identification of difficultly identifiable RLN which constitute almost 26% of all cases.<sup>[16]</sup>

Even in experienced centers, IONM has been shown to increase the nerve identification rate from 93% to 100% in primary thyroidectomies.<sup>[17]</sup> Especially in secondary cases, the course of the nerve change in 80% of cases and approximately 60% of the nerves passes through the scar or fibrotic tissue left by the first surgeries. The rate of visual identification of RLN is 45% that can be increased to 91% with IONM, and after getting experience with IONM, 100% of RLNs can be identified.<sup>[18]</sup>

### **Evidences Related with Anatomical Variations of RLN**

Anatomical variations of RLN may increase the risk of VCP and cannot be predicted preoperatively. Extralaryngeal branching is the most common variation of RLN with an approximate rate of 73.3% (95 % CI 61.0–84.0) in cadaveric studies. In clinical studies, the rate of extralaryngeal branching is lower than that of the cadaveric studies, because some of the branches are not able to be detected.<sup>[19]</sup> Anuwong et al.<sup>[17]</sup> reported that extralaryngeal branching can be detected visually in 21% of cases, furthermore, detection rate increases to 45% using IONM.

On top of being a rare variation of RLN, nonrecurrent RLN (non-RLN) is an important factor that increases risk of RLN injury. Mostly, it is originated from the right side and 85% of all cases are related with aberrant subclavian artery. Non-RLN originates from the vagus nerve above the laryngotracheal junction with a rate of 58% and below the laryngotracheal junction with a rate of 42%.<sup>[20]</sup> Using standard V1 stimulation in IONM, non-RLN can be identified before starting the dissection and this technique helps protecting the nerve's function and integrity.<sup>[21]</sup>

If the latency of the amplitude obtained through V1 stimulation is lower than 3.5 ms; sensitivity is 100%, specificity is 94%, positive predictive value is 100%, negative predictive value is 97%, and accuracy is 98% for the detection of the non-RLN.<sup>[22]</sup>

### **Evidences Related with Motor Innervation of the Larynx**

As a traditional knowledge, motor innervation of both adductor and abductor intrinsic laryngeal muscles is supplied by the RLN except the cricothyroid muscle (CTM). Innervation of CTM, which is the tensor muscle of the vocal cord, is provided by EBSLN. Besides that, internal branch of the superior laryngeal nerve (IBSLN) has sensorial function.<sup>[23]</sup>

In addition, laryngeal innervation has been shown to be more complex and variable than classical anatomical descriptions and neural connections have been demonstrated between EBSLN and RLN, IBSLN and RLN, and EBSLN and IBSLN in recent anatomical studies.<sup>[24,25]</sup> The motor functions of both RLN and EBSLN can be evaluated intraoperatively using IONM. The function of the thyroarytenoid muscle which is the main adductor muscle of the vocal cord can be assessed with IONM and surface electrode-based endotracheal tube. CTM function can be evaluated by visualization of the CTM twitch.<sup>[4,13]</sup> Moreover, the functions of the other laryngeal and adjacent muscles can be monitored with the use of multichannel IONM.<sup>[26]</sup>

The evidence regarding the motor function of the extralaryngeal branches of RLN is not clear in anatomical studies. In extralaryngeal branching nerves, anterior branch has been reported to have a motor function in all cases and giving branches to both adductor and abductor muscles in IONM studies.<sup>[27,28]</sup> In addition to the motor function of the anterior branch, posterior branches may contain adductor and/or abductor motor fibers with a rate up to 18.5%.<sup>[29,30]</sup>

Although the EBSLN has been reported to be the sole motor nerve of CTM, RLN or its extralaryngeal branches have been demonstrated to contribute to the motor innervation of the CTM.<sup>[31,32]</sup> After EBSLN innervating the CTM, distal branches of the EBSLN penetrate the larynx and reach the 1/3 anterior portion of the thyroarytenoid muscle and make a connection with RLN. This connection has been named as human communicating nerve and shown in 41–85% of cases in anatomical studies.<sup>[33,34]</sup> Related with the human communicating nerve, in addition to the CTM contraction by EBSLN stimulation, electromyographical data regarding the adductor function of the vocal cord can be obtained through endotracheal surface electrodes in 70–80% of cases.<sup>[35-39]</sup> The EBSLN also contributes to the ipsilateral in-

nervation of the posterior cricoarytenoid muscle which is the main abductor muscle of vocal cord, in 1/3 of all cases, in addition to its contribution to the adductor function of the vocal cord.<sup>[40]</sup>

Occasionally, pharyngeal plexus may contribute to the innervation of the vocal cord.<sup>[41]</sup> Motor innervation of crico-pharyngeal muscle which is the major component of upper esophageal sphincter may be provided by RLN and/or EBSLN in addition to the pharyngeal plexus.<sup>[26]</sup> In patients with preoperative VCP, electrophysiologic activity can be detected from the vocal cords with the stimulation of RLN in 15–50% of all cases when RLN is anatomically intact.<sup>[42,43]</sup> It is claimed that despite the insufficient function of the nerve, there might be a residual function preserved which may be an important factor for preventing vocal cord atrophy.<sup>[44]</sup>

Pre-operative unilateral VCP may be asymptomatic in 30–40% of cases. In this situation, presence of the residual motor innervation for the vocal cords may be the potent factor. If an electrophysiologic activity was detected in a paralyzed RLN, anatomical integrity of the nerve should be preserved ipsilaterally to maintain neural tonus and prevent vocal cord atrophy.<sup>[45,46]</sup>

The complex motor innervation pattern of the larynx which has been demonstrated also functionally with studies of IONM, explains that voice, respiration, and swallowing changes after RLN and/or EBSLN injury in thyroidectomy may be variable and unpredictable.

### Etiology of RLN Injury

In addition to recognition of RLN injury, IONM helps to find the etiology and point of the injury. Before the invention of IONM, transection or clamping injuries were presumed as the most frequent etiological factors for RLN injury. With the invention of IONM, traction trauma was demonstrated as the most common etiological factor for RLN injury and its incidence is ranging between 67% and 93% in all RLN injuries.<sup>[47-49]</sup>

In a study by Dionigi et al., the etiological factors of injury were analyzed for 281 RLNs out of 3143 patients (6093 nerves under risk of injury) who underwent thyroidectomy. The most common etiological factor was traction trauma (71%), followed by thermal injury (17%), compression injury (4.2%), clamping injury (3.4%), ligature (1.6%), aspiration (1.4%), and transection (1.4%). Most of the traction traumas resulted with transient VCP and the rate of permanent VCP was only 1.4%. In addition, the rate of permanent VCP was 28% for thermal, 50% for clamping, and 100% for transection injuries.<sup>[50]</sup> Contrary to RLN, more than 50% of EBSLN injuries were caused by transection.<sup>[39]</sup>

### Electrophysiologic Evidences Related with RLN Paralysis

LOS was described as obtaining an amplitude of  $<100 \mu\text{V}$  with stimulation of the vagus with a current over vagal threshold (1–2 mA), when the baseline amplitude was  $>500 \mu\text{V}$ .<sup>[4]</sup>

**Type 1 LOS:** During stimulation of RLN, signal cannot be achieved proximal to a specific point over RLN. These injuries were known as Type 1 segmental injuries and a signal can be achieved distal to the point of injury.

**Type 2 LOS:** It is named as Type 2 global injury. There is no point of injury determined electrophysiologically and a signal cannot be achieved along the ipsilateral vagus nerve-RLN axis.<sup>[51]</sup>

After the maneuver leading to LOS is terminated, LOS may persist or recover. At the end of the surgery, if the amplitude increases over  $100 \mu\text{V}$  and is lower than 50% of the baseline amplitude, it is defined as incomplete recovery. If the amplitude is over  $100 \mu\text{V}$  but greater than 50% of the baseline amplitude, then it is defined as complete recovery.<sup>[52]</sup>

Type 1 LOS results with a more serious injury and is more frequent in female population. Both in type 1 and type 2 LOS, major cause of injury is the traction trauma. When LOS persists, 95% of type 1 injuries and 70% of type 2 injuries result with post-operative VCP. Two-thirds of Type 1 LOS are superior to the crossing point of RLN and inferior thyroid artery (ITA). In both types of LOS, 90% of VCP recover in 6 months.<sup>[51]</sup>

In patients with intraoperative incomplete recovery of LOS, post-operative VCP was occurred in 95% of type 1 LOS and 48% of type 2 LOS. Complete recovery of LOS resulted with no post-operative VCP both in type 1 and type 2 LOS.<sup>[53]</sup> Wu et al.<sup>[54]</sup> demonstrated that amplitude loss more than 60% at the proximal region below the point of LOS compared to the amplitude at the distal region above the point of LOS is associated with VCP. After LOS, complete recovery occurs by 7–8 min in Type 1 LOS and 13–16 min in Type 2 LOS.<sup>[52,53]</sup> LOS caused by traction trauma may recover intraoperatively in 20 min in 70% of injured nerves, if the traction is released.<sup>[55]</sup> At the end of 20 min of waiting period after LOS, if an incomplete signal recovery occurs and amplitude still remains below the 50% of baseline amplitude, the risk of post-operative VCP is 70–80%.<sup>[52,53]</sup> VCP is transient in patients with complete recovery of signal and no permanent VCP is seen in these patients.<sup>[53]</sup> Median recovery time for VCP is 62 days for type 1 LOS and 27 days for type 2 LOS.<sup>[52]</sup>

The INMSG recommends that when evaluating signal recovery absolute amplitude level must be considered to-

gether with an increase of more than 50% of baseline amplitude. With an amplitude level  $>250 \mu\text{V}$  possibility of post-operative normal vocal cord function is high, however, with an amplitude level  $<250 \mu\text{V}$ , there is still a possibility for post-operative VCP. As a result, having an absolute amplitude level  $>250 \mu\text{V}$  together with a final amplitude, more than 50% of baseline amplitude were recommended for assessment of signal recovery.<sup>[14]</sup>

### Evidence Related with Traction Trauma

Traction trauma which is the most common cause of RLN injury in thyroid surgery appears gradually in a certain amount of time. At the first phase of traction injury, amplitude is decreasing due to the decrease in the number of nerve fibers transmitting the action potential. With continuation of traction, amplitude keeps on decreasing and the increase of latency becomes evident due to the loss of myelin sheath.<sup>[56]</sup>

Related with traction trauma, a decrease of amplitude  $>50\%$  together with an increase of latency  $>10\%$  is defined as combined event. These events can be followed simultaneously using C-IONM in a proper way. Combined events are critical EMG changes that can be reversible in 80% of cases when the action leading to the traction trauma is terminated. If the nerve is not released, LOS develops and the chance of recovery is less. EMG changes in only amplitude or latency are mostly related with the endotracheal tube malrotation or problems with equipment and do not predict VCP. Possible VCP can be prevented when the traction trauma developing LOS on RLN is terminated in a favorable time.<sup>[11,57,58]</sup>

### Intraoperative Detection of RLN Injury

Only 15% of RLN injuries can be detected by visible physical changes.<sup>[48,59]</sup> In approximately 85% of RLN injuries, nerves are visually intact and injury site can be localized functionally using IONM. Whether RLN injury is visible or not is related to prognosis of VCP. While the rate of permanent VCP is 56% in RLN injury with physical changes, permanent VCP is very low (1.2%) in RLNs without physical changes.<sup>[50]</sup>

Mapping of RLN with IONM and intraoperative detection of RLN injury make an important contribution to the RLN-related surgical strategy. If RLN was ligated with a clip or suture or compressed by a fibrous tissue, risk of permanent paralysis can be prevented by the surgeon after elimination of underlying condition. Furthermore, IONM helps finding the distal part of the RLN, if the nerve is transected unintentionally. In addition, it is also useful to find the motor branch or branches of branching RLNs for an anastomosis.<sup>[46]</sup>

### Prediction of Post-Operative Vocal Cord Function by Intermittent IONM (I-IONM)

Approximately 7000 nerves were evaluated in a meta-analysis and sensitivity was 83.76%, specificity was 90.24%, positive predictive value was 61.3%, and negative predictive value was 99.15% for I-IONM.<sup>[60]</sup>

In another study, standard vagal stimulation was applied in compliance with the International Neuromonitoring Guideline statements and sensitivity increased to 92%, specificity increased to 99.3, positive predictive value increased to 76.7%, and negative predictive value increased to 99.8%.<sup>[61]</sup>

### Prevention of Bilateral VCP

Bilateral VCP is one of the life-threatening and most feared complications of thyroidectomy. One of the most important evidence about IONM is its ability to prevent bilateral VCP.<sup>[62]</sup> When LOS developed at the first side of intervention in a patient planned for total thyroidectomy, bilateral VCP is not going to occur with a surgical plan of staged thyroidectomy.<sup>[62,63]</sup> However, without noticing LOS or continuing to the contralateral side of the neck despite LOS, the procedure may conclude with bilateral VCP in 16–17% of cases.<sup>[64,65]</sup> Over 99% of negative predictive value of IONM is an indicator of eliminating the possibility of bilateral VCP if no LOS develops after resection of the first side and a normal EMG signal is obtained.<sup>[61]</sup>

Positive predictive value of IONM is about 60–75%. When LOS develops on the first side of the intervention, postoperatively, normal vocal cord function may be seen due to the false positivity. Thus, this value may be accepted as a rational for staged thyroidectomy to prevent bilateral VCP.<sup>[61]</sup>

### Limitations of I-IONM

Even though I-IONM is an effective method for finding of RLN, mapping its anatomical course, showing type and localization of LOS, and preventing bilateral VCP, this technique has limitations.

I-IONM does not provide a simultaneous functional monitoring throughout RLN and only gives information about function at the moment of stimulation. Current systems do not allow surgeon to dissect and stimulate at the same time. I-IONM does not give information about outcomes of surgical manipulations between two stimulation. If an injury was occurred by surgical manipulation, I-IONM has no impact on preventing this injury and stimulation after surgical manipulation only shows that an injury was occurred. I-IONM informs about function of distal part of the nerve to the point of stimulation and cannot determine if there is a Type 1 injury proximal to the point of stimula-

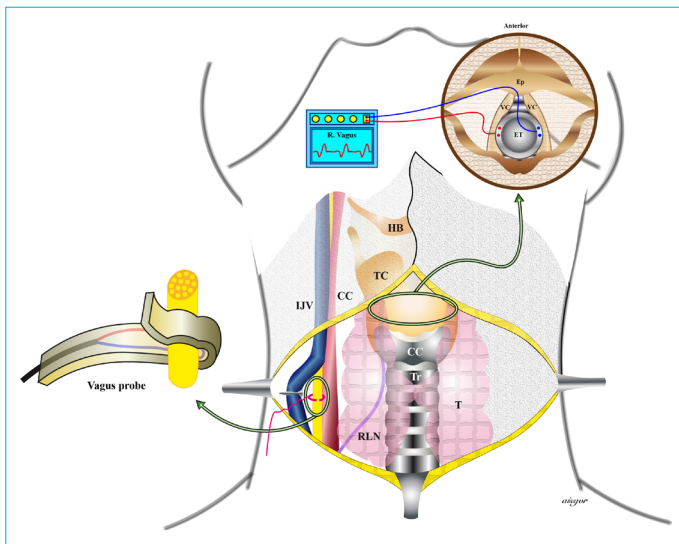
tion in RLN-vagus nerve axis. This injury can be detected by stimulating proximally to the point of injury.<sup>[56,66]</sup>

### C-IONM

C-IONM is a technique based on following the changes in amplitude and latency of EMG signals through periodical stimulations of vocal cords by applying a probe to the vagus nerve at the level of middle zone of thyroid gland and evaluating functional integrity of vagus nerve-RLN axis simultaneously (Fig. 2).<sup>[11,67]</sup>

Traction trauma which is the most common cause of RLN injury is progressive and a certain time passes until LOS develops. During that timeline, EMG amplitude changes of RLN synchronously alert the surgeon and enable the surgeon to correct surgical manipulations. EMG findings may recover after waiting for an adequate time and terminating the maneuver leading to the traction trauma. As combined events (more than 50% decrease in the baseline amplitude and more than 10% increase of latency) or LOS are emerged after traction trauma, surgical manipulation should be terminated and wait for 20 min.<sup>[11]</sup>

When amplitude values are lower than 50% of baseline amplitude, the possibility of VCP is 100% for Type 1 and 67% for Type 2 LOS and these numbers are closer to the rates of persistent LOS (100% and 75%, respectively). In patients with a plan of total thyroidectomy, staged thyroidectomy



**Figure 2.** Schematic view of continuous intraoperative neuromonitorization by vagus (Ep: Epiglottis, VC: Vocal cord, ET: Endotracheal tube, R. Side: Right side, HB: Hyoid bone, TC: thyroid cartilage, CC: cricoid cartilage, IJV: Internal jugular vein, CC: Common carotid artery, RLN: Recurrent laryngeal nerve, T: Thyroid, Tr: Trachea, Right upper arrow: Transverse section of larynx at the level of vocal cords and the position of surface electrode-based endotracheal tube placed between vocal cords, Right lower arrow: Schematic view of application of semi-closed vagus probe after dissection of vagus).

should be planned if this happens on the first side of intervention. When complete signal recovery (an increase of amplitude to the level more than 50% of baseline amplitude) is observed, this situation is related with normal vocal cord function and operation can be continued on contralateral side.<sup>[11,52]</sup>

The other etiological factors of RLN injury such as cauterization, clamping, ligature, transection occur with sudden actions and these actions may not be prevented by C-IONM.<sup>[68,69]</sup>

According to the registry of the German Society of General and Visceral Surgery in which IONM is used widely in thyroidectomy, only 17.4% of surgeons perform thyroidectomy using C-IONM.<sup>[70]</sup>

In a study comparing I-IONM and C-IONM including more than 6000 patients and 10,200 RLNs, C-IONM was found superior for preventing VCP. In C-IONM group, early VCP was 1.7 times lower than I-IONM group (1.5% vs. 2.5%, respectively) and permanent VCP was 30 times lower than I-IONM group (0.02% vs. 0.6%, respectively). When C-IONM compared to I-IONM in multivariable logistic regression analysis, the use of C-IONM was detected as an independent factor for decreasing early VCP 1.8-fold (OR:0.56) and decreasing permanent VCP 29.4-fold (OR:0.034). With the use of C-IONM, only one out of 75 early VCP was observed as permanent VCP and with the use of I-IONM, one out of 4.2 early VCP was observed as permanent VCP. The possibility of developing permanent VCP after early VCP was found 17.9-fold lower in C-IONM group.<sup>[71]</sup>

For the prediction of both early post-operative and permanent VCP, C-IONM was detected to be better than I-IONM in a broad study by Schneider et al. In C-IONM and I-IONM, for the prediction of early post-operative VCP, the sensitivity was 88.5% versus 52.4%, specificity was 99.6% versus 99.2%, positive predictive value was 79.3% versus 61.9%, negative predictive value was 99.8% versus 98.8%, and accuracy was 99.5% versus 98.0%, respectively. In C-IONM and I-IONM; for the prediction of permanent VCP; the sensitivity was 100.0% versus 51.7%, specificity was 98.3% versus 98.2%, negative predictive value was 100.0% versus 99.7%, and accuracy was 98.3% versus 97.9%, respectively. However, positive predictive value was lower in C-IONM compared to I-IONM (1.1% vs. 14.3%, respectively, one permanent VCP related with C-IONM).<sup>[71]</sup>

Even C-IONM has some limitations. First of all, further dissection is applied and additional time is spent for placement of C-IONM probe to the vagus nerve. Another limitation of C-IONM may be related with lack of standardization. There is a great variety among the criteria of alarm thresholds in the literature. Even though there is an increase in

centers and surgeons who use this technique, a standard method is not formed yet. When well-known advantages of C-IONM are taken into account, sufficient training to perform a safe operation with C-IONM is still resuming as the gold standard. There are no data regarding the learning curve of the technique to be used in C-IONM.<sup>[72]</sup>

### Monitorization of External Branch of the Superior Laryngeal Nerve

Despite visual identification is the gold standard technique for preservation of RLN, the best method is still on debate among various proposed techniques for preservation of EBSLN.<sup>[13]</sup> At present, many surgeons perform dissections without searching for EBSLN considering that searching for it is invasive and dangerous.<sup>[73]</sup> However, upper pole dissection with IONM is increasing but still fewer than its use in RLN.<sup>[74,75]</sup>

Main principle for preservation of a peripheral nerve is meticulous dissection and visualization of the nerve. Since EBSLN is thinner than RLN and may be under or among the fibers of inferior pharyngeal constrictor muscle, it may not be identified or non-neural muscle fibers may be presumed as EBSLN.<sup>[76,77]</sup>

IONM makes a significant contribution to the visual and functional identification of EBSLN during the upper pole dissection. Uludag et al.<sup>[78]</sup> reported that IONM increased the visual detection rate of EBSLN from 36.9% to 70% and 25.2% of nerves were functionally detected even though nerves were not visualized.

EBSLN is closely related to the upper pole vessels and most popular categorization to describe this relationship is Cernea classification.<sup>[79]</sup>

Upper pole vessels are in a relationship with EBSLN which is categorized as; Cernea type 1, 24–31% of thyroidectomies (EBSLN crosses upper pole vessels at a point more than 1 cm superior to upper pole), Cernea type 2a, 60–68% of thyroidectomies (EBSLN crosses upper pole vessels at a point <1 cm superior to upper pole), and Cernea type 2b, 7–9% of thyroidectomies (EBSLN crosses upper pole vessels below the upper pole superior border). Practically, during the upper pole dissection, approximately 75% of EBSLNs are close to upper pole <1 cm (Cernea type 2a+2b) and under potential risk of injury.<sup>[39,78,80]</sup>

In a prospective study, Cernea classification is found to be associated with the stress on EBSLN during the upper pole dissection. Ratio of nerves with a reduction of amplitude at the end of the upper pole dissection was more than 25% of amplitude of stimulation at identification which were 4.9% in Cernea type 1, 11.2% in Cernea type 2a, and 18% in Cernea type 2b and LOS ratio was 0%, 2.8%, and 3%, respec-

tively. Furthermore, authors suggested that stimulation of the EBSLN when nerve is identified should be defined as S1 and stimulation of EBSLN proximally to the point of vessel transection at the end of the dissection should be defined as S2 similar to the standardization of RLN.<sup>[81]</sup>

Significant reduction of EBSLN injury with the use of IONM during upper pole dissection has been demonstrated in various randomized prospective studies. Cernea evaluated EBSLN injury using post-operative EMG of CTM in his randomized prospective studies. EBSLN injury rate was 28% when surgery residents operate the patient without searching for EBSLN, 12% when experienced attending surgeon operate without searching for EBSLN and there was no injury when experienced attending surgeon search for the nerve with a nerve stimulator.<sup>[82]</sup>

Barczynski et al. evaluated voice performances with post-operative videostrobolaryngoscopy and vocal tests in randomized prospective studies. During the upper pole dissection, total EBSLN injury rate was higher in the group in which nerves were searched with visual inspection than the group in which nerves were searched with IONM (6% vs. 1.5%,  $p=0.02$ ), and more than 10% of reduction in phonation parameters were detected.<sup>[36]</sup>

In another prospective study, EBSLN injury was evaluated with intraoperative EMG of CTM and the number of injured EBSLNs in the group in which IONM was used during upper pole dissection was found to be lower than number of nerves at risk of injury in the group in which nerves were not searched during the dissection (0.9% vs. 8.6%,  $p=0.010$ ).<sup>[39]</sup>

Routine use of IONM for identification of EBSLN during thyroidectomy can minimize the risk of injury. More than 50% decrease in at least one of the EBSLN amplitude response in the EMG of CTM performed by needle electrodes is related with poor vocal outcome.<sup>[83]</sup> True positivity of EBSLN stimulation in IONM is described as observing a twitch on CTM and/or recording an endotracheal glottic waveform by endotracheal tube electrodes.<sup>[13]</sup>

One of the main limitations of EBSLN monitorization is the lack of continuous monitorization due to the fact that EBSLN is branching from vagus nerve at a very short distance from cranial base. Although a glottic response is taken in majority of patients through the human communicating nerve, at least in 20% of patients, a quantitative response cannot be achieved. The correlation between magnitude of EMG amplitude achieved from the vocal cords and the function of EBSLN is yet not known.<sup>[13]</sup>

### Disclosures

**Peer-review:** Externally peer-reviewed.

**Conflict of Interest:** None declared.

**Authorship Contributions:** Concept – N.A., M.K, A.I., M.U.; Design – N.A., M.K, A.I., M.U.; Supervision – A.I., M.U.; Materials – N.A., M.K, A.I., M.U.; Data collection &/or processing – N.A., M.K, M.U.; Analysis and/or interpretation – N.A., M.K, A.I., M.U.; Literature search – N.A., M.K, A.I., M.U.; Writing – N.A., M.K, A.I., M.U.; Critical review –A.I., M.U.

## References

- Grover G, Sadler GP, Mihai R. Morbidity after thyroid surgery: patient perspective. *Laryngoscope* 2013;123:2319–23. [CrossRef]
- Nam IC, Park YH. Pharyngolaryngeal symptoms associated with thyroid disease. *Curr Opin Otolaryngol Head Neck Surg* 2017;25:469–74. [CrossRef]
- Lahey FH, Hoover WB. Injuries to the recurrent laryngeal nerve in thyroid operations: their management and avoidance. *Ann Surg* 1938;108:545–62. [CrossRef]
- Randolph GW, Dralle H; International Intraoperative Monitoring Study Group, Abdullah H, Barczynski M, Bellantone R, Brauckhoff M, et al. Electrophysiologic recurrent laryngeal nerve monitoring during thyroid and parathyroid surgery: international standards guideline statement. *Laryngoscope* 2011;121 Suppl 1:S1–16.
- Shedd DP, Durham C. Electrical identification of the recurrent laryngeal nerve. I. Response of the canine larynx to electrical stimulation of the recurrent laryngeal nerve. *Ann Surg* 1966;163:47–50.
- Riddell V. Thyroidectomy: prevention of bilateral recurrent nerve palsy. Results of identification of the nerve over 23 consecutive years (1946–69) with a description of an additional safety measure. *Br J Surg* 1970;57:1–11. [CrossRef]
- Eisele DW. Intraoperative electrophysiologic monitoring of the recurrent laryngeal nerve. *Laryngoscope* 1996;106:443–9. [CrossRef]
- Lamade W, Fogel W, Rieke K, Senninger N, Herfarth C. Intraoperative monitoring of the recurrent laryngeal nerve. A new method. [Article in German]. *Chirurg* 1996;67:451–4.
- Lamadé W, Meyding-Lamadé U, Hund E, Senninger N, Herfarth C. Transtracheal monitoring of the recurrent laryngeal nerve. Prototype of a new tube. [Article in German]. *Chirurg* 1997;68:193–5.
- Lamadé W, Ulmer C, Seimer A, Molnar V, Meyding-Lamadé U, Thon KP, et al. A new system for continuous recurrent laryngeal nerve monitoring. *Minim Invasive Ther Allied Technol* 2007;16:149–54.
- Schneider R, Lorenz K, Machens A, Thanh PN, Randolph GW, Dralle H. Continuous intraoperative neuromonitoring (CIONM) of the recurrent laryngeal nerve. In: Randolph GW, editor. *The Recurrent and Superior Laryngeal Nerves*. 1st ed. Switzerland: Springer International Publishing AG; 2016. p. 169–83. [CrossRef]
- International Neural Monitoring Study Group (INMSG). Available at: <http://www.inmsg.org>. Accessed Jun 07, 2021.
- Barczyński M, Randolph GW, Cernea CR, Dralle H, Dionigi G, Alesina PF, et al; International Neural Monitoring Study Group. External branch of the superior laryngeal nerve monitoring during thyroid and parathyroid surgery: International Neural Monitoring Study Group standards guideline statement. *Laryngoscope* 2013;123 Suppl 4:S1–14. [CrossRef]
- Schneider R, Randolph GW, Dionigi G, Wu CW, Barczynski M, Chiang FY, et al. International neural monitoring study group guideline 2018 part I: Staging bilateral thyroid surgery with monitoring loss of signal. *Laryngoscope* 2018;128 Suppl 3:S1–17.
- Wu CW, Dionigi G, Barczynski M, Chiang FY, Dralle H, Schneider R, et al. International neuromonitoring study group guidelines 2018: Part II: Optimal recurrent laryngeal nerve management for invasive thyroid cancer-incorporation of surgical, laryngeal, and neural electrophysiologic data. *Laryngoscope* 2018;128 Suppl 3:S18–27.
- Chiang FY, Lu IC, Chen HC, Chen HY, Tsai CJ, Lee KW, et al. Intraoperative neuromonitoring for early localization and identification of recurrent laryngeal nerve during thyroid surgery. *Kaohsiung J Med Sci* 2010;26:633–9. [CrossRef]
- Anuwong A, Lavazza M, Kim HY, Wu CW, Rausei S, Pappalardo V, et al. Recurrent laryngeal nerve management in thyroid surgery: consequences of routine visualization, application of intermittent, standardized and continuous nerve monitoring. *Updates Surg* 2016;68:331–41. [CrossRef]
- Wojtczak B, Sutkowski K, Kaliszewski K, Barczyński M, Bolanowski M. Thyroid reoperation using intraoperative neuromonitoring. *Endocrine* 2017;58:458–66. [CrossRef]
- Henry BM, Vikse J, Graves MJ, Sanna S, Sanna B, Tomaszewska IM, et al. Extralaryngeal branching of the recurrent laryngeal nerve: a meta-analysis of 28,387 nerves. *Langenbecks Arch Surg* 2016;401:913–23. [CrossRef]
- Henry BM, Sanna S, Graves MJ, Vikse J, Sanna B, Tomaszewska IM, et al. The Non-Recurrent Laryngeal Nerve: a meta-analysis and clinical considerations. *PeerJ* 2017;5:e3012. [CrossRef]
- Kandil E, Anwar MA, Bamford J, Aslam R, Randolph GW. Electrophysiological identification of nonrecurrent laryngeal nerves. *Laryngoscope* 2017;127:2189–93. [CrossRef]
- Brauckhoff M, Machens A, Sekulla C, Lorenz K, Dralle H. Latencies shorter than 3.5 ms after vagus nerve stimulation signify a nonrecurrent inferior laryngeal nerve before dissection. *Ann Surg* 2011;253:1172–7. [CrossRef]
- Zeale DL, Billante CR. Neurophysiology of vocal fold paralysis. *Otolaryngol Clin North Am* 2004;37:1–23. [CrossRef]
- Martin-Oviedo C, Marañillo E, Lowy-Benoliel A, Pascual-Font A, Martínez-Guirado T, Rodríguez-Niedenführ M, et al. Functional role of human laryngeal nerve connections. *Laryngoscope* 2011;121:2338–43. [CrossRef]
- Sañudo JR, Marañillo E, León X, Mirapeix RM, Orús C, Quer M. An anatomical study of anastomoses between the laryngeal nerves. *Laryngoscope* 1999;109:983–7. [CrossRef]
- Uludag M, Aygün N, Işgor A. Innervation of the human cricopharyngeal muscle by the recurrent laryngeal nerve and external branch of the superior laryngeal nerve. *Langenbecks Arch Surg* 2017;402:683–90. [CrossRef]
- Serpell JW, Yeung MJ, Grodski S. The motor fibers of the recurrent



- laryngeal nerve are located in the anterior extralaryngeal branch. *Ann Surg* 2009;249:648–52. [\[CrossRef\]](#)
28. Kandil E, Abdelghani S, Friedlander P, Alrasheedi S, Tufano RP, Bellows CF, et al. Motor and sensory branching of the recurrent laryngeal nerve in thyroid surgery. *Surgery* 2011;150:1222–7.
  29. Cho I, Jo MG, Choi SW, Jang JY, Wang SG, Cha W. Some posterior branches of extralaryngeal recurrent laryngeal nerves have motor fibers. *Laryngoscope* 2017;127:2678–85. [\[CrossRef\]](#)
  30. Uludag M, Aygun N, Isgor A. Motor function of the recurrent laryngeal nerve: Sometimes motor fibers are also located in the posterior branch. *Surgery* 2016;160:153–60. [\[CrossRef\]](#)
  31. Masuoka H, Miyauchi A, Yabuta T, Fukushima M, Miya A. Innervation of the cricothyroid muscle by the recurrent laryngeal nerve. *Head Neck* 2016;38 Suppl 1:E441–5. [\[CrossRef\]](#)
  32. Miyauchi A, Masuoka H, Nakayama A, Higashiyama T. Innervation of the cricothyroid muscle by extralaryngeal branches of the recurrent laryngeal nerve. *Laryngoscope* 2016;126:1157–62. [\[CrossRef\]](#)
  33. Wu BL, Sanders I, Mu L, Biller HF. The human communicating nerve. An extension of the external superior laryngeal nerve that innervates the vocal cord. *Arch Otolaryngol Head Neck Surg* 1994;120:1321–8. [\[CrossRef\]](#)
  34. Marañillo E, León X, Quer M, Orús C, Sañudo JR. Is the external laryngeal nerve an exclusively motor nerve? The cricothyroid connection branch. *Laryngoscope* 2003;113:525–9. [\[CrossRef\]](#)
  35. Aygün N, Uludağ M, İsgör A. Contribution of intraoperative neuromonitoring to the identification of the external branch of superior laryngeal nerve. *Turk J Surg* 2017;33:169–74. [\[CrossRef\]](#)
  36. Barczyński M, Konturek A, Stopa M, Honowska A, Nowak W. Randomized controlled trial of visualization versus neuromonitoring of the external branch of the superior laryngeal nerve during thyroidectomy. *World J Surg* 2012;36:1340–7. [\[CrossRef\]](#)
  37. Aygün N, Besler E, Celayir F, Bozdağ E, Çitgez B, Yetkin G, et al. The effect of the intraoperative neuromonitoring to the external branch of the superior laryngeal nerve identification and contribution of the nerve to the motor function of the thyroaritenoid muscle. *Sisli Etfal Hastan Tip Bul* 2016;50:97–102. [\[CrossRef\]](#)
  38. Potenza AS, Phelan EA, Cernea CR, Slough CM, Kamani DV, Darr A, et al. Normative intra-operative electrophysiologic waveform analysis of superior laryngeal nerve external branch and recurrent laryngeal nerve in patients undergoing thyroid surgery. *World J Surg* 2013;37:2336–42. [\[CrossRef\]](#)
  39. Uludag M, Aygun N, Kartal K, Citgez B, Besler E, Yetkin G, et al. Contribution of intraoperative neural monitoring to preservation of the external branch of the superior laryngeal nerve: a randomized prospective clinical trial. *Langenbecks Arch Surg* 2017;402:965–76. [\[CrossRef\]](#)
  40. Uludag M, Aygun N, Kartal K, Besler E, Isgor A. Innervation of the human posterior cricoarytenoid muscle by the external branch of the superior laryngeal nerve. *Head Neck* 2017;39:2200–7. [\[CrossRef\]](#)
  41. Uludag M, Aygun N, Isgor A. The functional role of the pharyngeal plexus in vocal cord innervation in humans. *Eur Arch Otorhinolaryngol* 2017;274:1121–8. [\[CrossRef\]](#)
  42. Lorenz K, Abuazab M, Sekulla C, Schneider R, Nguyen Thanh P, Dralle H. Results of intraoperative neuromonitoring in thyroid surgery and preoperative vocal cord paralysis. *World J Surg* 2014;38:582–91. [\[CrossRef\]](#)
  43. Kamani D, Darr EA, Randolph GW. Electrophysiologic monitoring characteristics of the recurrent laryngeal nerve preoperatively paralyzed or invaded with malignancy. *Otolaryngol Head Neck Surg* 2013;149:682–8. [\[CrossRef\]](#)
  44. Chi SY, Lammers B, Boehner H, Pohl P, Goretzki PE. Is it meaningful to preserve a palsied recurrent laryngeal nerve? *Thyroid* 2008;18:363–6. [\[CrossRef\]](#)
  45. Uludag M, Yetkin G, Oran ES, Aygun N, Celayir F, Kartal A, et al. A palsied recurrent laryngeal nerve should be explored and evaluated by intraoperative neuromonitoring during secondary thyroidectomy: report of two cases. *Surg Today* 2015;45:1436–41.
  46. Uludağ M, Tanal M, İsgör A. A review of methods for the preservation of laryngeal nerves during thyroidectomy. *Sisli Etfal Hastan Tip Bul* 2018;52:79–91. [\[CrossRef\]](#)
  47. Snyder SK, Lairmore TC, Hendricks JC, Roberts JW. Elucidating mechanisms of recurrent laryngeal nerve injury during thyroidectomy and parathyroidectomy. *J Am Coll Surg* 2008;206:123–30.
  48. Chiang FY, Lu IC, Kuo WR, Lee KW, Chang NC, Wu CW. The mechanism of recurrent laryngeal nerve injury during thyroid surgery—the application of intraoperative neuromonitoring. *Surgery* 2008;143:743–9. [\[CrossRef\]](#)
  49. Dionigi G, Alesina PF, Barczynski M, Boni L, Chiang FY, Kim HY, et al. Recurrent laryngeal nerve injury in video-assisted thyroidectomy: lessons learned from neuromonitoring. *Surg Endosc* 2012;26:2601–8. [\[CrossRef\]](#)
  50. Dionigi G, Wu CW, Kim HY, Rausei S, Boni L, Chiang FY. Severity of recurrent laryngeal nerve injuries in thyroid surgery. *World J Surg* 2016;40:1373–81. [\[CrossRef\]](#)
  51. Schneider R, Randolph G, Dionigi G, Barczyński M, Chiang FY, Triponoz F, et al. Prospective study of vocal fold function after loss of the neuromonitoring signal in thyroid surgery: The International Neural Monitoring Study Group's POLT study. *Laryngoscope* 2016;126:1260–6. [\[CrossRef\]](#)
  52. Schneider R, Sekulla C, Machens A, Lorenz K, Thanh PN, Dralle H. Dynamics of loss and recovery of the nerve monitoring signal during thyroidectomy predict early postoperative vocal fold function. *Head Neck* 2016;38 Suppl 1:E1144–51. [\[CrossRef\]](#)
  53. Schneider R, Randolph G, Dionigi G, Barczynski M, Chiang FY, Wu CW, et al. Prediction of postoperative vocal fold function after intraoperative recovery of loss of signal. *Laryngoscope* 2019;129:525–31. [\[CrossRef\]](#)
  54. Wu CW, Hao M, Tian M, Dionigi G, Tufano RP, Kim HY, et al. Recurrent laryngeal nerve injury with incomplete loss of electromyography signal during monitored thyroidectomy—evaluation and outcome. *Langenbecks Arch Surg* 2017;402:691–9. [\[CrossRef\]](#)
  55. Liu MY, Chang CP, Hung CL, Hung CJ, Huang SM. Traction injury

- of recurrent laryngeal nerve during thyroidectomy. *World J Surg* 2020;44:402–7. [CrossRef]
56. Schneider R, Machens A, Lorenz K, Dralle H. Intraoperative nerve monitoring in thyroid surgery-shifting current paradigms. *Gland Surg* 2020;9:S120–8. [CrossRef]
57. Schneider R, Randolph GW, Sekulla C, Phelan E, Thanh PN, Bucher M, et al. Continuous intraoperative vagus nerve stimulation for identification of imminent recurrent laryngeal nerve injury. *Head Neck* 2013;35:1591–8. [CrossRef]
58. Phelan E, Schneider R, Lorenz K, Dralle H, Kamani D, Potenza A, et al. Continuous vagal IONM prevents recurrent laryngeal nerve paralysis by revealing initial EMG changes of impending neuropraxic injury: a prospective, multicenter study. *Laryngoscope* 2014;124:1498–505. [CrossRef]
59. Bergenfelz A, Jansson S, Kristoffersson A, Mårtensson H, Reihner E, Wallin G, et al. Complications to thyroid surgery: results as reported in a database from a multicenter audit comprising 3,660 patients. *Langenbecks Arch Surg* 2008;393:667–73. [CrossRef]
60. Malik R, Linos D. Intraoperative neuromonitoring in thyroid surgery: a systematic review. *World J Surg* 2016;40:2051–8. [CrossRef]
61. Stopa M, Barczyński M. Prognostic value of intraoperative neural monitoring of the recurrent laryngeal nerve in thyroid surgery. *Langenbecks Arch Surg* 2017;402:957–64. [CrossRef]
62. Kartal K, Aygün N, Celayir MF, Besler E, Citgez B, Işgor A, et al. Intraoperative neuromonitoring in thyroid surgery: an efficient tool to avoid bilateral vocal cord palsy. *Ear Nose Throat J* 2020;145561320906325. [CrossRef]
63. Gür EO, Hacıyanlı M, Karaisli S, Hacıyanlı S, Kamer E, Acar T, et al. Intraoperative nerve monitoring during thyroidectomy: evaluation of signal loss, prognostic value and surgical strategy. *Ann R Coll Surg Engl* 2019;101:589–95.
64. Goretzki PE, Schwarz K, Brinkmann J, Wirowski D, Lammers BJ. The impact of intraoperative neuromonitoring (IONM) on surgical strategy in bilateral thyroid diseases: is it worth the effort? *World J Surg* 2010;34:1274–84. [CrossRef]
65. Melin M, Schwarz K, Lammers BJ, Goretzki PE. IONM-guided goiter surgery leading to two-stage thyroidectomy—indication and results. *Langenbecks Arch Surg* 2013;398:411–8. [CrossRef]
66. Dionigi G, Dralle H, Liddy W, Kamani D, Kyriazidis N, Randolph GW. IONM of the Recurrent Laryngeal Nerve. In: Randolph GW, editors. *The Recurrent and Superior Laryngeal Nerves*. 1st ed. Switzerland: Springer International Publishing AG; 2016. p. 147–68.
67. Uludag M, Aygün N, Kaya C, Tanal M, Oba S, Işgor A. Basic principles and standardization of intraoperative nerve monitoring in thyroid surgery. *Sisli Etfal Hastan Tip Bul* 2017;51:13–25. [CrossRef]
68. Sinclair CF, Téllez MJ, Ulkatan S. Continuous laryngeal adductor reflex versus intermittent nerve monitoring in neck endocrine surgery. *Laryngoscope* 2021;131:230–6. [CrossRef]
69. Schneider R, Sekulla C, Machens A, Lorenz K, Nguyen Thanh P, Dralle H. Postoperative vocal fold palsy in patients undergoing thyroid surgery with continuous or intermittent nerve monitoring. *Br J Surg* 2015;102:1380–7. [CrossRef]
70. Bartsch DK, Dotzenrath C, Vorländer C, Zielke A, Weber T, Buhr HJ, et al; The StuDoQ/Thyroid Study Group TSS. Current practice of surgery for benign goitre—an analysis of the prospective DGAV StuDoQ|Thyroid registry. *J Clin Med* 2019;8:477. [CrossRef]
71. Schneider R, Machens A, Sekulla C, Lorenz K, Elwerr M, Dralle H. Superiority of continuous over intermittent intraoperative nerve monitoring in preventing vocal cord palsy. *Br J Surg* 2021;108:566–73. [CrossRef]
72. Caruso E, Pino A, Pontin A, Pinto G, Damiano C, Catalfamo A, et al. Limitations of continuous neural monitoring in thyroid surgery. *Sisli Etfal Hastan Tip Bul* 2019;53:81–3. [CrossRef]
73. Hwang SB, Lee HY, Kim WY, Woo SU, Lee JB, Bae JW, et al. The anatomy of the external branch of the superior laryngeal nerve in Koreans. *Asian J Surg* 2013;36:13–9. [CrossRef]
74. Ritter A, Ganly I, Wong RJ, Randolph GW, Shpitzer T, Bachar G, et al. Intraoperative nerve monitoring is used routinely by a significant majority of head and neck surgeons in thyroid surgery and impacts on extent of surgery—Survey of the American Head and Neck Society. *Head Neck* 2020;42:1757–64. [CrossRef]
75. Barczyński M, Randolph GW, Cernea C; International Neural Monitoring Study Group in Thyroid and Parathyroid Surgery. International survey on the identification and neural monitoring of the EBSLN during thyroidectomy. *Laryngoscope* 2016;126:285–91.
76. Selvan B, Babu S, Paul MJ, Abraham D, Samuel P, Nair A. Mapping the compound muscle action potentials of cricothyroid muscle using electromyography in thyroid operations: a novel method to clinically type the external branch of the superior laryngeal nerve. *Ann Surg* 2009;250:293–300. [CrossRef]
77. Lennquist S, Cahlin C, Smeds S. The superior laryngeal nerve in thyroid surgery. *Surgery* 1987;102:999–1008.
78. Uludag M, Aygün N, Kartal K, Besler E, Işgor A. Is intraoperative neural monitoring necessary for exploration of the superior laryngeal nerve? *Surgery* 2017;161:1129–38. [CrossRef]
79. Cernea CR, Ferraz AR, Nishio S, Dutra A Jr, Hojaij FC, dos Santos LR. Surgical anatomy of the external branch of the superior laryngeal nerve. *Head Neck* 1992;14:380–3. [CrossRef]
80. Aygün N, Demircioglu MK, Demircioglu ZG, Akgün IE, Işgor A, Uludag M. Factors influencing the relationship of the external branch of the superior laryngeal nerve with the superior pole vessels of the thyroid gland. *Sisli Etfal Hastan Tip Bul* 2020;54:469–74.
81. Dionigi G, Kim HY, Randolph GW, Wu CW, Sun H, Liu X, et al. Prospective validation study of Cernea classification for predicting EMG alterations of the external branch of the superior laryngeal nerve. *Surg Today* 2016;46:785–91. [CrossRef]
82. Cernea CR, Ferraz AR, Furlani J, Monteiro S, Nishio S, Hojaij FC, et al. Identification of the external branch of the superior laryngeal nerve during thyroidectomy. *Am J Surg* 1992;164:634–9. [CrossRef]
83. Iwata AJ, Liddy W, Barczyński M, Wu CW, Huang TY, Van Slycke S, et al. Superior laryngeal nerve signal attenuation influences voice outcomes in thyroid surgery. *Laryngoscope* 2021;131:1436–42.