



DOI: 10.14744/SEMB.2020.34651

Med Bull Sisli Etfal Hosp 2021;55(2):268–271

Case Report

A Case of Smith-Lemli-Opitz Syndrome Diagnosed with Hypertrophic Pyloric Stenosis

Elif Ece Eren,¹ Nurbanu Bilgin,¹ Nafiye Urganci,² Gulsen Kose³

¹Department of Child Health and Diseases, Sisli Hamidiye Etfal Training and Research Hospital, Istanbul, Turkey

²Department of Pediatric Gastroenterology, Sisli Hamidiye Etfal Training and Research Hospital, Istanbul, Turkey

³Department of Pediatric Neurology, Sisli Hamidiye Etfal Training and Research Hospital, Istanbul, Turkey

Abstract

Smith-Lemli-Opitz syndrome (SLOS) is caused by a deficiency in the enzyme 7-dehydrocholesterol reductase (DHCR7) that results in an abnormality in cholesterol metabolism. SLOS is inherited as an autosomal recessive genetic disorder. In this case, we describe a 34-day-old patient with postnatal progressive projectile vomiting, diagnosed with hypertrophic pyloric stenosis, who was suspected to have SLOS during treatment clinical and biochemical profile. A 34-day-old patient with progressively worsening vomiting and abdominal distention, diagnosed as hypertrophic pyloric stenosis, was operated by pediatric surgery department. After operation, the patient required pediatric intensive care unit admission due to respiratory distress, anemia, hypoalbuminemia, and generalized edema. Physical examination of our patient revealed dysmorphic facial features, finger anomalies, sacral dimple, and ambiguous genitalia, with chromosomal determination as XY. Molecular genetic testing was performed, and mutations in the DHCR7 gene of homozygous c.1342G>A/p.Glu448Lys (rs80338864) were detected. Infants with progressive projectile vomiting, feeding problems, and multiple anomalies with dysmorphic facial anomalies may be suspected to have SLOS and their families should be advised to have genetic testing and genetic counseling.

Keywords: Infantile hypertrophic pyloric stenosis; Smith-Lemli-Opitz syndrome.

Please cite this article as "Eren EE, Bilgin N, Urganci N, Kose G. A Case of Smith-Lemli-Opitz Syndrome Diagnosed with Hypertrophic Pyloric Stenosis. Med Bull Sisli Etfal Hosp 2021;55(2):268–271".

Smith-Lemli-Opitz syndrome (SLOS) is an autosomal recessive congenital disorder of cholesterol metabolism and is observed multiple congenital anomalies.^[1] The last step of cholesterol biosynthesis includes the enzyme delta-7-sterol reductase, which converts 7-dehydrocholesterol to cholesterol. The enzyme deficiency occurs with mutation in the 11q13 chromosome of 7-dehydrocholesterol reductase (DHCR7) gene, which encodes this enzyme. 7-dehydrocholesterol accumulates in tissues and cholesterol deficiency

develops.^[2] Its incidence is between 1/20.000 and 60.000 and is more common in males.^[3] There are two forms: Classical Type 1, which is mildly affected, and Type 2, which has a severe course and causes premature death.^[4] Its clinical manifestations are growth retardation, microcephaly, mental retardation, hypotonia, syndactyly of the 2nd and 3rd toes, polydactyly and genitourinary anomalies, cleft palate, and pyloric stenosis. With this case presentation, a patient who presented with vomiting and was diagnosed with

Address for correspondence: Nafiye Urganci, MD. Sisli Hamidiye Etfal Egitim ve Arastirma Hastanesi, Cocuk Gastroenteroloji Bolumu, Istanbul, Turkey

Phone: +90 542 543 14 94 **E-mail:** nafiyeurganci@yahoo.com

Submitted Date: January 09, 2020 **Accepted Date:** June 01, 2020 **Available Online Date:** July 02, 2021

©Copyright 2021 by The Medical Bulletin of Sisli Etfal Hospital - Available online at www.sislietfaltip.org

OPEN ACCESS This is an open access article under the CC BY-NC license (<http://creativecommons.org/licenses/by-nc/4.0/>).



SLOS Type 2 while being followed up with a pre-diagnosis of pyloric stenosis was examined.

Case Report

The patient was born by cesarean delivery at 38 weeks of gestational week (GW), with a weight of 2590 g, was operated with the diagnosis of hypertrophic pyloric stenosis at the age of 24 days. On the post-operative 6th day, the patient was admitted to the intensive care unit with the pre-diagnosis of sepsis and metabolic disease, due to the development of respiratory distress, generalized edema, anemia, and hypoalbuminemia. It was learned that the baby's parents were second-degree relatives. On examination, the baby had a weight of 2920 g (<3 p), a height of 42 cm (<3 p), and a head circumference of 33 cm (<3 p) and seemed restless. Body temperature was 36.5°, peak heart rate was 142/min, blood pressure was 110/60 mmHg, respiratory rate was 32/min, saturation with oxygen mask was 99%, and it was around 70% with room air. Except for dysmorphic facial features (retromicrognathia, hypertelorism, flat nasal bridge, low-set ears, and cleft palate), six fingers in the right hand (Fig. 1), syndactyly of the 2nd and 3rd toes (Fig. 2), and sacral dimples (Fig. 3) were detected. Ambiguous genitalia (labia minora hypertrophy, conjoined in the midline) was observed in genital examination (Fig. 4). Respiratory sounds were even and natural. Heart sounds were rhythmic and there was a 2/6 pansystolic murmur at the apex and hypotonia on neurological examination. In the laboratory examination, complete blood count, urinalysis, tandem-MS, lactate, pyruvate, blood gas levels, ammonia, biotinidase, Pompe enzyme activity, and gonadal hormone levels were normal. In thyroid function tests, fT4 was found to be 1.07 ng/dl and thyroid-stimulating hormone as 19.55 mU/ml (0.6-4.84 Mu/ml), so treatment was initiated with the diagnosis of hypothyroidism. Serum cholesterol level was detected as 38 mg/dl (<200 mg/dl), high-density lipoprotein as 7 mg/dl (40-80 mg/dl). In pelvic ultrasound (USG), the testicles were located in the inguinal canal and no uterus was observed. In the abdominal USG, intrahepatic bile ducts were observed slightly dilated. Narrowing at two levels of the bile duct (in the common bile duct and proximal common bile duct), enlargement of the common bile duct, Grade-1 ectasia in the right kidney, and increase in the resistive index in the right renal artery were detected. Atrial septal defect and thickening of the cardiac wall were detected on echocardiography. Cholesterol synthesis defect was considered due to low cholesterol levels and dysmorphic findings in the case whose chromosome analysis was found to be consistent with XY. In the whole sequence exon analysis, a homozygous c.1342G>A/p.Glu448Lys (rs80338864) mutation was detected in the DHCR7

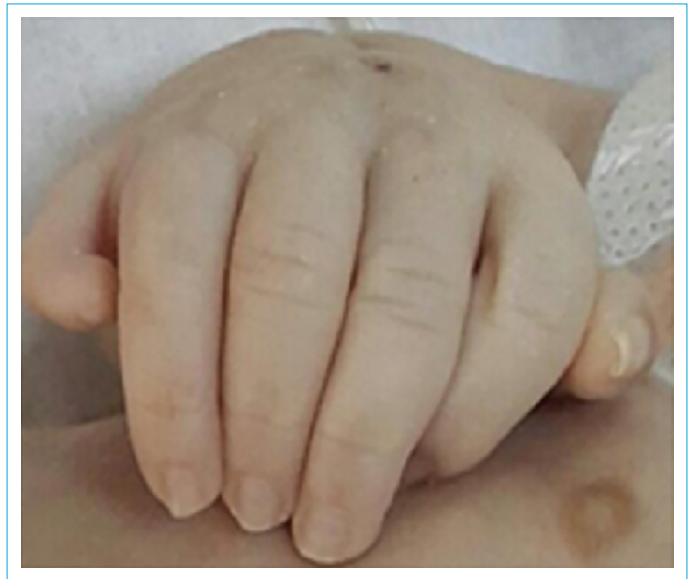

Figure 1. Six fingers in the right hand.

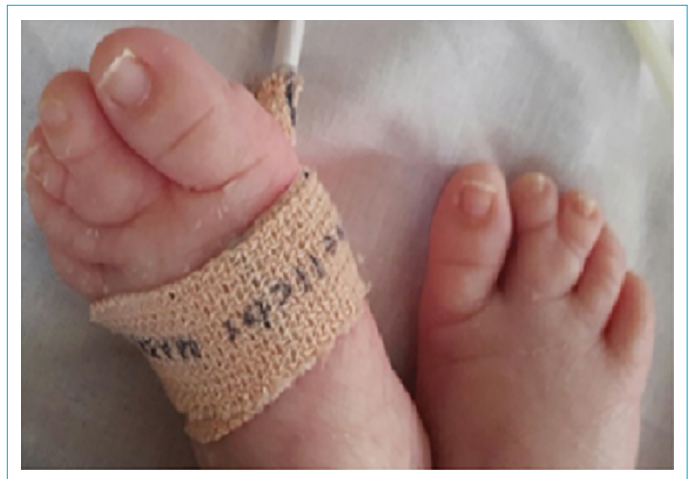

Figure 2. Bilateral syndactyly of 2–3 toes.

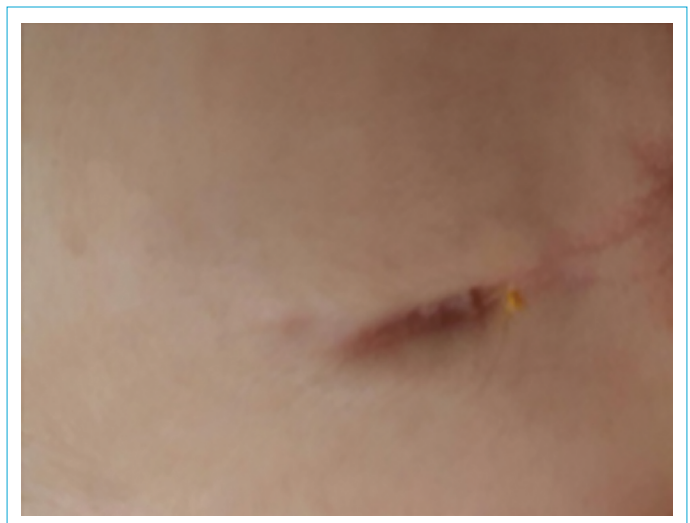

Figure 3. Sacral dimple.

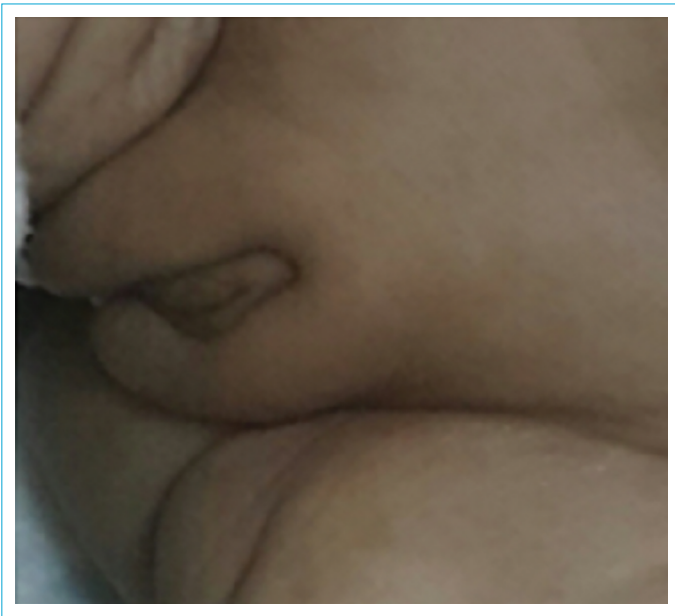


Figure 4. Ambiguous genitalia.

gene. The patient was diagnosed with SLOS based on clinical features and genetic analysis. A diet rich in bile acid, cholesterol extract, and cholesterol was planned. Antihypertensive treatment was started due to the development of hypertension and thickening of the cardiac wall in the follow-up. Total parenteral nutrition was started with minimal enteral nutrition in the patient who rapidly developed hypertrophic cardiomyopathy and could not tolerate enteral intake. General condition of the patient worsened with increasing abdominal distention in intensive care unit follow-up. The patient died at the age of 2½ months due to cardiac arrest secondary to arrhythmia and ventricular fibrillation. Informed consent was obtained from the parents of the patient to publish this article.

Discussion

Dysmorphic facial features (micrognathia, anteverted nostrils, V-shaped upper lip, webbed neck, microglossia, cleft/high palate, bifid uvula, and thick maxillary-alveolar protrusions), microcephaly, mental retardation, hypotonia, premature closing of the fontanel, polydactyly, syndactyly of the 2nd and 3rd toes, and genitourinary anomalies (cryptorchidism, hypospadias, clitoral hypertrophy, and ambiguous genitalia) are common anomalies in Type 2 SLOS with severe clinical course.^[5] Less commonly, hypertelorism, cataracts, short limbs, hydrocephalus, lissencephaly, central nervous system anomalies such as corpus callosum agenesis, atrial/ventricular septal defect, cardiac anomalies such as patent ductus arteriosus,^[6] lung development anomalies (single lung), hypertrophic pyloric stenosis, Hirschsprung,^[7] gastrointestinal pathologies such as pancreatic islet cell

hyperplasia, adrenal gland pathologies, and sacral dimples can be seen. In our case, there were congenital anomalies of many systems as well as growth and developmental delay, as in the literature. However, he was diagnosed with pyloric stenosis in the clinic where he presented with vomiting and was operated on, and later, congenital anomalies were observed in the pediatric clinic (Figs. 1-4). While generally suspicious genital findings are seen in boys, normal genital structure is found in girls.^[8] The testicles were observed in the inguinal canal in the pelvic USG performed due to the ambiguous genitalia observed in the external genitalia of our case. Karyotype testing was also found to be compatible with the male gender. Although decreased serum cholesterol levels are a marker for the diagnosis of SLOS, it has been reported that there is no correlation between plasma cholesterol level and disease severity.^[5,9] Low 7-dehydrocholesterol level is important in the cases and it is stated that it indicates the level of the disorder in cholesterol production.^[9] In our case, serum cholesterol level was found to be low and a diagnosis of SLOS was made by genetic examination. In recent years, improvement in growth and neuromotor development of children has been reported with bile acid and cholesterol treatment.^[10] We applied cholesterol and bile acid treatment to our patient, but he was lost due to organ failure due to other system anomalies.

Conclusion

SLOS, which is characterized by dysmorphic appearance and multiple anomalies, develops with cholesterol synthesis disorder. In our country, where consanguineous marriages are common, plasma cholesterol level should be checked in cases with malnutrition, vomiting, dysmorphic appearances, and anomalies, genetic examination should be performed considering SLOS in differential diagnosis and genetic consultation should be recommended to the family.

Disclosures

Informed consent: Written, informed consent was obtained from the patient's family for the publication of this case report and the accompanying images.

Peer-review: Externally peer-reviewed.

Conflict of Interest: None declared.

Authorship Contributions: Concept – N.U.; Design – E.E.E.; Supervision – N.B.; Materials – G.K., N.B.; Data collection &/or processing – E.E.E.; Analysis and/or interpretation – N.U.; Literature search – E.E.E.; Writing – N.B.; Critical review – N.U.

References

1. Porter FD. RSH/Smith-Lemli-Opitz syndrome: a multiple congenital anomaly/mental retardation syndrome due to an inborn error

- of cholesterol biosynthesis. *Mol Genet Metab* 2000;71:163–74.
2. Yu H, Lee MH, Starck L, Elias ER, Irons M, Salen G, et al. Spectrum of Delta(7)-dehydrocholesterol reductase mutations in patients with the Smith-Lemli-Opitz (RSH) syndrome. *Hum Mol Genet*. 2000 May 22;9(9):1385-91. [\[CrossRef\]](#)
 3. Tint GS, Irons M, Elias ER, Batta AK, Frieden R, Chen TS, et al. Defective cholesterol biosynthesis associated with the Smith-Lemli-Opitz syndrome. *N Engl J Med* 1994;330:107–13. [\[CrossRef\]](#)
 4. Ramírez-Gómara A, Castejón-Ponce E, Martínez-Martínez M, García-Bodega O, Rite-Gracia S, Segura- Arazuri D, et al. Smith Lemli Opitz Syndrome type II of neonatal diagnosis and review of the most interesting clinical features. [Article in Spanish]. *Rev Neurol* 2002;34:946–50. [\[CrossRef\]](#)
 5. Cunniff C, Kratz LE, Moser A, Natowicz MR, Kelley RI. Clinical and biochemical spectrum of patients with RSH/Smith-Lemli-Opitz syndrome and abnormal cholesterol metabolism. *Am J Med Genet* 1997;68:263–9. [\[CrossRef\]](#)
 6. Lin AE, Ardinger HH, Ardinger RH Jr, Cunniff C, Kelley RI. Cardiovascular malformations in Smith-Lemli-Opitz syndrome. *Am J Med Genet* 1997;68:270–8. [\[CrossRef\]](#)
 7. Patterson K, Toomey KE, Chandra RS. Hirschsprung disease in a 46,XY phenotypic infant girl with Smith-Lemli-Opitz syndrome. *J Pediatr* 1983;103:425–7. [\[CrossRef\]](#)
 8. Curry CJ, Carey JC, Holland JS, Chopra D, Fineman R, Golabi M, et al. Smith-Lemli-Opitz syndrome-type II: multiple congenital anomalies with male pseudohermaphroditism and frequent early lethality. *Am J Med Genet* 1987;26:45–57. [\[CrossRef\]](#)
 9. Oláh AV, Szabó GP, Varga J, Balogh L, Csábi G, Csákváry V, et al. Relation between biomarkers and clinical severity in patients with Smith-Lemli-Opitz syndrome. *Eur J Pediatr* 2013;172:623–30.
 10. Nwokoro NA, Mulvihill JJ. Cholesterol and bile acid replacement therapy in children and adults with Smith-Lemli-Opitz (SLO/RSH) syndrome. *Am J Med Genet* 1997;68:315–21. [\[CrossRef\]](#)