



## Original Research

# The Efficiency of Fractional Anisotropy, Apparent Diffusion Coefficient, and Contrast Enhancement Index in Liver Fibrosis Staging

Umut Perçem Orhan Soylemez,<sup>1</sup> Deniz Turkyilmaz Mut,<sup>2</sup> Canan Alatas Alkim,<sup>3</sup> Huseyin Alkim,<sup>3</sup>  
 Banu Yilmaz Ozguven,<sup>4</sup> Salih Boga,<sup>5</sup> Muzaffer Basak,<sup>2</sup> Sukru Mehmet Erturk<sup>6</sup>

<sup>1</sup>Department of Radiology, Istanbul Medeniyet University, Goztepe City Hospital, Istanbul, Turkey

<sup>2</sup>Department of Radiology, Sisli Hamidiye Etfal Teaching and Research Hospital, Istanbul, Turkey

<sup>3</sup>Department of Gastroenterohepatology, University of Health Sciences Turkey, Sisli Hamidiye Etfal Training and Research Hospital, Istanbul, Turkey

<sup>4</sup>Department of Pathology, University of Health Sciences Turkey, Basaksehir Cam ve Sakura City Hospital, Istanbul, Turkey

<sup>5</sup>Department of Gastroenterology, Istanbul Bahcelievler Memorial Hospital, Istanbul, Turkey

<sup>6</sup>Department of Radiology, Istanbul University Faculty of Medicine, Istanbul, Turkey

### Abstract

**Objectives:** Even though magnetic resonance imaging has been described as the most effective imaging method for the diagnosis of liver fibrosis, an accepted magnetic resonance imaging (MRI) technique is yet to be defined. The aim of this study is to determine the efficiency of MRI in the staging of liver fibrosis.

**Methods:** Patients with chronic hepatitis B infection and had upper abdominal MRI with hepatocyte specific contrast agent were evaluated. Twenty-nine patients that had undergone liver biopsy were included in the study. ADC, FA, and signal intensity values of liver parenchyma were measured by two observers and contrast enhancement index (CEI) was calculated as well. Patients were grouped as early (A) and late fibrosis(B) according to Ishak grading system and then the correlations between the stage and MRI findings were analysed. The intraclass correlation coefficient was used to analyze the inter-rater agreements. ADC, FA, and CEI were compared with Student t-test between early and late fibrosis groups. Pearson's correlation was used to assess the correlation between ADC and FA values. Spearman correlation was used to evaluate the relationship between pathologic fibrosis grade and MRI parameters that were measured.

**Results:** Twenty-two patients were staged as 1 and 2 (group A), seven patients were staged as 3 and above fibrosis(group B). Statistically, there was a strong, negative correlation between the FA values and the degree of fibrosis ( $r=-0.582$ ,  $p=0.001$ ). There was no correlation between the CEI and hepatocyte activity index ( $r=-0.88$ ,  $p=0.655$ ) and degree of fibrosis ( $r=0.0001$ ,  $p=0.997$ ). In terms of FA values, there was a statistically significant difference between two groups (group A= $0.429 \pm 0.06$ , group B= $0.349 \pm 0.06$ ) ( $p=0.004$ ).

**Conclusion:** Correlation of FA values with fibrosis stage and significant difference in FA values between early-late stage fibrosis patients shows that diffusion tensor imaging can be a promising technique in the staging and follow-up of liver fibrosis.

**Keywords:** Contrast agent, diffusion magnetic resonance imaging, hepatitis B, liver cirrhosis, magnetic resonance imaging

Please cite this article as "Orhan Soylemez UP, Turkyilmaz Mut D, Alatas Alkim C, Alkim H, Yilmaz Ozguven B, Boga S, et al. The Efficiency of Fractional Anisotropy, Apparent Diffusion Coefficient, and Contrast Enhancement Index in Liver Fibrosis Staging. Med Bull Sisli Etfal Hosp 2022;56(1):113-118".

**Address for correspondence:** Umut Perçem Orhan Soylemez, MD. Istanbul Medeniyet Universitesi, Goztepe Sehir Hastanesi, Radyoloji Anabilim Dalı, Istanbul, Turkey

**Phone:** +90 533 735 44 37 **E-mail:** umutpercem@gmail.com

**Submitted Date:** August 27, 2021 **Accepted Date:** November 29, 2021 **Available Online Date:** March 28, 2022

©Copyright 2022 by The Medical Bulletin of Sisli Etfal Hospital - Available online at [www.sislietfaltip.org](http://www.sislietfaltip.org)

**OPEN ACCESS** This is an open access article under the CC BY-NC license (<http://creativecommons.org/licenses/by-nc/4.0/>).



Liver fibrosis is one of the results of chronic liver diseases. This is a serious and common public health problem and may cause portal hypertension, liver failure, cirrhosis, hepatocellular carcinoma, and even death. The most common cause of the disease is the chronic viral hepatitis (Chronic hepatitis B [CHB] infection is the most common).<sup>[1]</sup> The early diagnosis of CHB infection increases patient survival and decreases the need for liver transplantation.<sup>[2]</sup> It is very important to diagnose fibrosis in the early stage as its progression can be controlled and fibrosis can be reversible in the early stage, but it is a low possibility for late stage fibrosis.<sup>[3]</sup> These patients also fibrosis stage must be followed up such as viral load and levels of transaminasis.<sup>[4]</sup> Despite being an invasive procedure, liver biopsy is still the best diagnostic tool for diagnosing and staging the liver fibrosis and is performed for follow-ups of fibrosis.<sup>[5]</sup> The search for non-invasive and reproducible alternative diagnostic methods is continuing to reduce the possible complications of liver biopsy and prevent the patient discomfort.<sup>[6]</sup>

CHB patients are screened for complications such as dysplastic nodules and hepatocellular carcinoma as well.<sup>[6]</sup> Ultrasound (US) and magnetic resonance imaging (MRI) are the most common imaging techniques for screening. Studies about the efficacy of diffusion-weighted imaging (DWI) in staging liver fibrosis have revealed that DWI may be an effective and non-invasive method.<sup>[7]</sup> DWI is one of the main sequences in the differential diagnosis of liver lesions.<sup>[8]</sup> Furthermore, MRI contrast agents are frequently used in daily practice in the detection, follow-up, and differential diagnosis of liver lesions. Hepatocyte-specific contrast agents are increasingly being used in daily practice.<sup>[9]</sup> Gadoteric acid (Gd-EOB-DTPA) is excreted from biliary system by multidrug resistance-associated proteins.<sup>[3]</sup> It has been previously reported that the relative enhancement of Gd-EOB-DTPA which shows the uptake into hepatocytes is correlated with clinical cirrhosis scoring systems.<sup>[10]</sup> Furthermore, there are promising studies on the use of Gd-EOB-DTPA to differentiate early and late stage fibrosis.<sup>[11]</sup> In this study, we aimed to evaluate the correlation of DWI (ADC values), diffusion tensor imaging (FA values), and Gd-EOB-DTPA-enhanced MRI (contrast enhancement index [CEI]) with the histopathological Ishak stage of liver fibrosis in CHB infected patients.

## Methods

Institutional review board approval was obtained for this retrospective study (ID:198/28.5.2013). The patients with CHB infection and clinically followed up in gastroenterohepatology department were evaluated. Patients having dynamic upper abdominal MRI with Gd-EOB-DTPA and had undergone liver biopsy in 2 years period were included in

the study. Patients under the age of 18, with inadequate image quality (without diffusion weighted sequence, without hepatocyte phase in 20th min and with artefacts), patients that have not staged and reported in line Ishak scoring system, Ishak stage 0 patients, patients with the history of partial hepatectomy, transarterial chemo and radioembolisation, percutaneous ethanol injection, and liver metastasis were excluded from the study.

## MRI Parameters and Measurements

All MRIs were performed with 1,5 T Simens 2011 Avanto Tim 76 × 18. To increase the diffusion effect, ADC measurements were made from images with "b" value of 1000. Hepatocyte phase was performed in 20th min after 0.025 mmol/kg intravenous Gd-EOB-DTPA (Primovist, Bayer Health Care). Independently two observers evaluated MR images. ADC (Fig. 1), FA (Fig. 2), T1 signal intensity before

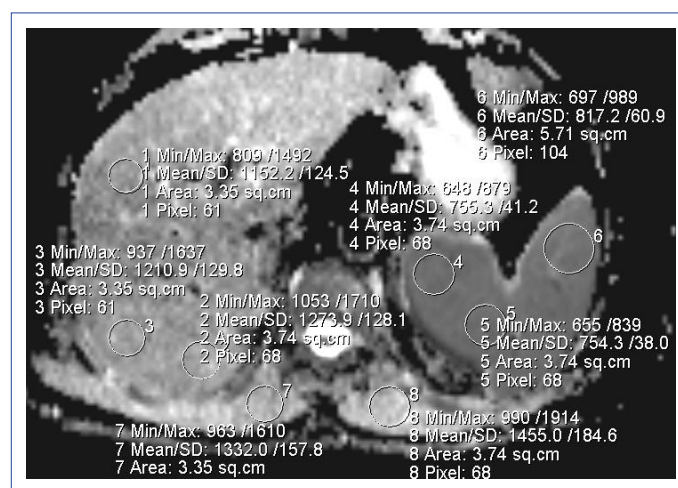


Figure 1. Apparent diffusion coefficient measurement.

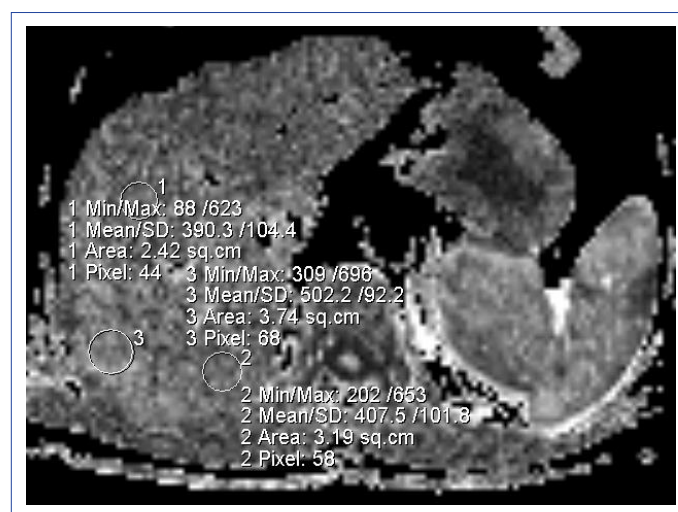


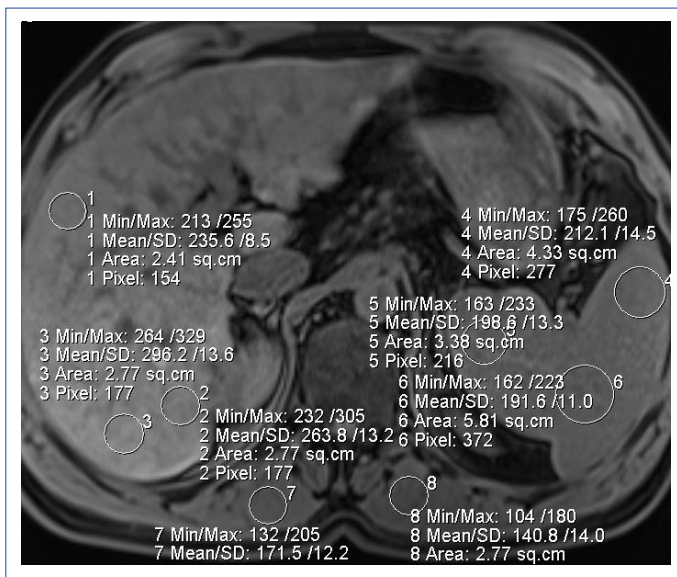
Figure 2. Fractional anisotropy measurements in diffusion tensor image.

(Fig. 3), and after contrast injection (in hepatocyte phase) (Fig. 4) were measured from three different points of liver right lobe. In all measurements, region of interest was placed by avoiding biliary and vascular structures and motion artifacts as much as possible with a diameter of 1–2 cm<sup>2</sup> (Figs. 1-4).

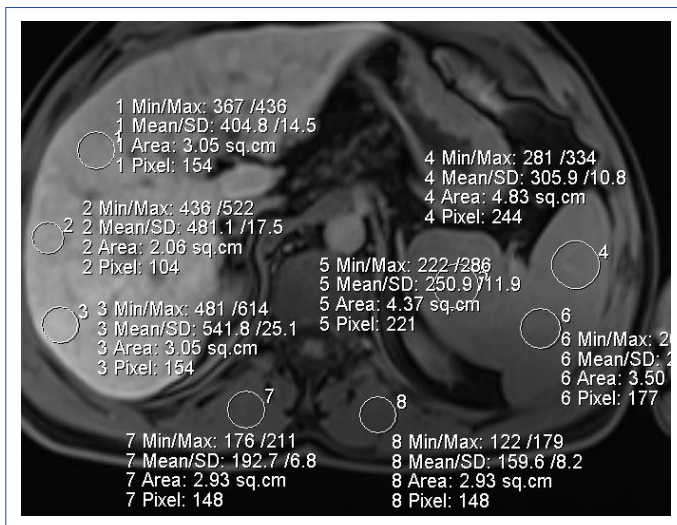
CEI was calculated as:

$$\frac{\text{Signal intensity in hepatocyte specific phase} - \text{Signal intensity in unenhanced T1W sequence}}{\text{Signal intensity in hepatocyte specific phase}}$$

*Signal intensity in hepatocyte specific phase*



**Figure 3.** Signal intensity measurements from three points of the right liver lobe, three points of spleen and both paravertebral muscles by region of interest on non-contrast T1-weighted sequence.



**Figure 4.** Signal intensity measurements from the same points, 20 min after intravenous contrast injection.

## Histopathological Evaluation

Ishak scoring system (modified hepatocyte activity index)<sup>[12]</sup> was used to stage the liver fibrosis. The only stage that does not have fibrosis in this scoring system is the stage 0 and the remaining stages grades the fibrosis of the liver parenchyma. Stage 0 patients were not included to this study. Periportal/periseptal interface hepatitis, confluent necrosis, focal lytic necrosis/apoptosis/focal inflammation, portal inflammation, fibrosis, Ishak grade (modified HAI score), and Ishak stage (fibrosis) were evaluated and scored by an experienced pathologist in all specimens.<sup>[12]</sup> Patients were classified as fibrosis stage 1 and 2 (group A), stage 3 and higher (group B).

## Statistical Analysis

Data were analyzed using SPSS software (ver. 26.0; IBM Corp., Armonk, NY, USA). The intraclass correlation coefficient (ICC) was used to analyze the inter-rater agreements for ADC, SI, and FA values. Inter-rater reliability was assessed using the kappa coefficient ( $\kappa$ ) for qualitative variables. An ICC or a  $\kappa$  value of 0.81–1.00 indicates almost perfect agreement, while 0.61–0.80 reflects substantial agreement, 0.21–0.60 moderate agreement, and  $\leq 0.20$  slight agreement. Student t-test was used to compare the differences between groups for ADC, FA, and CEI. Correlation between ADC and FA values in the entire patient cohort was assessed by Pearson’s correlation ( $r$ ). In the whole patient cohort, the relationship between Ishak score and fibrosis stage and ADC and FA values and CEI was assessed with Spearman correlation. Correlation coefficients were interpreted as follows; 0.7 and above; very strong, between 0.69 and 0.5; strong, 0.49 and 0.3 between; moderate, between 0.29 and 0.1; low, and from 0.09 to 0.01; and very low.

## Results

Fourteen female (48.3%) and 15 male (51.7%) patients (age; 44.3 [22–63]) were included in the study. According to HAI scores, 22 of the patients had had a stage 1 and 2 fibrosis (group A) and seven of the patients had a stage 3 and above fibrosis (group B). Distribution of modified HAI scores which ranged from 2 to 11.

There was substantial agreement for ADC, FA, and SI values between observers ( $\kappa=0.82, 0.87,$  and  $0.86,$  respectively).

There was a moderate negative correlation between ADC values and FA values ( $r=-0.469, p=0.001$ ). A strong negative correlation between FA values and the degree of fibrosis ( $r=-0.582, p=0.001$ ) was also detected. A significant correlation between modified HAI scores and ADC values ( $r=-0.013, p=0.949$ ) and degree of fibrosis ( $r=0.076, p=0.699$ ) was not detected. Moreover, no significant correlation was found be-



tween FA values and HAI scores ( $r=-0.265$ ,  $p=0.172$ ). Furthermore, a correlation between HAI scores ( $r=-0.88$ ,  $p=0.655$ ) and degree of fibrosis ( $r=0.0001$ ,  $p=0.997$ ) with the CEI could not be detected (Table 1).

There was no significant difference between early and late stage groups in terms of CEI (Group A =  $0.7473\pm 0.33$ , Group B =  $0.6814\pm 0.22$ ;  $p=0.623$ ) and ADC values (Group A =  $1.11\pm 0.12$ , Group B =  $1.16\pm 0.04$ ;  $p=0.317$ ). However, FA values were significantly different between two groups (Group A =  $0.429\pm 0.06$ , Group B =  $0.349\pm 0.06$ ;  $p=0.004$ ) (Table 2).

## Discussion

Based on the idea that early microstructural changes derived from liver fibrosis, which can be detected with measurable MRI parameters, this study evaluated the correlation between ADC, FA, CEI, and Ishak scores. A statistically significant correlation was found between the FA values and the pathological stage of fibrosis. Furthermore, FA values differed significantly in the early and late fibrosis cases. However, evaluated remaining parameters revealed no significant correlation with the fibrosis score or difference in the early and late fibrosis.

Liver fibrosis is a consequence of chronic liver diseases; this may occur due to many reasons including; alcoholism, steatosis, hepatitis, cholestatic liver diseases, and toxins.<sup>[13,14]</sup> Liver biopsy remains to be the gold standard for diagnosis

and follow-up of liver fibrosis.<sup>[15]</sup> This procedure enables us to evaluate only a very small incidental piece of the liver parenchyma. However, the changes in the liver parenchyma can be very heterogeneous and random sampling may not be effective for precise detection of the fibrosis.<sup>[9,16]</sup> From this point of view, studies on non-invasive diagnostic methods have been carried out for a long time due to the possible complications of liver biopsy, the difficulty of repetition, the patient discomfort it causes, and the inability to give an idea about the whole parenchyma. Biomarkers and radiological imaging methods are the most popular methods that are investigated currently.<sup>[16]</sup>

Among imaging methods, MR elastography had been reported the best for grading liver fibrosis.<sup>[17]</sup> However, it is an expensive imaging method that can only be performed in a limited number of centers.<sup>[17]</sup> Therefore, the search for more accessible MR sequences continues.

In the previous DTI studies in rats with experimental fibrosis, it has been reported that FA is valuable parameter in detecting early stage fibrosis and following the progression of fibrosis.<sup>[18,19]</sup> Interestingly, both positive<sup>[19]</sup> and negative correlations<sup>[20]</sup> with fibrosis have been reported in the previous studies for FA. In the present study, FA values were negatively correlated with fibrosis stage and also FA values differed between early and late fibrosis cases. These differences may cause from the underlying complex histopathological changes such as inflammation, fat infiltration, and decrease of extracellular collagen. Presumably, in the period when extracellular matrix proteins increase, diffusion of water molecules is restricted and FA value decreases. However, on the contrary, it increases in advanced phase when cell necrosis occurs. These differences can be explained by the fibrosis stage, etiology, and sample size differences in the studies.

Harada et al. had reported no significant difference between ADC values and fibrosis grade.<sup>[21]</sup> Furthermore, Bülow et al. described ADC values as confounded in iron and fat deposition even authors reported no correlation between ADC and fibrosis stage even without iron and fat deposition.<sup>[22]</sup> In line with this studies, our results revealed that ADC values were not correlated with fibrosis stage and did not differ in the early and late fibrosis cases. Besides, some authors had reported significant correlation with ADC and fibrosis grade.<sup>[23]</sup> In a meta-analysis including 25 studies, DWI reported to be a good diagnostic tool for liver fibrosis grading. Heterogenous patient groups, different imaging parameters, and histopathological study models may have caused the different results. Different results may have been obtained depending on the heterogeneous patient groups (hepatitis [B and C], biliary causes, alcoholism,

**Table 1.** Correlation of MRI parameters with histopathological results

	Hepatocyte activity index	Stage of fibrosis
ADC (mm <sup>2</sup> /s)	$r=-0.013$ $P=0.949$	$r=0.076$ $P=0.699$
FA	$r=-0.265$ $P=0.172$	$r=-0.582$ $p=0.001^*$
CEI	$r=-0.88$ $P=0.655$	$r=0.0001$ $P=0.997$

ADC: Apparent diffusion coefficient; FA: Fractional anisotropy; CEI: Contrast enhancement index; r: Spearman correlation\*significant.

**Table 2.** Comparison of MRI parameters of early and late stage fibrosis groups

	Group A (n=22)	Group B (n=7)	p
ADC (mm <sup>2</sup> /s)(mean/SD)	$1.11\pm 0.12$	$1.16\pm 0.04$	0.317
FA (mean/SD)	$0.429\pm 0.06$	$0.349\pm 0.06$	0.004*
CEI (mean/SD)	$0.7473\pm 0.33$	$0.6814\pm 0.22$	0.623

Student t-test; FA: Fractional anisotropy; CEI: Contrast enhancement index; ADC: Apparent diffusion coefficient; SD: Standard deviation; \*Significant.

non-alcoholic steatohepatitis, toxins, etc.) included in studies conducted in recent years. Considering technical parameters, methods such as ADC normalization, have been proposed for a more standard imaging.<sup>[24]</sup> In the evaluation of ADC, fatty liver, iron accumulation in parenchyma, liver inflammation, and perfusion effect pose problem.<sup>[25]</sup> In the present study, only CHB infected patients were included for a more homogeneous patient group evaluation.

The CEI was recently reported as a reliable biomarker for staging liver fibrosis.<sup>[26-29]</sup> Stable comparison criteria are needed in case other liver diseases may be present. Among these parameters, we used the CEI and liver to paravertebral muscle SI ratios. Although various SI parameters were described and have been studied recently, paravertebral muscle SI was used in the present study, because it was reported to be more stable and minimally effected from age and liver function.<sup>[21]</sup> Furthermore, CEI was reported to have a better diagnostic accuracy than one phase imaging.<sup>[30]</sup> However, we detected no correlation between the fibrosis stage and CEI. This may be due to the small rate of advanced fibrosis in the patient group.

This study evaluates only the patients with fibrosis (Ishak grade 1 and over). Results revealed that MRI can be effective to determine the early or late stage of the fibrosis. Nevertheless, the prognosis of the patients having fibrosis can be predicted using the MRI. However, as there was not a control group with no fibrosis, it is impossible to mention the effectiveness of the MRI differentiating the patients with fibrosis and no fibrosis. Thus, future comparative studies between patients without fibrosis and patients with the early stage fibrosis are needed to determine the effectiveness of the MRI.

Retrospective design, limited number of patients, and the low rate of advanced fibrosis patients were the limitations of the present study. However, this study could contribute to the knowledge as we had evaluate the both diffusion weighted and diffusion tensor imaging parameters, and also CEI in a homogeneous patient cohort (only in CHB infection). Studies with prospective design ang include large patient cohorts would provide more information.

## Conclusion

DTI, whereas FA may be a promising diagnostic tool for staging liver fibrosis. Quantitative MRI parameters may provide us to stage and follow-up the prognosis of liver fibrosis. Thus, liver biopsy and associated morbidity and mortality rates could decrease. The difference in FA values between follow-up images may be a sign for the progression of fibrosis.

## Disclosures

**Ethics Committee Approval:** Instutional review board approval was obtained for this retrospective study (ID:198/28.5.2013).

**Peer-review:** Externally peer-reviewed.

**Conflict of Interest:** None declared.

**Authorship Contributions:** Concept – S.M.E., U.P.O.S., D.T.M., H.A.; Design – S.M.E., U.P.O.S., S.B., C.A.A.; Supervision – S.M.E., U.P.O.S., M.B., H.A.; Materials – S.B., B.Y.O., H.A.; Data collection &/ or processing – S.B., U.P.O.S., D.T.M.; Analysis and/or interpretation – B.Y.O., O.N.T., M.B., C.A.A.; Literature search – S.M.E., U.P.O.S., D.T.M.; Writing – U.P.O.S., C.A.A., H.A.; Critical review – U.P.O.S., D.T.M., S.B., M.B.

## References

- Xiao H, Shi M, Xie Y, Chi X. Comparison of diagnostic accuracy of magnetic resonance elastography and Fibroscan for detecting liver fibrosis in chronic hepatitis B patients: A systematic review and meta-analysis. *PLoS One* 2017;12:e0186660. [CrossRef]
- Terrault NA, Lok ASF, McMahon BJ, Chang KM, Hwang JP, Jonas MM, et al. Update on prevention, diagnosis, and treatment of chronic hepatitis B: AASLD 2018 hepatitis B guidance. *Hepatology* 2018;67:1560–99. [CrossRef]
- Li X, Liu H, Wang R, Yang J, Zhang Y, Li C. Gadoxetate-disodium-enhanced magnetic resonance imaging for liver fibrosis staging: a systematic review and meta-analysis. *Clin Radiol* 2020;75:319.
- Esmaeelzadeh A, Saadatnia H, Memar B, Mokhtari Amirmajdi E, Ganji A, Goshayeshi L, et al. Evaluation of serum HBV viral load, transaminases and histological features in chronic HBsAg-negative hepatitis B patients. *Gastroenterol Hepatol Bed Bench* 2017;10:39–43.
- Lambrecht J, Verhulst S, Mannaerts I, Reynaert H, van Grunsven LA. Prospects in non-invasive assessment of liver fibrosis: Liquid biopsy as the future gold standard? *Biochim Biophys Acta Mol Basis Dis* 2018;1864:1024–36. [CrossRef]
- Zhong X, Li JS, Chen ZJ, Yin JX, Gui S, Sun ZQ, et al. Texture analysis of diffusion-weighted magnetic resonance imaging to identify atypically enhanced small hepatocellular carcinoma and dysplastic nodules under the background of cirrhosis. [Article in Chinese]. *Zhonghua Gan Zang Bing Za Zhi* 2020;28:37–42.
- Jiang H, Chen J, Gao R, Huang Z, Wu M, Song B. Liver fibrosis staging with diffusion-weighted imaging: a systematic review and meta-analysis. *Abdom Radiol (NY)* 2017;42:490–501. [CrossRef]
- Bharwani N, Koh DM. Diffusion-weighted imaging of the liver: an update. *Cancer Imaging* 2013;13:171–85. [CrossRef]
- Verloh N, Utpatel K, Haimerl M, Zeman F, Beyer L, Fellner C, et al. Detecting liver fibrosis with Gd-EOB-DTPA-enhanced MRI: A confirmatory study. *Sci Rep* 2018;8:6207. [CrossRef]
- Tamada T, Ito K, Higaki A, Yoshida K, Kanki A, Sato T, et al. Gd-EOB-DTPA-enhanced MR imaging: evaluation of hepatic enhancement effects in normal and cirrhotic livers. *Eur J Radiol* 2011;80:e311–6.
- Hako R, Kristian P, Jarčuška P, Haková I, Hockicková I, Schréter I, et

- al. Noninvasive assessment of liver fibrosis in patients with chronic hepatitis B or C by contrast-enhanced magnetic resonance imaging. *Can J Gastroenterol Hepatol* 2019;2019:3024630.
12. Ishak KG. Pathologic features of chronic hepatitis. A review and update. *Am J Clin Pathol* 2000;113:40–55. [\[CrossRef\]](#)
  13. Aydın MM, Akçalı KC. Liver fibrosis. *Turk J Gastroenterol* 2018;29:14–21. [\[CrossRef\]](#)
  14. Cetin EG, Demir N, Sen I. The relationship between insulin resistance and liver damage in non-alcoholic fatty liver patients. *Sisli Etfal Hastan Tip Bul* 2020;54:411–5.
  15. Lurie Y, Webb M, Cytter-Kuint R, Shteingart S, Lederkremer GZ. Non-invasive diagnosis of liver fibrosis and cirrhosis. *World J Gastroenterol* 2015;21:11567–83. [\[CrossRef\]](#)
  16. Afdhal NH. Biopsy or biomarkers: is there a gold standard for diagnosis of liver fibrosis? *Clin Chem* 2004;50:1299–300. [\[CrossRef\]](#)
  17. Obmann VC, Marx C, Berzigotti A, Mertineit N, Hrycyk J, Gräni C, et al. Liver MRI susceptibility-weighted imaging (SWI) compared to T2\* mapping in the presence of steatosis and fibrosis. *Eur J Radiol* 2019;118:66–74. [\[CrossRef\]](#)
  18. Cheung JS, Fan SJ, Gao DS, Chow AM, Man K, Wu EX. Diffusion tensor imaging of liver fibrosis in an experimental model. *J Magn Reson Imaging* 2010;32:1141–8. [\[CrossRef\]](#)
  19. Huang M, Lu X, Wang X, Shu J. Diffusion tensor imaging quantifying the severity of chronic hepatitis in rats. *BMC Med Imaging* 2020;20:74. [\[CrossRef\]](#)
  20. Lee Y, Kim H. Assessment of diffusion tensor MR imaging (DTI) in liver fibrosis with minimal confounding effect of hepatic steatosis. *Magn Reson Med* 2015;73:1602–8. [\[CrossRef\]](#)
  21. Harada TL, Saito K, Araki Y, Matsubayashi J, Nagao T, Sugimoto K, et al. Prediction of high-stage liver fibrosis using ADC value on diffusion-weighted imaging and quantitative enhancement ratio at the hepatobiliary phase of Gd-EOB-DTPA-enhanced MRI at 1.5T. *Acta Radiol* 2018;59:509–16. [\[CrossRef\]](#)
  22. Bülow R, Mensel B, Meffert P, Hernando D, Evert M, Kühn JP. Diffusion-weighted magnetic resonance imaging for staging liver fibrosis is less reliable in the presence of fat and iron. *Eur Radiol* 2013;23:1281–7. [\[CrossRef\]](#)
  23. Bonekamp D, Bonekamp S, Ou HY, Torbenson MS, Corona-Villalobos CP, Mezey E, et al. Assessing liver fibrosis: comparison of arterial enhancement fraction and diffusion-weighted imaging. *J Magn Reson Imaging* 2014;40:1137–46. [\[CrossRef\]](#)
  24. Shin MK, Song JS, Hwang SB, Hwang HP, Kim YJ, Moon WS. Liver fibrosis assessment with diffusion-weighted imaging: value of liver apparent diffusion coefficient normalization using the spleen as a reference organ. *Diagnostics (Basel)* 2019;9:107. [\[CrossRef\]](#)
  25. Aubé C, Racineux PX, Lebigot J, Oberti F, Croquet V, Argaud C, et al. Diagnosis and quantification of hepatic fibrosis with diffusion weighted MR imaging: preliminary results. [Article in French]. *J Radiol* 2004;85:301–6. [\[CrossRef\]](#)
  26. Chen BB, Hsu CY, Yu CW, Wei SY, Kao JH, Lee HS, et al. Clinical and histologic implications of delayed hepatobiliary enhancement on magnetic resonance imaging with gadolinium ethoxybenzyl diethylenetriaminepentaacetic Acid. *Invest Radiol* 2012;47:649–55. [\[CrossRef\]](#)
  27. Goshima S, Kanematsu M, Watanabe H, Kondo H, Kawada H, Moriyama N, et al. Gd-EOB-DTPA-enhanced MR imaging: prediction of hepatic fibrosis stages using liver contrast enhancement index and liver-to-spleen volumetric ratio. *J Magn Reson Imaging* 2012;36:1148–53. [\[CrossRef\]](#)
  28. Jang YJ, Cho SH, Bae JH, Kim GC, Ryeom H, Kim HJ, et al. Noninvasive assessment of hepatic fibrosis using gadoxetate-disodium-enhanced 3T MRI. *Ann Hepatol* 2013;12:926–34. [\[CrossRef\]](#)
  29. Lee S, Choi D, Jeong WK. Hepatic enhancement of Gd-EOB-DTPA-enhanced 3 Tesla MR imaging: Assessing severity of liver cirrhosis. *J Magn Reson Imaging* 2016;44:1339–45. [\[CrossRef\]](#)
  30. Norén B, Forsgren MF, Dahlqvist Leinhard O, Dahlström N, Kihlberg J, Romu T, et al. Separation of advanced from mild hepatic fibrosis by quantification of the hepatobiliary uptake of Gd-EOB-DTPA. *Eur Radiol* 2013;23:174–81. [\[CrossRef\]](#)